

# A delayed diagnosis of bilateral facet dislocation of the cervical spine: a case report

Julie O'Shaughnessy, DC, FCCS(C), MSc<sup>a</sup>  
 Julie-Marthe Grenier, DC, DACBR/FCCR(C)<sup>a</sup>  
 Paula J. Stern, BSc, DC, FCCS(C)<sup>b</sup>

**Objective:** *To review the case of a patient suffering from bilateral facet dislocation of the cervical spine.*

**Clinical features:** *A 53-year-old male was involved in a car accident and was transported to the hospital. Cervical radiographs were taken at the emergency department and interpreted as normal. Four days later, he consulted a chiropractor where radiographs of the cervical spine were repeated. The examination revealed bilateral cervical facet joint dislocation at C5-C6 as well as a fracture involving the spinous process and laminae of C6.*

**Intervention and outcome:** *The patient was referred to the hospital and underwent surgery.*

**Conclusion:** *Patients involved in motor vehicle accidents often consult chiropractors for neck pain treatment. A high index of suspicion due to significant history and physical examination findings should guide the clinician in determining the need for reviewing the initial radiographs (if taken and available) or request repeat studies, regardless of the initial imaging status.*

(JCCA 2014;58(1):45-51)

**KEY WORDS:** dislocation, cervical spine, radiographs

**Objectif :** *Examiner le cas d'un patient souffrant d'une dislocation facettaire bilatérale de la colonne cervicale.*

**Caractéristiques cliniques :** *Un homme de 53 ans a été transporté à l'hôpital à la suite d'un accident de voiture. Les radiographies cervicales prises à l'urgence ont été jugées normales. Quatre jours plus tard, les radiographies de la colonne cervicale ont été répétées chez un chiropraticien. L'examen a révélé une dislocation facettaire bilatérale à C5-C6, ainsi qu'une fracture impliquant l'apophyse épineuse et les lames de C6.*

**Intervention et résultat :** *Le patient a été envoyé à l'hôpital où il a subi une intervention chirurgicale.*

**Conclusion :** *Les patients impliqués dans des accidents de véhicules automobiles consultent souvent les chiropraticiens pour le traitement des douleurs cervicales. Un indice élevé de suspicion dû à l'histoire importante et aux résultats de l'examen physique doit pousser le clinicien à déterminer la nécessité de réviser les radiographies initiales (si disponibles) ou à demander la répétition des examens, peu importe l'interprétation initiale de l'imagerie.*

(JCCA 2014;58(1):45-51)

**MOTS CLÉS :** dislocation, colonne cervicale, radiographies

<sup>a</sup> Full time professor, Département de chiropratique, Université du Québec à Trois-Rivières (UQTR), Trois-Rivières, Québec, Canada.

<sup>b</sup> Director, CMCC Graduate Studies program, Canadian Memorial Chiropractic College, Toronto, Ontario, Canada.

Address correspondence :

Julie O'Shaughnessy, Département de Chiropratique, UQTR, 3351 boul. des Forges, C.P. 500, Trois-Rivières, QC, Canada G9A 5H7.

E-mail: Julie.O'Shaughnessy@uqtr.ca

Competing interests: The authors declare that they have no competing interests.

©JCCA 2014

## Introduction

Cervical injuries, such as bilateral facet dislocation, are part of a spectrum of cervical spine flexion/distraction-type injuries. Many definitions exist for these injuries and efforts have been made recently to standardize the nomenclature to avoid confusion during interprofessional communications, as well as to facilitate documentation and research. According to the Subaxial Cervical Injury Description System (SCIDS), bilateral facet dislocation is defined as a disruption of both facet joints in which the inferior articular processes of the cranial vertebra have translated anterosuperiorly over the superior articular processes of the caudal vertebra.<sup>1</sup> The lesion may be associated with fracture of the facet joint complex. Perched facets is a subtype of dislocation where there is complete loss of apposition of the articular surfaces, but the tip of the inferior articular process only abuts, without extending past, the superior articular process.<sup>1</sup> For the purpose of this paper, facet dislocations (uni or bilateral) will refer to an injury where there is less than full apposition of facet articular surfaces, regardless of the subtypes and individual variations.

Cervical dislocations are more frequent in males (4:1) with the median age being 29 years. The most common causes of cervical dislocations are motor vehicle accidents, diving accidents, and falls.<sup>2,3</sup> According to various studies, the most common levels for dislocations are C4-C5, C5-C6, and C6-C7.<sup>4,9</sup> The lower cervical spine is particularly at risk because of its increased mobility (as compared to the upper thoracic spine), as well as its more horizontally oriented and smaller dimension superior facets. In addition, the transition from kyphotic to lordotic curve increases the stress on the cervical region, contributing to the risk of dislocation.

Hyperflexion of the cervical spine has traditionally been described as the mechanism for bilateral facet dislocations. Recent studies question this association and suggest the buckling phenomenon as the principal mechanism of injury, at least when occurring in the context of sports injury. Buckling movement of the cervical spine would be caused by force vectors with significant compressive forces leading to flexion of the lower cervical spine and extension of the upper cervical spine, resulting in separation of the facets at the fulcrum point.<sup>2,4,8</sup> Regardless of the exact mechanism, the amount of force exerted to separate the facet joints inevitably causes extensive

soft tissue injury and cervical spine ligamentous instability. A study using magnetic resonance imaging (MRI) described the extent of the ligamentous damage seen in 30 patients with bilateral facet dislocation. Almost every patient (97%) demonstrated a disruption of the posterior column ligament complex, mainly the supraspinous and interspinous ligaments. The intervertebral disc and ligamentum flavum showed disruption in 90% of the subjects. It is important to note that 63.3% of patients also had a facet fracture.<sup>10</sup>

Furthermore, the forces exerted during the injury also create tremendous stresses on the vasculature. Vertebral artery injury following any type of cervical trauma is not rare.<sup>11-14</sup> It is most commonly seen with dislocations or when a fracture involves the transverse foramen, especially if bony fragments are present.<sup>11,12</sup> The incidence of vertebral artery injury in patients with dislocation or fracture has been found to be quite important, even though the range is quite large, between 21% to 75% of patients.<sup>11,13,14</sup> The vertebral arteries may be damaged in both unilateral and bilateral facet dislocations, but are more commonly associated with unilateral facet dislocation. Signs and symptoms of bilateral vertebral artery injury may not be apparent immediately. Delays of a few hours to a few days have been reported. Patients who are stable initially may suddenly deteriorate very rapidly. This injury dramatically increases the risk of thrombus formation, leading to posterior circulation stroke symptoms.<sup>11,12,15</sup>

We present a case of a 53-year-old male with a bilateral cervical dislocation. The objective of this case report is to demonstrate common characteristics of a rare condition in a patient that may present to chiropractors or other health care professionals.

## Case report

A 53-year-old man presented to a chiropractic clinic complaining of neck pain that began four days earlier following a motor vehicle accident. The patient was driving at approximately 80-90 km/h when he lost control of his vehicle and rolled over several times. He was transported to the hospital by ambulance where cervical and thoracic radiographs were taken and interpreted as normal. He was discharged from the hospital with a prescription for muscle relaxants, anti-inflammatory medication, and sick leave recommendation for a week. The initial pain was located between the mid-cervical and upper thoracic

spine (approximately between C4 and T4) and was accompanied by occasional pain and a sensation of numbness along the right C6 dermatome. All ranges of neck movement aggravated the symptoms, while non-steroidal anti-inflammatory medication and muscle relaxants provided relief. Past medical history and systems review were unremarkable.

Upon examination, pronounced cervical spine antalgia, in left lateral flexion and anterior translation, was observed. The patient also had a decreased lordosis, with a noticeable protuberance at the mid-cervical spine. A moderate decrease in right lateral flexion and right rotation associated with muscular spasms (bilaterally) at the cervical paraspinal and scalenus muscles was present. Cervical distraction decreased pain and numbness in the right arm, whereas compression in extension and compression in lateral flexion increased the symptoms. Upper and lower extremity neurological examination (i.e. deep tendon reflexes [DTR], sensation [light touch and sharp/pain], motor testing and pathologic reflexes [clonus, Hoffman and plantar reflex]) was not performed. Static palpation of the cervical spine revealed multiple trigger points in the right scalenus and bilateral erector spinae muscles, while motion palpation illustrated an articular restriction of C7 and T1.

The chiropractor took two radiographs of the cervical spine in his clinic: antero-posterior (AP) cervical with open mouth (Figure 1) and lateral (Figure 2) projections. The radiographs revealed severe anterior intervertebral disc space narrowing with 25% anterolisthesis of the vertebral body of C5 upon C6. Both pairs of intervertebral facets at C5-6 were discontinuous. A complete loss of apposition of the articular surfaces, with the most inferior tip of the C5 facets balancing on the most superior tip of the C6 facets, was observed (i.e. perched facets). This finding was indicative of a bilateral facet dislocation. A vertical radiolucency representing a fracture of the spinous process of C6 with extension into both laminae was also present. The anterior soft tissues appeared widened, especially in the retropharyngeal and retrotracheal portions. The cervical spine exhibited an acute kyphosis with the apex at C5-6, resulting in marked anterior translation of the head and upper cervical spine. Although the mid cervical region was superimposed with the mandible on the AP view, the facet joint spaces were visible and appeared widened. The uncinata processes at C5-6 could not

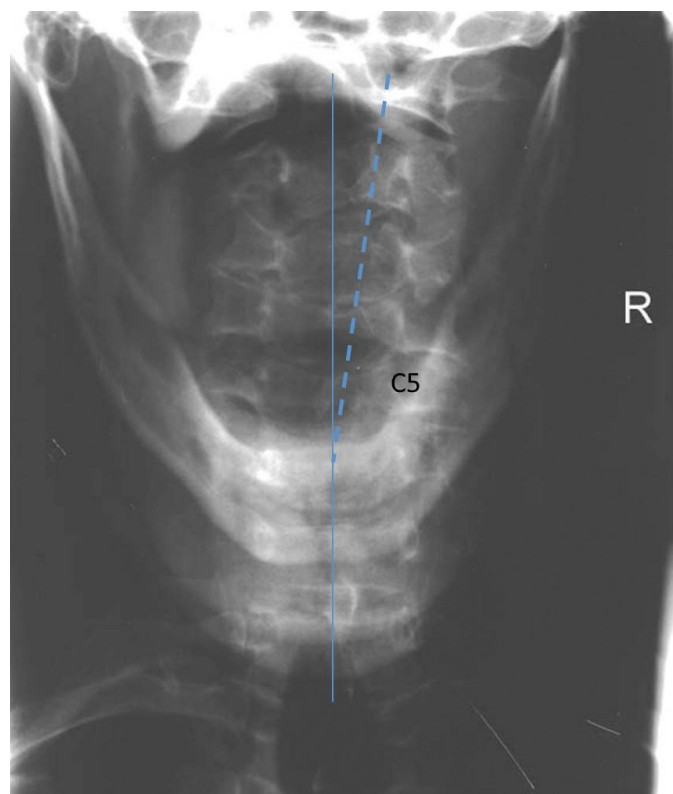


Figure 1:  
*Antero-posterior (AP) view of the cervical spine with open-mouth. This does not represent a standard radiographic view. Separate films for the upper and lower cervical spine are preferred. The rotation of the spinous processes above the level of the dislocation is shown by the dotted line.*

be evaluated. The spinous processes were rotated to the right above the C5 level yielding a doubling of the facet silhouette on the lateral view. Mild-to-moderate degenerative disc disease was present at C3-4, C4-5, and C6-7, with associated osteophytes and disc space narrowing.

The chiropractor immediately referred the patient to the hospital where the neurological status was assessed and advanced imaging performed. The orthopaedic team confirmed the bilateral facet dislocation and a cervical reduction were performed. Specific details regarding the surgical procedure and rehabilitation were not available. A telephone conversation, one year after the surgery, revealed that the patient had returned to work and did not report any residual symptoms.

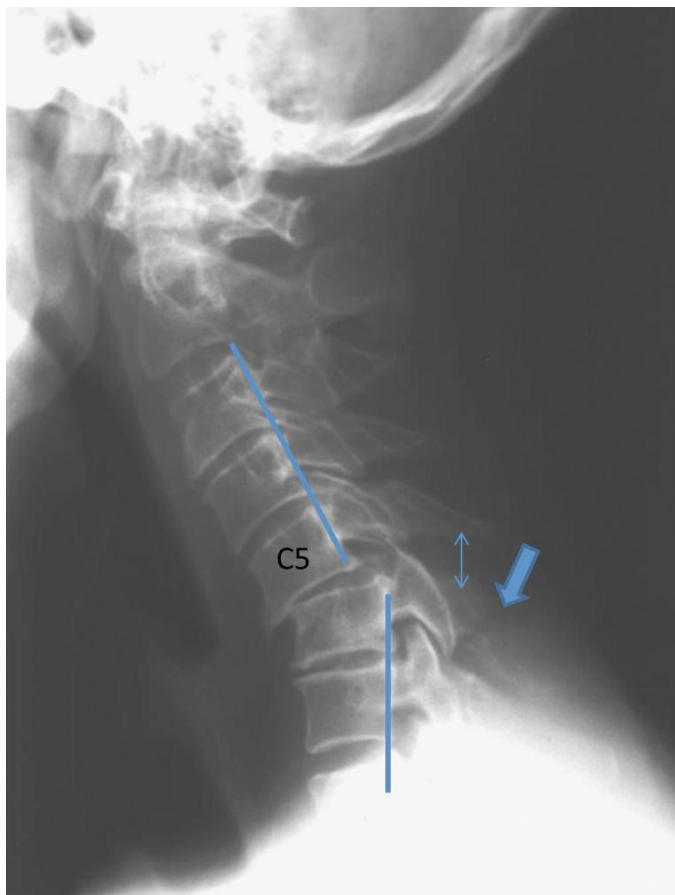


Figure 2:

*Neutral lateral cervical view demonstrating a break in the posterior vertebral body line, an acute kyphosis with separation of the spinous processes (double arrow), the anterior slippage of the C5 vertebral body on C6 as well as the complete separation of the articular surface of the facets indicating bilateral facet dislocation at C5-C6. There is also an oblique radiolucent line in the posterior elements indicating a fracture of the C6 spinous process and laminae (bold arrow).*

## Discussion

### *Clinical presentation*

When considering the severe mechanism of injury that produces cervical dislocation, it is unlikely for patients to present without signs or symptoms of neurological injuries.<sup>16,17</sup> Occasionally, however, signs may be more subtle, as in this particular case. It is estimated that 90% of pa-

tients with interfacetal dislocation will present with symptoms, and between 50% to 90% will suffer from a spinal cord injury.<sup>2,18</sup> One review of surgical cases has shown that, among patients with neurological injuries, approximately 40% had a partial cord lesion, 40% had a complete spinal cord injury, and 20% had sustained injury to the nerve root only.<sup>19</sup> The clinical signs of spinal cord injury in the upper extremities may include loss of sensation or radiculopathy, motor weakness, decreased deep tendon reflexes, and/or the presence of a pathological reflex (e.g. clonus and Hoffman). In the lower extremities, signs of an upper motor neuron lesion may also be observed. Gait can also be abnormal, particularly with “heel-toe” walking. In more extreme cases, a loss of vital functions, paralysis, or death can occur. The vertebral level of the dislocation may have a direct impact on the location and type of symptoms. The amount of displacement of the vertebra appears also in direct linear relationship with the level of neurological impairment.<sup>6</sup> Studies are, however, contradictory on the impact of the pre-injury spinal canal diameter. A larger canal is sometimes found to be protective against spinal cord injuries, while other studies showed no relationship.<sup>20-22</sup>

Once a chiropractor has identified cervical dislocation, whether it be unilateral or bilateral, his or her management options are limited to arranging for safe transportation of the patient to the hospital for rapid evaluation and management by the emergency team.<sup>19</sup> Obviously, spinal manipulation or any manual therapies are contraindicated. A complete neurological evaluation should always be performed and reported to the medical professional, who can then evaluate for neurological stability. Early management is always best, as delays complicate the treatment and decrease the possibility of satisfactory outcomes.<sup>9</sup>

### *Radiological features*

Missed cervical injuries are not a rare occurrence. It is estimated that between 5% to 30% go unrecognized.<sup>23,24</sup> Facet dislocations are among the most frequently missed conditions and they are often categorized as «neglected». Such injuries are defined as “injuries not treated in a timely fashion and found late when options are limited”.<sup>25</sup> It has been shown that this discrepancy can be attributed to the low sensitivity of plain film radiography (three views) to bony injuries. In fact, the sensitivity of radiography in detecting bony injuries is estimated to be approximately

only 50%, compared to computed tomography (CT).<sup>26-28</sup> Radiography remains accepted as a screening tool for patients with blunt trauma; however, its limitations should be understood. An important factor limiting the sensitivity of radiographs is poor image quality. More than 30% of radiographs are deemed inadequate for diagnosis, and in some studies this number can reach up to 80%.<sup>29</sup> Some of the reported issues include poor visualization of crucial anatomy such as the cranio-cervical or cervico-thoracic regions, improper positioning in ambulatory patients, artifacts caused by immobilization devices, and/or failure to obtain the proper radiographic series.<sup>30,31</sup> Flexion-extension studies have not been shown to add information or to increase the sensitivity to detecting fracture, especially since no definite criteria for their interpretation exist. In the same vein, oblique radiographs have not been found to convey additional information, are challenging to obtain, and few radiologists are comfortable with their interpretation.<sup>32-35</sup>

Clinical guidelines have been developed to help practitioners determine if radiography is necessary for a patient with neck trauma. The Canadian C-Spine Rule for Radiography in Alert and Stable Trauma Patients was developed in the late 1990s.<sup>36</sup> This clinical algorithm works by establishing the presence of risk factors for cervical injuries. It has been shown to have a sensitivity of almost 100% for detecting acute cervical spine injury in the emergency department setting, with a potential ordering radiograph rate of 58.2%.<sup>36</sup> Many patients do not require radiographic assessment of the cervical spine after trauma, especially when no signs or symptoms are present. Asymptomatic patients after trauma are defined as those who are neurologically normal, have a normal level of alertness, are not intoxicated, do not have neck pain or midline tenderness, and do not have an associated injury that is distracting. In the present case, the protocol for ordering cervical radiographs was in accordance with the Canadian C-Spine Rule.<sup>36</sup> The patient demonstrated numbness along the C6 dermatome. He was also involved in a high-risk rollover accident, was unable to rotate his neck 45 degrees, and demonstrated midline cervical spine tenderness. Although the patient reported that his previous films from the hospital were read as normal, given these clinical findings, as well as the presence of a palpable protuberance in the patient's neck, the clinician repeated the radiographs. However, in this present case, an incomplete

cervical series was obtained. A neutral lateral view (from base of the skull to T1), a complete AP cervical view demonstrating C3 to T1, and a separate AP open mouth view would have been more appropriate. For high-risk patients, such as those demonstrating frank neurological signs and symptoms, have an altered mental state, and/or those with multiple injuries, CT imaging should always be preferred to plain film radiography; and should also be performed if plain film radiographs are not of acceptable quality.<sup>3,37,38</sup>

### *Treatment*

Treatment options are multiple and depend on the type of injury, the delay in presentation, the type of signs and symptoms present, as well as the associated injuries. Priority is given to the decompression of neurological structures and reperfusion of the tissue first, followed by the restoration of mechanical integrity.<sup>39,40</sup> This can be performed with axial traction and/or manipulation or during surgery.<sup>41</sup> Surgical protocols vary greatly, and different approaches, such as anterior, posterior, or combined have been described in the literature. No consensus exists in the literature however, and decisions are likely to be motivated by the neurologic status of the patient, interpretation of a disc herniation, unilateral or bilateral nature of the injury, as well as surgeon training and experience.<sup>42,43</sup> Cervical facet dislocations include a wide array of bony and disco-ligamentous injuries, making it difficult to compare treatment outcomes and treatment protocols.<sup>44</sup> For example, the presence of an associated disc herniation may prevent attempts at closed reductions.<sup>21,41</sup> It seems that the earlier reduction leads to a better prognosis, whereas a herniated disc noted on post reduction might have an increased risk for a deterioration of neurological status.<sup>19,45</sup> Fractures of a facet also seem to decrease the chance of a successful closed reduction.<sup>46</sup>

### *Conclusion*

Chiropractors often see trauma patients after they have been examined and "cleared" by other health professionals. Regardless of the situation, every patient requires a thorough history and physical examination. Additional or repeat imaging may be necessary and chiropractors should not rely on another professional's decision or interpretation to determine its need. If timely or feasible, chiropractors should also always attempt to review the previous films and report regardless of their source and

date. In the case of cervical facet dislocation, the patient should be immobilised and safely transported to the emergency department for orthopaedic and/or neurological management.

## References

1. Bono CM, Schoenfeld A, Gupta G, Harrop JS, Anderson P, Patel AA, et al. Reliability and reproducibility of subaxial cervical injury description system: A standardized nomenclature schema. *Spine*. 2011;36(17):E1140-E4
2. Panjabi M, Simpson A, Ivancic P, Pearson A, Tominaga Y, Yue J. Cervical facet joint kinematics during bilateral facet dislocation. *European Spine J*. 2007;16:1680-8.
3. Saltzherr TP, Fung Kon Jin PHP, Beenen LFM, Vandertop WP, Goslings JC. Diagnostic imaging of cervical spine injuries following blunt trauma: A review of the literature and practical guideline. *Injury*. 2009;40(8):795-800.
4. Ebraheim N, Patil V, Liu J, Haman S, Yeasting R. Morphometric analyses of the cervical superior facets and implications for facet dislocation. *International Orthopaedics*. 2008;32:97-101.
5. O'Brien P, Schweigel J, Thompson W. Dislocation of the lower cervical spine. *J Trauma*. 1982;22:710-4.
6. O'Connor PA, McCormack O, Noël J, McCormack D, O'Byrne J. Anterior displacement correlates with neurological impairment in cervical facet dislocations. *International Orthopaedics*. 2003;27(3):190-3.
7. Tator C, Carson J, Edmonds V. Spinal injuries in ice hockey. *Clinical sports medicine*. 1998;17(1):183-94.
8. Kuster D, Gibson A, Abboud R, Drew T. Mechanisms of cervical spine injury in rugby union: a systematic review of the literature. *Br J Sports Med*. 2012;46:550-4.
9. Basu S, Malik F, Ghosh J, Tikoo A. Delayed presentation of cervical facet dislocations. *J Orthopaedic Surg*. 2011;19(3):331-5.
10. Carrino JA, Manton GL, Morrison WB, Vaccaro AR, Schweitzer ME, Flanders AE. Posterior longitudinal ligament status in cervical spine bilateral facet dislocations. *Skeletal Radiology*. 2006;35(7):510-4.
11. Inamasu J, Guiot BH. Vertebral artery injury after blunt cervical trauma: an update. *Surgical Neurology*. 2006;65:238-46.
12. Biffel W, Moore E, Elliott J, Ray C, Offner P, Franciose R, et al. The devastating potential of blunt arterial injuries. *Annals Surg*. 2000;231(5):672-81.
13. Mueller C-A, Peters I, Podlogar M, Kovacs A, Urbach H, Schaller K, et al. Vertebral artery injuries following cervical spine trauma: a prospective observational study. *European Spine J*. 2011;20(12):2202-9.
14. Willis BK, Greiner F, Orrison WW, Benzel EC. The incidence of vertebral artery injury after midcervical spine fracture or subluxation. *Neurosurgery*. 1994;34(3):435-41.
15. Yoshihara H, VanderHeiden T, Harasaki Y, Beauchamp K, Stahel P. Fatal outcome after brain stem infarction related to bilateral vertebral artery occlusion – case report of a detrimental complication of cervical spine trauma. *Patient Safety in Surgery*. 2011;5:18.
16. Beyer CA, Cabanela ME, Berquist TH. Unilateral facet dislocations and fracture-dislocations of the cervical spine. *J Bone Jt Surg (Br)*. 1991;73(6):977-81.
17. Kim SW, Ciccarella JM, Fedder IL. Bilateral cervical facet dislocation without neurological injury. *Orthopedics*. [Case Reports]. 2004;27(12):1297-8.
18. Carrino J, Manton G, Morrison W, Vaccaro A, Schweitzer M, Landers A. Posterior longitudinal ligament status in cervical spine bilateral facet dislocation. *Skeletal Radiology*. 2006;35:510-4.
19. Rizzolo SJ, Vaccaro AR, Cotler JM. Cervical spine trauma. *Spine*. [Review]. 1994;19(20):2288-98.
20. Lintner D, Knight R, Cullen J. The neurological sequelae of cervical spine facet injuries. *Spine (Phila Pa 1976)*. 1993;18(6):725-9.
21. Eismont F, Arena M, Green B. Extrusion of an intervertebral disc associated with traumatic subluxation or dislocation of cervical facets. *J Bone Jt Surg [Am]*. 1991;73:1555-60.
22. Ivancic PCP, Pearson AMMD, Tominaga YMDP, Simpson AKBA, Yue JJMD, Panjabi MMP. Mechanism of cervical spinal cord injury during bilateral facet dislocation. *Spine (Phila Pa 1976)*. 2007;32(22):2467-73.
23. Kahn A, Leggon R, Lindsey R. Cervical facet dislocation: management following delayed diagnosis. *Orthopedics*. 1998;21(10):1089-91.
24. Platzer P, Hauswirth N, Jandl M, Chatwani S, Vecsei V, Gaebler C. Delayed or missed diagnosis of cervical spine injuries. *J Trauma*. 2006;61(1):150-5.
25. Sengupta DK. Neglected spinal injuries. *Clinical orthopaedics and related research*. [Review]. 2005(431):93-103.
26. Holmes J, Akkinepalli R. Computed tomography versus plain film radiography to screen for cervical spine injury: a meta-analysis. *J Trauma*. 2005;58(5):902-5.
27. Jones C, Jazayeri F. Evolving standards of practice for cervical spine imaging in trauma: a retrospective review. *Australasian Radiology*. 2007;51:420-5.
28. Mehta S, Goss B, Gibson A, Athanasiov A, Williams R. Computed tomographic artifact suggesting cervical facet subluxation. *Spine (Phila Pa 1976)*. 2011;36(15):E1138-E041.
29. McCulloch P, France J, Jones D, Krantz W, Nguyen T, Chambers C, et al. Helical computed tomography alone compared with plain radiographs with adjunct computed tomography to evaluate the cervical spine after high energy trauma. *J Bone Jt Surg [Am]*. 2005;87(11):2388-94.
30. Mower W, Hoffman J, Pollack C, Zucker M, Browne B, Wolfson A. Screening cervical spine radiography in blunt trauma. *Annals Emerg Med*. 2001;38:1-7.

31. El-Khoury G, Kathol M, Daniel W. Imaging of acute injuries of the cervical spine: Value of plain radiography, CT and MR imaging. *Am J Roentgenology*. 1995;164:43-50.
32. Pollack C, Hendey G, Martin D, Hoffman J, Mower W. Use of flexion-extension radiographs of the cervical spine in blunt trauma. *Annals Emerg Med*. 2001;38:8-11.
33. Knopp R, Parker J, Tashjian J, Ganz W. Defining radiographic criteria for flexion-extension studies of the cervical spine. *Annals Emerg Med*. 2001;38:31-.
34. Freemyer B, Knopp R, Piche J, Wales L, Williams J. Comparison of five-view and three-view cervical spine series in the evaluation of patients with cervical trauma. *Annals Emerg Med*. 1989;18(8):818-21.
35. Silva C, Doria A, Traubici J, Moineddin R, Davila J, Shroff M. Do additional views improve the diagnostic performance of cervical spine radiography in pediatric trauma. *Am J Roentgenology*. 2010;194(2):500-8.
36. Stiell IG, Wells GA, Vandemheen KL, Clement CM, Lesiuk H, De Maio VJ, et al. The Canadian C-spine rule for radiography in alert and stable trauma patients. *JAMA: J Am Med Assoc*. [Multicenter StudyResearch Support, Non-U.S. Gov't]. 2001;286(15):1841-8.
37. Van Goethem JWM, Maes M, Özsarlak Ö, van den Hauwe L, Parizel PM. Imaging in spinal trauma. *European Radiology*. 2005;15(3):582-90.
38. Parizel P, van der Zijden T, Gaudino S, Spaepen M, Voormolen M, Venstermans C, et al. Trauma of the spine and spinal cord: imaging strategies. *European Spine J*. 2010;19(0):8-17.
39. Newton D, England M, Doll H, Gardner BP. The case for early treatment of dislocations of the cervical spine with cord involvement sustained playing rugby. *J Bone Jt Surg (Br)*. 2011;93-B(12):1646-52.
40. O'Dowd J. Basic principles of management for cervical spine trauma. *European Spine J*. 2010;19(0):18-22.
41. Lauweryns P. Role of conservative treatment of cervical spine injuries. *European Spine J*. 2010;19(0):23-6.
42. Nassr A, Lee J, Dvorak M, Harrop J, Dailey A, Shaffrey C, et al. Variations in surgical treatment of cervical facet dislocations. *Spine (Phila Pa 1976)*. 2008;33(7):E188-E93.
43. Lee JY, Nassr A, Eck JC, Vaccaro AR. Controversies in the treatment of cervical spine dislocations. *The Spine J*. 2009;9(5):418-23.
44. Dvorak M, Fisher C, Aarabi B, Harris M, Hubert R, Rampersaud R, et al. Clinical outcomes of 90 isolated unilateral facet fractures, subluxations, and dislocations treated surgically and nonoperatively. *Spine (Phila Pa 1976)*. 2007;32(26):3007-13.
45. Hadley MN, Fitzpatrick BC, Sonntag VK, Browner CM. Facet fracture-dislocation injuries of the cervical spine. *Neurosurgery*. 1992;30(5):661-6.
46. Surgeons CoN. Guidelines for management of acute cervicalspinalinjuries.Introduction.*Neurosurgery*.2002;50(3 Suppl):S1.