



---

## CANADIAN CHIROPRACTIC ASSOCIATION

---

*President* Jeff Warren, BSc, DC

---

## JCCA STAFF

---

*Editor* Allan Gotlib, C.M., BSc, DC  
Canadian Chiropractic Association, Toronto, Ontario

*Associate Editors* Jeff Quon, DC, PhD  
School of Population & Public Health  
Faculty of Medicine, University of British Columbia

Kent Stuber, DC, MSc  
Calgary, Alberta

*Assistant Editors* André Bussi eres, DC, FCCS(C), PhD  
Faculty of Medicine  
McGill University  
Montr al, Qu ebec  
D partement chiropratique  
Universit  du Qu ebec   Trois-Rivi eres  
Trois-Rivi eres, Qu ebec

Pierre C t , DC, PhD  
University of Ontario Institute of Technology

Gregory N Kawchuk, DC, PhD  
University of Alberta, Edmonton, Alberta

Dana J. Lawrence, DC, MMedEd, MA  
Palmer College of Chiropractic Davenport, Iowa

John J. Triano, DC, PhD  
Canadian Memorial Chiropractic College

*Production Co-ordinator* Tami Ehrlich

*Advertising* Editor, Journal of the Canadian Chiropractic Association  
186 Spadina Avenue, Suite 6, Toronto, Ontario M5T 3B2  
Tel: 416-585-7902 877-222-9303 Fax: 416-585-2970

Email: Dr. Allan Gotlib<AGotlib@chiropracticcanada.ca>  
Website: www.jcca-online.org

---

## TYPESETTING

---

Thistle Printing Limited  
35 Mobile Drive, Toronto, Ontario M4A 2P6

# JCCA

## Journal of the Canadian Chiropractic Association

*(Formerly the Canadian Chiropractic Association Journal)*

*Copyright Registered © by the Canadian Chiropractic Association 1961*

*Copyright: The Canadian Chiropractic Association, 2013*

All rights reserved. Without limiting the rights under copyright above, no part of this publication may be reproduced, stored in or introduced into any retrieval system, or transmitted in any form or by any means (electronic, mechanical, photocopying, recording or otherwise), without the prior written permission with the copyright owner and the publisher.

Published by the Canadian Chiropractic Association and issued quarterly

EDITORIAL AND EXECUTIVE OFFICES,  
186 SPADINA AVENUE, SUITE 6, TORONTO, CANADA M5T 3B2

*General Information:* The Journal of the Canadian Chiropractic Association is the official quarterly publication by the Canadian Chiropractic Association. The JCCA is published quarterly by the Canadian Chiropractic Association as a medium of communication between the Association and its members and is a forum for fair comment and discussion of all matters of general interest to the chiropractic profession and the Association. Readers are invited to comment and express their opinions on relevant subjects. Views and opinions in editorials and articles are not to be taken as official expression of the Association's policy unless so stated. Publication of contributed articles does not necessarily imply endorsement in any way of the opinions expressed therein and the Journal and its publisher does not accept any responsibility for them. Business correspondence should be addressed to: the Editor of JCCA, 186 Spadina Avenue, Suite 6, Toronto, Canada M5T 3B2.

### INDEXING SERVICES

JCCA is indexed by PubMed Central, CINAHL (Cumulative Index to Nursing and Allied Health Literature), MANTIS (formerly CHIROLARS), AMED, PASCAL, British Library Complementary Medicine Index, Index to Chiropractic Literature, and selectively by SPORTDiscus.

# Contents

JCCA Vol 57 No 2 ISSN 00083194

## 106 *Perspective*

Climate change: global challenges for the chiropractic profession

Richard Brown, DC, LL.M, FRCC

## 111 *Commentary*

Knowledge Transfer within the Canadian Chiropractic Community.

Part 1: understanding evidence-practice gaps

Greg Kawchuk, BSc, DC, MSc, PhD

Paul Bruno, BHK, DC, PhD

Jason W. Busse, DC, PhD

André Bussi eres, BSc, DC, FCCS(C), MSc, PhD

Mark Erwin, BA, DC, PhD

Steven Passmore, Hons BKin, MS, DC, PhD

John Srbely, BSc, DC, PhD

## *Original Articles*

## 116 Transient osteoporosis of the hip: A case report

Katherine Van Wagenen, BS

Paul Pritchard, DC

John A. Taylor, DC, DACBR

## 123 Insufficiency fracture of the tibial plateau after anterior cruciate ligament reconstructive surgery: a case report and review of the literature

Jessica J. Wong, BSc, DC, FCCS(C)

Brad Muir, HBSc (Kin), DC, FRCCSS(C)

## 132 Therapeutic interventions employed by Greater Toronto Area chiropractors on pregnant patients: results of a cross-sectional online survey

Tammy Yuen, BSc (Hons)

Kayla Wells, BKin (Hons)

Samantha Benoit, BSc

Sahila Yohanathan, BSc (Hons)

Lauren Capelletti, BKin (Hons)

Kent Stuber, BSc, DC, MSc

## 143 Straight Back Syndrome: positive response to spinal manipulation and adjunctive therapy – A case report

Paul M. Gold, BSc(H), DC

Brianna Albright

Sabine Anani

Heather Toner, BSc (Kin)

# Contents

---

JCCA Vol 57 No 2 ISSN 00083194

---

- 150 Myxopapillary ependymoma as a cause of back pain in a young male – A case report  
Trung P Ngo, BSc, DC  
John Dufton, DC, MSc, MD  
Paula J Stern, BSc, DC, FCCS(C)  
Omar Islam, MD, FRCPC, DABR
- 156 Interexaminer reliability of cervical motion palpation using continuous measures and rater confidence levels  
Robert Cooperstein, MA, DC  
Morgan Young, DC  
Michael Haneline, DC, MPH
- 165 Frequency of use of diagnostic and manual therapeutic procedures of the spine currently taught at the Canadian Memorial Chiropractic College: A preliminary survey of Ontario chiropractors. Part 2 – procedure usage rates  
Brian Gleberzon, DC, MHSc  
Kent Stuber, BSc, DC, MSc
- 176 Comminuted scapular body fractures: A report of three cases managed conservatively in chiropractic settings  
Julie Lynn Scarano, DC, CCSP, CCWP  
Matthew Richardson, DC, DACBR  
John A. Taylor, DC, DACBR

# Editorial Board

*Alan H Adams* DC  
Texas Chiropractic College  
Pasadena, Texas

*Kelly E. Donkers Ainsworth* DC, MD,  
FRCPC  
Pediatric Radiology Fellow  
The Hospital for Sick Children  
Toronto, Ontario

*Carlo Ammendolia* DC, PhD  
University of Toronto

*Samuel Bederman* MD, PhD, FRCSC  
Department of Orthopedic Surgery  
University of California at Irvine  
Orange, CA

*Paul Bruno* DC, PhD  
Faculty of Kinesiology and Health  
Studies  
University of Regina

*Brian Budgell* DC, PhD  
CMCC

*Jason Busse* DC, PhD  
McMaster University

*J David Cassidy* DC, MSc, PhD, FCCS(C),  
Dr Med Sc  
University of Southern Denmark

*Raphael K Chow* MD, FRCP(C)  
University of Toronto

*Colin M Crawford* B App Sc (Chiro),  
FCCS(C), MSc, Grad Dip Neuro, MB BS  
Perth, Australia

*Simon Dagenais* DC, PhD  
Boston, Massachusetts

*Martin Descarreaux* DC, PhD  
Université du Québec à Trois-Rivières

*John A. Dufton* DC, MSc, MD, FRCPC  
Staff Radiologist  
University Hospital of Northern  
British Columbia  
Prince George, British Columbia

*Mark Erwin* DC, PhD  
University of Toronto

*Brian Gleberzon* DC, MHSc  
CMCC

*Richard Goldford* BSc, DC, MBA,  
FCCSS(C), FCCPOR(C)  
Toronto, Ontario

*Bart Green* DC, MEd, DACBSP  
Naval Medical Center, San Diego  
San Diego, California

*François Hains* DC, FCCS(C), MSc  
Dorval, Québec

*Scott Haldeman* DC, MD, PhD, FRCP(C)  
University of California  
Irvine, California

*Jill Hayden* DC, PhD  
Dalhousie University  
Halifax, NS

*Walter Herzog* PhD  
University of Calgary

*Thomas E Hyde* BA, DC, DACBSP  
N Miami Beach, Florida

*Claire Johnson* DC, MEd, DACBSP  
National University of Health Sciences  
Lombard, Illinois

*Mohsen Kazemi* RN, DC, FCCSS(C),  
FCCPOR(C), MSc  
CMCC

*Clark R Konczak* MSc, DC, DABCO,  
FCCO(C), FRCCSS(C)  
Victoria, BC

*Deborah Kopansky-Giles* DC, FCCS(C),  
FICC, MSc  
St. Michael's Hospital  
Toronto, Ontario

*Doug M Lawson* BA, DC, MSc  
D'Youville College

*Cynthia Long* PhD  
Palmer Centre for Chiropractic Research  
Davenport, Iowa

*Marion McGregor* DC, PhD  
CMCC  
Toronto, Ontario

*William C Meeker* DC, MPH  
Palmer Chiropractic University System  
San Jose, CA

*Robert D Mootz* DC  
Associate Medical Director for  
Chiropractic, State of Washington  
Department of Labor and Industries  
Olympia, WA

*Bernadette Murphy* DC, PhD  
University of Ontario Institute of  
Technology

*Martin Normand* DC, PhD  
UQTR

*Steven Passmore* DC, PhD  
Faculty of Medicine  
University of Manitoba

*Stephen Perle* DC, MS  
University of Bridgeport  
Bridgeport, CT

*Reed B Phillips* DC, PhD, DACBR  
Southern California University of  
Health Sciences

*Mathieu Piché* DC, PhD  
UQTR

*John J Riva* DC  
Department of Family Medicine  
McMaster University  
Hamilton, Ontario

*John Z Srbely* DC, PhD  
University of Guelph

*Igor Steiman* MSc, DC, FCCS(C)  
CMCC

*John S Stites* DC, DACBR  
Palmer College of Chiropractic  
Davenport, Iowa

*Donald C Sutherland* DC, LLD, FICC  
CMCC

*John A M Taylor* DC, DACBR, FCCR(C)  
D'Youville College  
Buffalo, NY

*Haymo Thiel* DC, MSc (Orth), FCCS(C),  
Dip Med Ed, PhD  
Anglo-European College of  
Chiropractic  
Bournemouth, England

*Gabrielle M van der Velde* BSc, DC,  
FCCS(C), PhD  
Toronto Health Economics  
and Technology Assessment  
Collaborative  
University of Toronto

*Marja J Verhoef* PhD  
University of Calgary

# Climate change: global challenges for the chiropractic profession

Richard Brown, DC, LL.M, FRCC\*



Richard Brown, DC, LL.M, FRCC\*

## Introduction

History affords us numerous examples of circumstances where those fighting on the same side have conspired to harm each other, even to inflict mortal damage. This tendency has displayed itself throughout the history of the chiropractic profession, with disagreements over philosophy and nomenclature dominating the agenda<sup>1</sup> whilst

external detractors have looked on with the smug satisfaction of knowing that internal tensions are perpetuating division and stunting growth<sup>2</sup>.

In an era of health system transformation it is clear that the climate is changing.<sup>3</sup> Just as western society has gradually realised the impact of global ecological change and has adapted its behaviour accordingly, so must we as chiropractors realise that the healthcare environment is changing. While this presents challenges, it also gifts us unprecedented opportunities to evolve. What is essential is that we accept that climate change is happening and commit ourselves to bravely tackling the issues before us.

## Identity

I have consistently argued that for the profession to progress and be a key player in modern healthcare systems, it must jettison some of the historical baggage that has weighed it down over decades and commit itself to modern, evidence-based, research driven healthcare.<sup>4</sup>

This does not of course mean that chiropractic should suddenly turn its back on the philosophies and practice that has shaped its development and assured its survival since 1895. The power of the spinal adjustment, the consideration that the integrity of the spine has a direct impact on human health and the view that as living organisms we are more than simply the sum of our parts have all been guiding principles. However, the language in which we cloak our profession often suggests an archaic mindset and a refusal to move away from pseudo-religious concepts often embraced by complementary and alternative medical practices.

It is therefore of paramount importance that the chiro-

---

\*President, British Chiropractic Association  
The Lansdown Clinic, 1 High Street, Stroud, Gloucestershire GL5 1AU  
r.brown@lansdownclinic.co.uk  
©JCCA 2013

practic profession agrees a universal identity which is consistent around the world. Back in 2005, the WFC published the results of its identity consultation.<sup>5</sup> At this time, it was decided that the most appropriate public identity for the chiropractic profession was that they should be the spinal healthcare experts in the healthcare system. This was the result of two years of intensive work including a grass roots electronic survey of chiropractors worldwide.

It is widely considered that are seven pillars upon which chiropractic's identity should be grounded.

1. An ability to improve function in the neuromusculoskeletal system and have a distinct impact on the overall health, wellbeing and quality of life.
2. A specialised approach to examination, diagnosis and treatment which must be based on the best available research and clinical evidence, with a particular emphasis on the relationship between the spine and the nervous system.
3. A tradition of effectiveness and patient satisfaction.
4. An avoidance of drugs or surgery, enabling patients to avoid these where possible.
5. Expertly qualified providers of spinal adjustment, manipulation and other manual treatments, exercise instruction and patient education.
6. Collaboration with other health professionals
7. A patient-centred and biopsychosocial approach, emphasising the mind-body relationship in health, the self-healing powers of the body and individuals' responsibility for health and encouraging patient interdependence.

Late in 2012, Palmer College released its own identity statement.<sup>6</sup> This had many similarities with the WFC 2005 statement, positioning chiropractors as the primary health care professionals for spinal health and well being.

The synchronisation of identity statements from two of the world's leading organisations must surely gift us the opportunity to create a global message for the consumers and potential consumers of spinal health care services. Now is the time to bring together educators, academics, researchers and clinicians to finally agree how chiropractic should be portrayed to the world.

## Education

While we gladly accept that education in any discipline may be delivered in a range of formats, with differing emphases on individual components, there are inevitable boundaries. Inspectorates of schools, prisons and other state institutions ensure that minimum standards of education are attained, which correspond to nationally agreed frameworks. In medicine and dentistry, despite different emphasis on delivery (traditional didactic learning versus problem-based learning, for example) there is a broad consensus when it comes to required levels of competency and professional standards.

However, the evolution of the chiropractic profession, historically characterised by private educational institutions, has meant that a largely self-regulating mechanism has prevailed. The various Councils on Chiropractic Education have set their own accreditation criteria<sup>7</sup>, but flexibility of interpretation has meant that the delivery of chiropractic education between institutions remains startlingly different. While some focus on a strictly science-based and biomedical model, others steer their students towards more philosophical tenets.

Within the chiropractic profession many celebrate the diversity of educational approaches in chiropractic, lauding it as being symbolic of the various strands of development that have woven their way into the fabric of our profession. At the same time, others bemoan the fact the disparity and differences between programmes of study have created an indistinct image of chiropractic education, one where examples of excellence are interspersed with less robust programmes of study. The long term survival of chiropractic education outside the mainstream university network appears in some regions uncertain and this has been reflected in declining student numbers.

There may be a number of factors at play. The costs of education and training are such that in a global recession, they may have become prohibitively expensive. Opportunities for graduates may be more limited. Adverse media coverage and tarnished reputations of the profession in some areas may have reduced the demand for chiropractic. But perhaps one of the biggest challenges to the profession is that other manual therapy professions have realised the market for skilled spine care services and have focused their attention on what is seen as a vast untapped market.

The harmonisation of education throughout the world

must surely, therefore, be one of the goals of the chiropractic profession. As the world demands evidence-based, research driven healthcare<sup>8</sup>, there can no longer be a place where historical concepts are portrayed as fact and where students are expected to swear an undying allegiance to the theories of yesteryear.

I am not calling for every chiropractic centre of learning to become clones of one another; it is crucially important that schools, colleges and universities providing chiropractic education retain their own identity. However, in order to facilitate and foster information exchange, harmonisation of procedures and policies and attainment of comparable qualifications, there must be a robust review of the acceptability of programmes in the context of modern educational frameworks if they are to be deemed acceptable within the wider healthcare community.

In tandem with this, we must also see an expansion of the numbers of available programmes of study. The growth of the chiropractic profession materially depends upon the number of its practitioners being represented in adequate numbers over the face of the globe. We must not, therefore, be afraid of adopting new approaches to growing chiropractic in areas that are under-represented.

## Research

It is often said that research is the currency of the profession. For the profession to compete and attain the cultural authority it strives to achieve, it is essential that there is an international commitment to research. This should first examine what we do primarily as chiropractors – spine-based care using manipulation – as well as the other components that make up a modern chiropractor's package of care: supervised and home based exercise, spinal stabilization programmes, medical acupuncture and soft tissue techniques.

We must become the default spinal care experts and to be so we must be active – and be seen to be active – in the field of spinal research. Canada is one of the world leaders in grasping the nettle of spinal research and committing funds to it. The production of clinical guidelines<sup>9</sup>, the funding of Research Chairs and the willingness to collaborate with other stakeholders, both within the outside the profession, demonstrate clear leadership. World class chiropractic researchers are being heard and respected within forums that our ancestors would never have considered possible.

Following leads set by Canada and Denmark, other chiropractic research organisations are now appearing in Europe. The UK, Norway, Sweden and France have all now set up their own national research organisations, but in every nation where chiropractic exists we need to be sure that data is collected and the knowledge base is widened. We need to know how chiropractic care may impact on Africans, on Asians and Middle Eastern populations as well as in our own well-developed North American and European regions.

In a challenging environment where funds for chiropractic are limited, priorities need to be identified to ensure maximum effectiveness and utilisation of outcomes. Collaborations may provide an excellent platform for developing international research and ongoing work is being done to develop the North Atlantic Research Collaboration. This is an affiliation of the national associations of the UK, Canada, Denmark, Norway, Switzerland and Sweden and it is hoped that a shared research agenda between the parties will facilitate knowledge that will enhance service delivery and mainstream integration.

With enormous costs associated with sickness absence<sup>10</sup>, demonstrating chiropractic's role in the prevention of occupational injuries and disability carries huge potential societal and economic advantage. Research directed at preventative care for specific and general populations also feeds into the health policies of many developed and developing nations.

Cost effectiveness will undoubtedly be the driver in terms of chiropractic's role in health systems. Politicians can make all the right noises about how concerned they are about clinical effectiveness and life saving care, but the bottom line is how much it will all cost and where the best deals are to be had. Anything that shows that chiropractic is cheaper than the competition will attract the attention of key decision-makers. Reduced costs, reduced waiting times, and the satisfaction of patients, who of course are those who elect politicians to office, will get chiropractic noticed in the healthcare marketplace.

## Widening access

In developing the chiropractic profession, we must constantly endeavour to widen access to care beyond those who can afford it. If we are to become the spinal health and wellbeing experts, we must strive to ensure that the services that we offer are available to everyone in society.



Widening access to care will increase the exposure of chiropractic to groups otherwise unable to benefit from what we as healthcare professionals can offer. This is relevant not only here in Canada on a socioeconomic level, but also internationally, and initiatives by Scott Haldeman and World Spine Care in Botswana and India as well as humanitarian missions to disaster zones and other developing areas of the world have helped to illustrate the compassionate nature of chiropractors in the delivery of healthcare.

On a local level, the involvement of chiropractic organisations in public health must be prioritised. As neuromusculoskeletal experts, governments, organisations and society expect chiropractors to be active in the field of public health. Here, there is of course no instantaneous reward; no queues of patients starting to form in an orderly fashion outside chiropractors' offices and no dramatic upturn in terms of universal acceptance. However, what engagement in public health initiatives achieves is authority through altruism.

The identification of back pain as the single leading cause of disability worldwide, with MSK disorders as a group being the second greatest cause after cardiovascular conditions, should propel us all to become involved in health promotion. *The Lancet's* December report<sup>11</sup>, supported by the WHO, should be a clarion call to the chiropractic profession to take ownership of the responsibility to educate populations in the area of spinal health.

Whether it be safer lifting campaigns, perfect posture initiatives or spinal exercise drives, chiropractors should be at the forefront of any and all spinal health education. If we are to satisfy the weight of expectation that society will place on us as experts, we must address that expectation, not just by the effectiveness of our adjustments or diagnostic techniques, but by showing that we have a concern for health prevention strategies. Again, this is something that should be the product of effective leadership and strong collaboration. The *Straighten Up* and *Just Keep Walking* campaigns are examples of excellent work but we must dedicate funds and energy to ensuring that with the opportunities before us chiropractic is positioned as a public health leader in enhancing and improving the health of our nations.

### Policy input and research

As a profession, it is imperative that we not only reach the

spines of the public, but also the minds of our politicians. Engagement in health policy and involvement in helping to steer the direction of health transformation is vital if we are to secure recognition and credibility. In the changing climate of health systems, the challenge for the chiropractic profession is to have a voice on matters of policy and decision making, particularly in the field of neuromusculoskeletal care.

This is largely a factor of resource allocation and political knowledge. The lack of formal regulation in many nations makes Government links difficult to forge and the relative immaturity of the profession in certain regions makes inroads a distinct challenge. With opportunities opening up in the brave new world of modern healthcare, it may therefore be relevant for future international congresses to consider sharing knowledge and skills in the fields of lobbying and political networking.

### Developing leadership skills

The outdated view of leadership are that leaders are marked out for greatness from an early age and that if you are not a born leader, there is little that you can do to become one. The persistence of this view in some quarters is a great pity, but the modern view, and one that I wholeheartedly support, is that with perseverance, determination, passion and hard work, anyone can become an effective leader.

But leadership in chiropractic seems to be something that, certainly when I was a student, was missing from the curriculum. We were taught to assess, diagnose, adjust, x-ray and write reports, all essential attributes in clinical practice, but we were not given any advice on how to be leaders.

Of course, it might be argued that to teach leadership is not the responsibility of the educational institutions, and they may be right. Their role is to produce safe, competent, confident graduates. So whose role is it to ensure that there is a legacy of effective and strong leadership that is passed on to future generations of chiropractors?

The truth is that probably we all have a duty to communicate leadership. We must display strength during periods of adversity and humility during periods of celebration. We must have a vision for the future and turn that vision into a reality. And we must have a passion for what we do such that we may get up early and go to bed late, we stay excited about what we do, we see potential in others and be thrilled when they succeed.

I believe that there is scope for a leadership programme in chiropractic. This can be organised on a regional, national or global level but its essence must be that we can be assured of strong, committed leadership to develop the profession worldwide. This calls for investment, both financially and in time, but such an investment will be rewarded many times over. Guidance, mentoring and stewardship should be as much a feature of graduate development as practice management. We are not all destined to become leaders of national or Provincial organisations, but every graduate chiropractor will need leadership skills as they navigate their way through the intricate windings of their careers as clinicians, clinic owners and beyond.

### Strategy

In light of the changing climate in healthcare what should be our key strategies to overcoming the challenges that lay before us? Strategy is all about shaping the future and for us as chiropractors we must develop a strategy that is future focused and looks at the unmet needs of patients and society. The area of spinal health is a vast, largely untapped and currently mismanaged global burden but for chiropractic to seize opportunities it must carefully plan its strategy.

In an era of climate change, our profession must be prepared for all weathers and must plan accordingly. We must continually monitor the external environment and however cosy we might feel in our own cocooned environment, we must be mindful of the conditions outside.

### Conclusion

We must consider a strategy that best serves the political, economic and healthcare climate of our times. We have important choices to make. Darwin or Dogma? Progression or regression? Survival or submission?

Events around the globe are conspiring to make this one of the most dynamic periods of chiropractic's history. Great strides have been made. Regulation, education and research have flourished. Yet divisions persist. For chiropractic's sake, let us meet our global challenges with fortitude, ensure sound professional governance and be ready to adapt as the healthcare climate changes.

### References

1. Phillips R. The battle for innate. *J Clin Humanities*. 2004; 2-10.
2. Ernst E. UK chiropractic: regulated but unruly. *J Health Serv Res Policy*. 2009 Jul; 14(3): 186-7.
3. Kates N, Hutchinson B, O'Brien P, Fraser B, Wheeler S, Chapman C. Framework for advancing improvement in primary care. *Healthc Pap*. 2012; 12(2):8-21.
4. Brown RA. After the storm: what have we learned? *Chiropractic Report*. 2011; 25: 1-5.
5. Carey P, Clum G, Dixon P. Final report of the identity consultation task force. 2005. Accessed at [http://www.wfc.org/website/images/wfc/docs/as\\_tf\\_final\\_rept-Am\\_04-29-05\\_001.pdf](http://www.wfc.org/website/images/wfc/docs/as_tf_final_rept-Am_04-29-05_001.pdf).
6. Palmer College Identity Statement. Accessed at <http://www.palmer.edu/Identity-Statement/>.
7. The Councils on Chiropractic Education International. <http://www.cceintl.org/>
8. Holmes B, Scarrow G, Schellenberg M. Translating evidence into practice: the role of health research funders. *Implement Sci*. 2012 Apr 24; 7:39.
9. Bryans R, Descarreaux M, Duranleau M, Marcoux H, Potter B, Ruegg R, Shaw L, Watkin R, White E. Evidence based guidelines for the chiropractic treatment of adults with headache. *J Manipulative Physiol Ther*. 2011; 34(5): 274-289.
10. UK Office for National Statistics. Sickness absence in the labour market. April 2012. Accessed at [http://www.ons.gov.uk/ons/dcp171776\\_265016.pdf](http://www.ons.gov.uk/ons/dcp171776_265016.pdf)
11. Salomon JA, Vos T et al. Common values in assessing health outcomes from disease and injury: disability weights measurement study for the Global Burden of Disease Study 2010. *Lancet*. 2012 Dec 15; 380 (9859): 2129-43.

# Knowledge Transfer within the Canadian Chiropractic Community. Part 1: Understanding Evidence-Practice Gaps

Greg Kawchuk, BSc, DC, MSc, PhD<sup>1</sup>

Paul Bruno, BHK, DC, PhD<sup>2</sup>

Jason W. Busse, DC, PhD<sup>3,8</sup>

André Bussi eres, BSc, DC, FCCS(C), MSc, PhD<sup>4</sup>

Mark Erwin, BA, DC, PhD<sup>5</sup>

Steven Passmore, Hons BKin, MS, DC, PhD<sup>6</sup>

John Srbely, BSc, DC, PhD<sup>7</sup>

### Overview

This two-part commentary aims to provide a basic understanding of knowledge translation (KT), how KT is currently integrated in the chiropractic community and our view of how to improve KT in our profession. Part 1 presents an overview of KT and discusses some of the common barriers to successful KT within the chiropractic profession. Part 2 will suggest strategies to mitigate these barriers and reduce the evidence-practice gap for both the profession at large and for practicing clinicians.

### Introduction

New knowledge is created at such a rapid pace that health care professionals find it difficult, if not impossible, to

keep up to date. In a single day alone, 75 clinical trials and 11 systematic reviews are published.<sup>1</sup> As a result, it is incredibly difficult to keep up to date with the literature in order to implement new knowledge that may optimize patient care, increase benefits, or reduce harm. In an effort to promote evidence-based practice, many researchers and funding agencies are now focusing on processes to deliver emerging evidence successfully to clinicians and other stakeholders; this process has been termed KT.

### What is KT?

KT is defined by the Canadian Institutes of Health Research (CIHR) as ‘a dynamic and iterative process that includes synthesis, dissemination, exchange and ethically

---

<sup>1</sup> Associate Professor and Canada Research Chair in Spinal Function, Faculty of Rehabilitation Medicine, University of Alberta

<sup>2</sup> Assistant Professor and CCRF Research Chair in Neuromusculoskeletal Health, Faculty of Kinesiology and Health Studies, University of Regina

<sup>3</sup> Assistant Professor, Department of Anesthesia, McMaster University, Hamilton, Canada

<sup>4</sup> Assistant Professor and CCRF Research Chair in Rehabilitation Epidemiology, School of Physical and Occupational Therapy, McGill University. Professor, Universit e du Qu ebec   Trois-Rivi eres

<sup>5</sup> CCRF Professorship in Disc Biology, Assistant Professor Divisions of Orthopaedic and Neurological Surgery, The Spine Programme, University of Toronto, Toronto Western Hospital, Toronto Western Research Institute

<sup>6</sup> Assistant Professor, CCRF Professorship, School of Medical Rehabilitation, Faculty of Medicine, University of Manitoba; Assistant Professor (Adjunct), Research Department, New York Chiropractic College

<sup>7</sup> Assistant Professor and CCRF Chair in Spine Mechanics and Neurophysiology, Human Health and Nutritional Science, University of Guelph

<sup>8</sup> Assistant Professor, Department of Clinical Epidemiology and Biostatistics, McMaster University, Hamilton, Canada

### Corresponding author’s contact information

Email: greg.kawchuk@ualberta.ca

Address: Faculty of Rehabilitation Medicine, University of Alberta

Edmonton, Alberta, T6G 2G4 Canada

Phone:(780) 492-6891

### Declaration:

The authors have no conflicts of interest to declare regarding this paper or the material described therein. Dr. Kawchuk receives support funding from the Canada Research Chairs program. Dr. Busse is funded by a New Investigator Award from the Canadian Institutes of Health Research. Dr. Erwin receives partial salary support the Canadian Memorial Chiropractic College and the University Health Network. Drs. Bruno, Busse, Bussi eres, Erwin, Passmore and Srbely receive full or partial funding support from the Canadian Chiropractic Research Foundation.

  JCCA 2013

sound application of knowledge to improve the health of Canadians, provide more effective health services and products, and strengthen the health care system'.<sup>2</sup> In other words, it is the ongoing process of effectively translating current and up-to-date research into practice and policy.

### What KT is not...

A commonly held misconception is that the process of KT is a pipeline that transports information generated by academics to awaiting clinicians. Knowledge translation does not involve just two parties, or the simple exchange of information. In reality, KT (and knowledge exchange) is a roadmap of two-way streets that creates a system of interconnections between researchers and clinicians, patients, government, policy makers, regulators, payers, guideline developers, and other stakeholders. Through these interconnections, it is hoped that all involved will use shared knowledge to improve health care delivery in a measurable way (e.g. effectiveness, cost, access to care, etc.).<sup>3</sup> As such, creating structured two-way avenues for collaboration between chiropractic clinicians, scientists, policy-makers, and others is a vital element in the facilitation of effective and efficient KT in the chiropractic profession.

In contrast, activities such as technology integration, commercialization of a product, and continuing education (i.e. professional development) may not necessarily constitute KT if they do not engage the appropriate stakeholders and/or do not result in improved outcomes.<sup>3</sup>

### Why is KT important?

In 2000 and 2001, two landmark reports were published that clearly defined the importance of KT. Published by the Institute of Medicine (IOM), 'To Err is Human'<sup>4</sup> and 'Crossing the Quality Chasm',<sup>5</sup> drew attention to the gap between what clinicians know as opposed to what clinicians actually do. This gap was seen as an important cause of overuse, misuse, and underuse of health care services. In addition to defining the impacts arising from this gap, the second IOM report proposed a *reason* for the existing gap, namely that health care delivery has fallen well short in its ability to translate research into practice and policy, and to apply new technology safely and appropriately.<sup>5</sup>

A major implication arising from this observation is that patients don't always receive safe and effective health care and, if they do, it may not be delivered in a

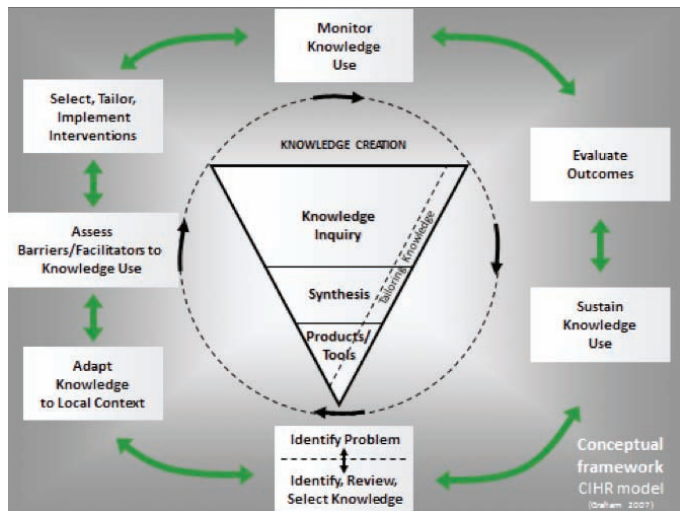


Figure 1. *The Knowledge-to-Action process developed by Graham et al. (2006). The funnel represents knowledge creation, and the cycle represents the application of knowledge (action).*

timely manner. As a result, many feel that much of society's investment to date in biomedical, clinical, and health research has had limited impact. To better understand the extent of how the evidence-practice gap contributes to adverse effects on population health, social welfare, and economic productivity, various global organizations are now cataloguing gaps in primary care, specialty care, and in-patient care provided by most health disciplines.<sup>6</sup> Studies in industrialized countries including North America, Australia, and Europe have identified that up to 30 to 40% of patients do not receive treatments of proven effectiveness, while approximately 25% receive care that is unnecessary or potentially more harmful.<sup>7,8</sup> While little is known regarding similar gaps for chiropractic care, there are no compelling reasons to suggest that the magnitude of these gaps are any different within the chiropractic profession. In fact, the management of back and neck pain is recognized as having poor adherence to, and wide variations in, established best practices.<sup>9-13</sup>

### Understanding KT

The CIHR Knowledge-to-Action model<sup>14</sup> helps conceptualize ways in which evidence-practice gaps can be addressed toward changing professional behavior with the ultimate outcome of improving health (Figure 1). Recom-

mended steps to identifying and addressing knowledge-practice gaps include problem identification, selection of best practices relevant to the problem, and assessing barriers to practice change. Together, these steps suggest strategies that can potentially narrow research-practice gaps (Part 2). In practice, the Knowledge-to-Action model identifies selected strategies which are then disseminated or implemented using various means; changes in practice and other trends can then be monitored. The impact of these strategies are then evaluated and additional strategies are implemented to help improved practices become sustained.<sup>14,15</sup> This process is not foolproof, and adapting the model to specific situations can be a difficult task before success is realized.

### The size of the evidence-practice gap in chiropractic

Narrowing the evidence-practice gap is an ongoing exercise for any health profession. While there are several approaches to reducing a profession's evidence-practice gap (Part 2), it is critical to assess the size of the gap to determine what strategies to use and whether current KT strategies are effective.

Several different approaches exist with respect to measuring the size of the gap in the chiropractic profession. While it is not our intent to provide an exhaustive list, some approaches are easier to appreciate than others. For example, one simple way of assessing the size of the evidence-practice gap in chiropractic is to ask yourself: "What has changed in practice since I graduated?" Alternatively, another simple approach is to contrast what is done in your practice to what recent clinical practice guidelines recommend.

No matter how the gap is measured, it would appear to be significant.

### Addressing our own evidence-practice gap

While the profession may not presently have an informed, planned, and measurable approach to reducing the evidence-practice gap, there are examples where our ability as a profession to generate new, meaningful knowledge and our willingness to incorporate it into our clinical practice has succeeded. For example, it can be argued that chiropractic clinicians' understanding of the relation between manipulation and adverse events is current and informed by research. Unfortunately, there are many other

examples where meaningful knowledge has been generated in our profession, but has not been adopted into practice. Specifically, the Neck Disability Index was created by chiropractic researchers Sil Mior and Howard Vernon in 1991. This simple tool has become the international standard for measuring neck function. Yet, a recent survey suggests that many chiropractors do not use this tool in daily practice.<sup>16</sup> Additionally, investigations related to the prediction of short-term and long-term outcomes in back pain patients receiving chiropractic care have shown that early improvement in the course of treatment appears to be a crucial factor,<sup>17-22</sup> and is a strong predictor of outcome at 3 and 12 months.<sup>23-25</sup> Despite this body of evidence, we suspect that many chiropractors do not use this criteria (i.e. lack of improvement within the first few treatments) as an indication that the patient may best be served through an alternative treatment strategy. As a result, there is an increased probability that a single patient may receive very different care, with different results, if they were to see a number of different chiropractors<sup>26</sup> (a phenomenon present in many other clinical disciplines). Understanding the reasons why practice variations exist and the barriers to optimizing care are extremely important in regard to effectively reducing practice gaps.

### Barriers to KT in the chiropractic community

A systematic approach to KT can help understand why a specific gap persists between what is known to be effective, what is done in chiropractic practice and how this gap might be reduced.

Several studies have itemized the primary barriers to implementing evidence in clinical practice in general. These include a lack of time and the lack of skills to navigate and appraise literature. While these are two important barriers, over 250 others have been identified with respect to specific KT activities involving physicians alone.<sup>27</sup> Quite often, these barriers are easy to appreciate if they are grouped into those affected by individual clinicians (e.g. lack of awareness, lack of familiarity, lack of agreement, lack of self-efficacy, lack of outcome expectancy, and inertia of previous practice), and those external to clinicians (e.g. patients, guidelines, and practice environment).<sup>28</sup>

While these general barriers are common in many health professions, there are additional barriers which (although not specific to the chiropractic profession) are certainly well-known characteristics of our profession.

On the supply side, there is limited research capacity to generate knowledge within the profession, with approximately 1% of the chiropractic profession conducting research in Canada.<sup>29</sup> While this figure is nearly twice as much among physician-scientists in the US, the numbers of full time MD researchers has remained rather stable in the past decade.<sup>30</sup>

Another barrier for our profession is the suggestion that when compared to other professions, the chiropractic profession places a lower value on scientific knowledge as compared to individual expertise.<sup>31,32</sup> Chiropractic is also characterized by a large percentage of clinicians practicing in solo practice, which can limit opportunities to interact with colleagues and other professions.<sup>33,34</sup>

Additionally, the profession tends to have a short history with decision support systems (e.g. clinical decision rules, guidelines, etc), and may trivialize their use. A limited number of chiropractic guidelines have been published since the Mercy Guideline in 1993,<sup>35</sup> and divergent recommendations among available guidelines may only serve to confuse clinicians.<sup>36</sup>

Finally, like most other professions, chiropractic has yet to develop coordinated efforts to address KT issues between researchers, practitioners, and stakeholders while ongoing debates, legislation, and internal evolution about the chiropractic profession's own identity<sup>37</sup> result in low coherence of beliefs and evidence-based practices.

## Summary

In this commentary, we described the process of KT and its importance in optimizing health care delivery through the effective and efficient integration of available and new knowledge into practice and policy. In addition, we highlighted several barriers to KT, including those that are common to most health care disciplines, and those that are of particular relevance to the chiropractic profession (e.g. limited research capacity, a greater emphasis on individual expertise than scientific knowledge). In Part 2, we will suggest strategies to narrow the evidence-practice gap in our profession, as well as some tools that may provide early success in this regard.

## Next issue:

### **Knowledge Transfer within the Canadian Chiropractic Community.**

### **Part 2: Narrowing Evidence-Practice Gaps.**

## References

1. Bastian H, Glasziou P, Chalmers I. Seventy-five trials and eleven systematic reviews a day: how will we ever keep up? *PLoS Med.* 2010; 7(9): e1000326.
2. Canadian Institutes of Health Research (CIHR): Knowledge Translation – Definition. Available at: <http://www.cihr-irsc.gc.ca/e/29418.html> (Accessed Dec 14th, 2012)
3. Straus SE, Tetro J, Graham I. Defining knowledge translation. *CMAJ.* 2009; 181: 165-8.
4. Kohn LT, Corrigan JM, Donaldson ML. *To err is human.* Washington, DC: National Academy Press, 2000.
5. Institute of Medicine, *Shaping the Future for Health: Crossing the quality chasm: a new health system for the 21st century.* 2001. Available at: <http://www.iom.edu/Object.File/Master/27/184/Chasm-8pager.pdf>. (Accessed Feb 2, 2013)
6. Grol R. Successes and failures in the implementation of evidence-based guidelines for clinical practice. *Med Care.* 2001; 39: 1146-54.
7. McGlynn EA, Asch SM, Adams J, Keesey J, Hicks J, DeCristofaro A, Kerr EA. The quality of health care delivered to adults in the United States. *N Engl J Med.* 2003; 348: 2635-45.
8. Schuster MA, Elizabeth A, McGlynn R, Brook H. How good is the quality of health care in the United States? *Milbank Q.* 1998; 76: 517-63.
9. Koes B, van Tulder M, Lin C-W, Macedo L, McAuley J, Maher C. An updated overview of clinical guidelines for the management of non-specific low back pain in primary care. *Eur Spine J.* 2010; 19: 2075-94.
10. Pincus T, Foster NE, Vogel S, Santos R, Breen A, Underwood M. Attitudes to back pain amongst musculoskeletal practitioners: a comparison of professional groups and practice settings using the ABSmp. *Man Ther.* 2007; 12: 167-75.
11. Poitras S, Blais R, Swaine B, Rossignol M. Practice patterns of physiotherapists in the treatment of work-related back pain. *J Eval Clin Pract.* 2007; 13: 412-21.
12. Sherman KJ, Cherkin DC, Deyo RA, Erro JH, Hrbek A, Davis RB, Eisenberg DM. The diagnosis and treatment of chronic back pain by acupuncturists, chiropractors, and massage therapists. *Clin J Pain.* 2006; 22: 227-34.
13. van de Veen EA, de Vet HC, Pool JJ, Schuller W, de Zoete A, Bouter LM. Variance in manual treatment of nonspecific low back pain between orthomanual physicians, manual therapists, and chiropractors. *J Manipulative Physiol Ther.* 2005; 28: 108-16.
14. Graham I, Logan J, Harrison M, Straus S, Tetroe J, Caswell W. Lost in knowledge translation: time for a map? *J Contin Educ Health Prof.* 2006; 26: 13-24.
15. Straus S, Tetroe J, Graham I. *Knowledge translation in health care. Moving from evidence to practice.* Wiley-Blackwell BMJ Books. 2009.

16. Hinton PM, McLeod R, Broker B, MacLellan CE. Outcome measures and their everyday use in chiropractic practice. *J Can Chiropr Assoc.* 2010; 54: 118-31.
17. Ax en I, Rosenbaum A, R obech R, Wren T, Leboeuf-Yde C. Can patient reactions to the first chiropractic treatment predict early favorable treatment outcome in persistent low back pain? *J Manipulative Physiol Ther.* 2002; 25: 450-4.
18. Ax en I, Rosenbaum A, R obech R, Larsen K, Leboeuf-Yde C. The Nordic back pain subpopulation program: can patient reactions to the first chiropractic treatment predict early favorable treatment outcome in nonpersistent low back pain? *J Manipulative Physiol Ther.* 2005; 28: 153-8.
19. Ax en I, Jones JJ, Rosenbaum A, L ovgren PW, Halasz L, Larsen K, Leboeuf-Yde C. The Nordic back pain subpopulation program: validation and improvement of a predictive model for treatment outcome in patients with low back pain receiving chiropractic treatment. *J Manipulative Physiol Ther.* 2005; 28: 381-5.
20. Kongsted A, Leboeuf-Yde C. The Nordic back pain subpopulation program: course patterns established through weekly follow-ups in patients treated for low back pain. *Chiropr Osteopat.* 2010; 18:2. doi: 10.1186/1746-1340-18-2.
21. Malmqvist S, Leboeuf-Yde C, Ahola T, Andersson O, Ekstr om K, Pekkarinen H, Turpeinen M, Wedderkopp N. The Nordic back pain subpopulation program: predicting outcome among chiropractic patients in Finland. *Chiropr Osteopat.* 2008; 16:13. doi: 10.1186/1746-1340-16-13.
22. Stig LC, Nilsson  , Leboeuf-Yde C. Recovery pattern of patients treated with chiropractic spinal manipulative therapy for long-lasting or recurrent low back pain. *J Manipulative Physiol Ther.* 2001; 24: 288-91.
23. Leboeuf-Yde C, Gr onstvedt A, Borge JA, Lothe J, Magnesen E, Nilsson  , R osok G, Stig LC, Larsen K. The Nordic back pain subpopulation program: demographic and clinical predictors for outcome in patients receiving chiropractic treatment for persistent low back pain. *J Manipulative Physiol Ther.* 2004; 27: 493-502.
24. Leboeuf-Yde C, Gr onstvedt A, Borge JA, Lothe J, Magnesen E, Nilsson  , R osok G, Stig LC, Larsen K. The Nordic back pain subpopulation program: a 1-year prospective multicenter study of outcomes of persistent low-back pain in chiropractic patients. *J Manipulative Physiol Ther.* 2005; 28: 90-6.
25. Leboeuf-Yde C, Ax en I, Jones JJ, Rosenbaum A, L ovgren PW, Halasz L, Larsen K. The Nordic back pain subpopulation program: the long-term outcome pattern in patients with low back pain treated by chiropractors in Sweden. *J Manipulative Physiol Ther.* 2005; 28: 472-8.
26. Kopansky-Giles D, Papadopoulos C. Canadian chiropractic resources databank (CCRD): a profile of Canadian chiropractors. *J Can Chiropr Assoc.* 1997; 41: 155-91.
27. Cabana M, Rand C, Powe N, Wu A, Wilson M, Abboud P, Rubin H: Why don't physicians follow clinical practice guidelines? A framework for improvement. *JAMA* 1999; 282:1458-65.
28. Cabana MD, Rushton JL, Rush AJ. Implementing practice guidelines for depression: applying a new framework to an old problem. *Gen Hosp Psychiatry.* 2002; 24: 35-42.
29. Stuber K, Bussi eres A, Gotlib A. Chiropractic research capacity in Canada in 2008. *J Can Chiropr Assoc.* 2009; 53: 78-86.
30. Ley TJ, Rosenberg LE. The physician-scientist career pipeline in 2005. Build it, and they will come. *JAMA.* 2005; 294(11): 1343-51.
31. Biggs L, Mierau D, Hay D. Measuring philosophy: a philosophy index. *J Can Chiropr Assoc.* 2002; 46: 173-84.
32. Villanueva-Russell Y. Evidence-based medicine and its implications for the profession of chiropractic. *Soc Sci Med.* 2005; 60: 545-61.
33. A comprehensive inventory of practical information about Canada's licensed chiropractors. Canadian Chiropractic Resources Databank (CCRD) National Report, The Canadian Chiropractic Association. 2011.
34. Verstappen WH, ter Riet G, Dubois WI, Winkens R, Grol RP, van der Weijden T. Variation in test ordering behaviour of GPs: professional or context-related factors? *Fam Pract.* 2004; 21: 387-395.
35. Haldeman S, Chapman-Smith D, Petersen DM. Guidelines for chiropractic quality assurance and practice parameters: proceedings of the Mercy Center Consensus Conference. Jones & Bartlett Pub. 1993: 222 Pages
36. Cates JR, Young DN, Guerriero DJ, Jahn WT, Armine JP, Korbett AB, Bowerman DS, Porter RC, Sandman T, King RA. An independent assessment of chiropractic practice guidelines. *J Manipulative Physiol Ther.* 2003; 26: 282-6.
37. World Federation of Chiropractic. Identity consultation: report and recommendations. WFC Assembly. Sydney, Australia. 2005.

# Transient osteoporosis of the hip: A case report

Katherine Van Wagenen, BS<sup>1</sup>

Paul Pritchard, DC<sup>2</sup>

John A. Taylor, DC, DACBR<sup>3</sup>

*We report a case of transient osteoporosis of the hip (TOH) in a 59-year-old man including the clinical presentation, diagnostic studies, management and clinical progress. TOH is a rare self-limiting condition that typically affects middle-aged men or, less frequently, women in the third trimester of pregnancy. Affected individuals present clinically with acute hip pain, limping gait, and limited ranges of hip motion. TOH may begin spontaneously or after a minor trauma. Radiographs are typically unremarkable but MR imaging studies yield findings consistent with bone marrow edema. TOH is referred to as regional migratory osteoporosis if it travels to other joints or the contralateral hip. TOH often resembles osteonecrosis but the two conditions must be differentiated due to different prognoses and management approaches. The term TOH is often used interchangeably and synonymously with transient bone marrow edema.*

*Nous rapportons le cas d'une ostéoporose transitoire de la hanche (OTH) d'un homme de 59 ans avec une présentation clinique, des études diagnostiques, la gestion et les progrès cliniques. L'OTH est une maladie à résolution spontanée rare qui atteint généralement les hommes d'un certain âge ou, moins fréquemment, les femmes lors du troisième trimestre de la grossesse. Les personnes touchées présentent des douleurs aiguës de la hanche, marchent en boitant, et ont une amplitude des mouvements de la hanche limités. L'OTH peut se déclencher spontanément ou après un traumatisme mineur. Les radiographies sont généralement ordinaires mais les études menées sur l'IRM fournissent des résultats compatibles avec un œdème de la moelle osseuse. L'OTH est qualifié d'ostéoporose migratoire régionale si elle se déplace vers d'autres articulations ou vers la hanche controlatérale. L'OTH ressemble à l'ostéonécrose mais les deux conditions doivent être différenciées en raison de pronostics et d'approches de gestion différentes. Le terme OTH est souvent synonyme d'œdème de la moelle osseuse transitoire, et ces deux termes sont souvent employés de manière interchangeable.*

KEY WORDS: osteoporosis, hip, transient

MOTS CLÉS : ostéoporose, hanche, transitoire

<sup>1</sup> Intern, Chiropractic Program, D'Youville College, Buffalo, NY

<sup>2</sup> Private Practice, Thompson, MB

<sup>3</sup> Professor, Chiropractic Department, D'Youville College, Buffalo, NY

Corresponding Author: Katherine Van Wagenen, Chiropractic Department, D'Youville College, 320 Porter Avenue, Buffalo, NY 14201  
vanwak30@dyc.edu  
(518) 542-9371

Disclaimers: No disclaimers or conflicts of interest.

Sources of Support: No sources of financial support.

Acknowledgement: The authors thank Chris Herrington for assistance with the reproductions

©JCCA 2013



## Introduction

Transient osteoporosis of the hip (TOH) is a rare self-limiting condition that typically affects middle-aged men or, less commonly, women in the third trimester of pregnancy. These individuals present without a history of major trauma but usually developed an acute onset of hip pain accompanied by decreased ranges of motion, and a limping gait.<sup>1-6</sup> Radiographs of TOH are frequently unremarkable, but may display diffuse osteopenia of the femoral head and neck. The affected area appears “warm” on bone scans; however, this test is seldom used due to its low specificity for TOH.<sup>1</sup> Computed tomography findings include reduced bone density of the affected area and loss of thickness with continuity of vertical primary compressive trabeculae.<sup>2</sup> Magnetic resonance (MR) imaging yields findings consistent with bone marrow edema – low signal intensity of bone marrow on T1-weighted sequences and high signal intensity of bone marrow on fluid-sensitive (T2-weighted and fat-suppressed) sequences.<sup>3</sup> The edema affects the subchondral bone of the femoral head and can extend toward the neck and intertrochanteric region. Unlike osteonecrosis, TOH does not result in collapse, fragmentation, or remodeling of the cortical bone of the femoral head nor does it progress to arthritis.<sup>1</sup>

Cases of TOH have been reported with and without the co-existent presence of subchondral stress fractures of the femoral head.<sup>1,4</sup> The susceptibility to stress fractures may be partly due to diminished bone density secondary to increased osteoclastic activity.<sup>3</sup> There has been debate within the literature whether TOH is a consequence of a stress fracture or vice versa, since not every patient with TOH also has subchondral stress fractures.<sup>3,4</sup>

Although the specific risk factors for TOH are poorly understood, it is generally agreed that they differ from the risk factors associated with osteonecrosis.<sup>1,3-7</sup> For example, it is postulated that there may be a relationship between TOH and reflex sympathetic dystrophy, also known as complex regional pain syndrome (CRPS).<sup>3,5,6</sup> The two conditions share similar signs and symptoms of pain, edema, and inflammatory soft tissue changes, however, the hypersensitivity, vasomotor dysfunction, temperature and skin changes typically observed in CRPS are not characteristic of transient osteoporosis.<sup>3,5</sup> A small retrospective study<sup>6</sup> (n=17) reported that physicians had a higher incidence of TOH compared to osteonecrosis or

transient bone marrow edema syndrome and postulated that this may be due to long hours of standing.

TOH may eventually migrate to other joints, especially the contralateral hip, a condition referred to as regional migratory osteoporosis (RMO).<sup>5</sup> The signs and symptoms of RMO are identical to TOH and both eventually resolve without treatment, suggesting that these are variations of the same or a similar condition.<sup>8</sup>

TOH is also similar to a condition termed transient bone marrow edema (TBME) syndrome. Within the literature, authors may either use the terms interchangeably<sup>3</sup> or choose to differentiate the two conditions. According to some authors<sup>5,7</sup>, TBME syndrome should be reserved for cases where radiographs do not show osteopenic changes of the femoral head and neck, whereas the term TOH is typically reserved for cases where radiographs do demonstrate osteopenia. Aside from this minor distinction the clinical presentation and MR findings of TBME syndrome and TOH are equivalent.<sup>5</sup>

## Case History

A 59-year-old male presented to a chiropractic clinic with a chief complaint of acute left hip pain after building a dock. The pain began two to three days after the building project during which he repeatedly carried 16-foot long, two inch by six inch planks of lumber on his left hip down a steep incline to the beach. The pain was a constant ache with sharp, stabbing pain when moving from sitting to standing and after prolonged walking, sitting or lying supine. Following prolonged standing or walking, the severity of the patient’s pain prevented him from lying in a neutral left hip, knee extended posture. In order to avoid pain he would assume a supine lying position of 45° hip and knee flexion. At night he would frequently wake up to “walk off the pain”.

## Physical Examination

Upon examination, the patient had difficulty arising from sitting and ambulated with an antalgic gait and limp favoring his left hip. His left groin and hip region were tender to palpation and demonstrated painful limitation of passive ranges of internal rotation, external rotation, flexion, and extension. Log roll, FABER Patrick, and FADIR (hip impingement) tests were all exquisitely painful with soft end feel restriction associated with muscular guarding rather than with a hard end feel restriction suggestive

Table 1  
Relevant Orthopedic Examinations<sup>14</sup>

Orthopedic Exam	Description	Interpretation
Log Roll	Patient is supine, the examiner places both hands on the patient's mid-thigh and passively externally rotates each hip maximally.	Test is positive for intra-articular pathology if greater external rotation is noted on the affected side.
FABER Patrick	Patient is supine, the examiner flexes, abducts, and externally rotates the affected hip so that the ipsilateral ankle is placed just proximal to the unaffected knee. While stabilizing the anterior superior iliac spine, the affected leg is lowered toward the table.	Test is positive for intra-articular hip pain if the maneuver reproduces the patient's symptoms.
FADIR Hip Impingement	Patient is supine, the examiner flexes the hip and knee to 90°, then adducts and internally rotates the affected hip in the flexed position.	Test is positive for intra-articular hip pathology if the patient's symptoms are reproduced.
Ober's test	Patient is side-lying with the affected side up, the examiner flexes the patient's knee to 90° and abducts and extends the hip. The examiner allows gravity to adduct the hip as much as possible.	Test is positive if the hip is unable to adduct to the neutral position. Positive test is indicative of iliotibial band pathology.
Trendelenberg	Patient is standing and lifts one foot off the ground.	Test is positive if the non-stance hip drops. Positive test is indicative of gluteus medius weakness on the stance side.

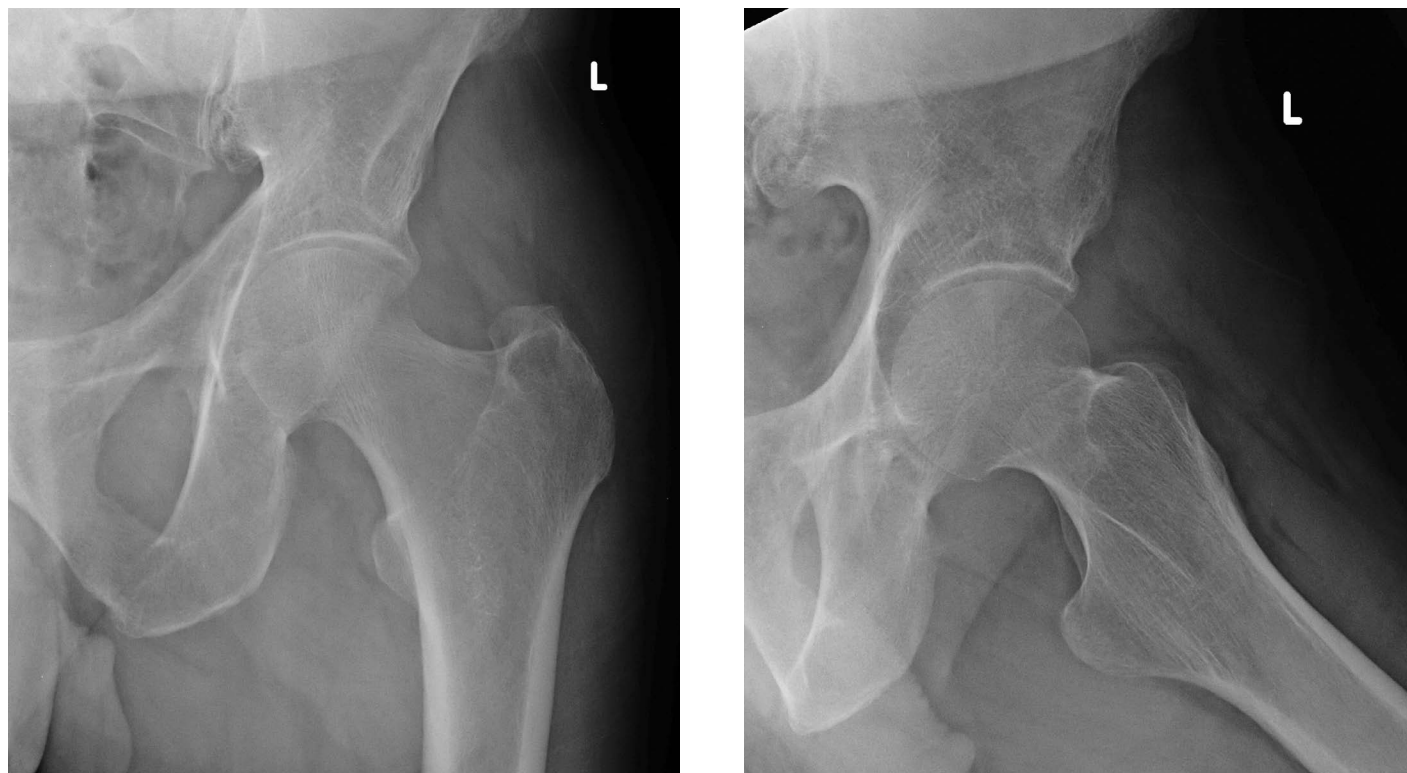


Figure 1. Anteroposterior (A) and frog-leg lateral (B) radiographs reveal normal bone density, trabeculae and only minor hip joint space narrowing.

of joint pathology. Ober test and Trendelenberg tests were negative (refer to Table 1 for a summary of the relevant orthopedic examinations). Conventional AP (Figure 1A) and frog-leg lateral (Figure 1B) radiographs of the left hip were interpreted as normal.

### Initial Diagnosis and Management

The initial clinical impression was of an acute capsular lesion of the hip. The patient's primary care clinician prescribed analgesic and non-steroidal anti-inflammatory medication for six weeks which provided only minimal relief. A brief three visit course of conservative physical therapy triggered acute exacerbations of pain lasting 48 to 72 hours following each therapy session and was therefore discontinued. Despite the patient's optimistic expectation of a gradual self-resolution of the complaint, at six weeks post-injury his pain and disability appeared to be increasing. As a result, the patient was referred for MR imaging with intra-articular gadolinium (MR arthrogram) to assess the hip joint and intra-articular structures.

### MR Imaging and Final Diagnosis

MR imaging was ordered to rule out internal derangement or osseous pathology (i.e. labral tear, osteoarthritis or osteonecrosis respectively). The MR images revealed extensive edema within the medullary bone of the head and neck of the left femur with an associated joint effusion. No findings suggestive of avascular necrosis, labral tear or intra-articular lesion were identified. Further T1-weighted MR images were obtained after intravenous injection of gadolinium, revealing minor signal enhancement of the femoral head. The radiologist's report concluded that these findings were most consistent with transient osteoporosis of the hip (Figure 2A).

The cornerstone of management involved education of the patient to the benign, self-limiting nature of the condition. This included a cautionary warning regarding the heightened risk for fracture of the femoral neck secondary to transient osteoporosis and the risk of migration of the condition to the contralateral hip. Pain reduction strategies included utilization of analgesics on an as-needed

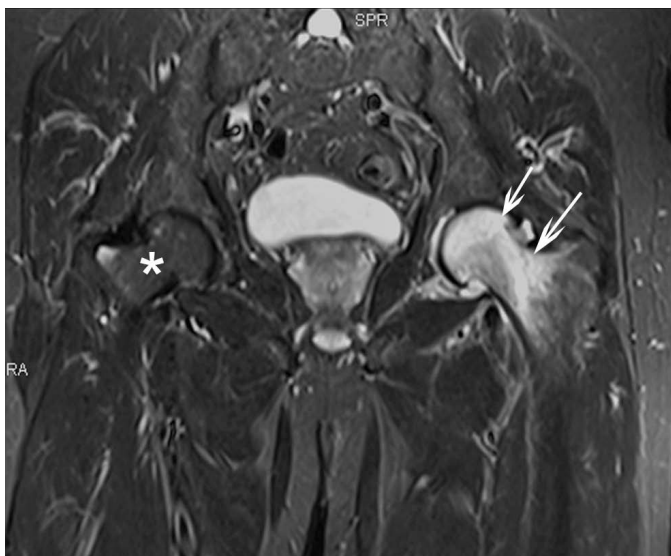
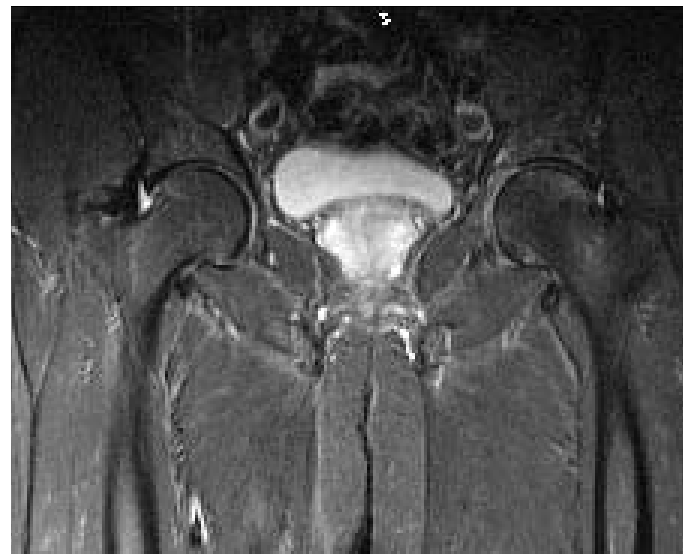

Figure 2.

A) Initial coronal fluid-sensitive (STIR) MR image obtained 3 months after initial onset of pain reveals hyperintense bone marrow signal within the left femoral head and neck (arrows) consistent with the bone marrow edema associated with transient osteoporosis. A joint effusion is also present. The right femoral head and neck exhibit normal bone marrow signal. (\*)



B) Follow up coronal fluid-sensitive (STIR) MR image obtained 3 months after the initial MR study reveals complete resolution of the abnormal bone marrow signal within the left femoral head and neck as well as resolution of the initial joint effusion. The right femoral head and neck exhibit normal bone marrow signal.

basis and the adoption of hip sparing postures and activities to decrease loading.

The radiologist requested follow-up MR imaging to confirm that the edema had resolved satisfactorily, to exclude the presence of subchondral stress fracture, and to ensure that the contralateral femoral head and neck remained normal. MR imaging obtained four months post-diagnosis demonstrated complete resolution of the findings of bone marrow edema and joint effusion. There was no evidence of contralateral hip involvement or complications such as fracture (Figure 2B). The patient reported a full resolution of his symptoms at the follow-up appointment just prior to his second MRI. Regular and moderate manual labor provoked no symptomatic flair or recurrence.

## Discussion

TOH is a self-limiting condition which develops spontaneously or may be triggered by minor trauma and is characterized clinically by acute hip pain, limping gait, and limited range of motion.<sup>1,3</sup> It is three times as likely to affect males<sup>5</sup> who are typically between the ages of 32 and 55<sup>1</sup>. A subset less frequently affected by TOH are women in the third trimester of pregnancy.<sup>1,2,5</sup> Most cases of TOH are spontaneous<sup>3,5</sup> while others occur following minor trauma<sup>1,6</sup> such as a “groin pull” or a slip. It is thought that minor trauma may cause a transient ischemic period which triggers an episode of TOH.<sup>6</sup> In the current case it can be postulated that the repetitive compressive loading of the left hip may have been sufficient trauma to result in transient ischemia which progressed to TOH.

Conventional radiographic studies are generally insensitive to TOH and contribute little value to the diagnosis.<sup>1,3</sup> The radiographs in the current case were unremarkable, exhibiting no degenerative (osteoarthritic) changes of either hip, despite the patient’s age of 59 years. Some cases of TOH report diffuse osteopenia of the femoral head and neck, however, this finding may not be detected radiographically until up to eight weeks post-injury.<sup>1-5</sup> Our patient underwent radiographic examination within four weeks of the onset of acute hip pain, perhaps explaining the absence of osteopenia on his images.

MR imaging findings of bone marrow edema are the diagnostic hallmark of TOH – low signal intensity of bone marrow on T1-weighted images and high signal on STIR and fat saturated T2-weighted, fluid sensitive sequences.<sup>3</sup>

Hip joint effusion (seen in this study) is a consistent finding in many cases of TOH.<sup>1,3,5</sup> Although not present in the current case, another finding frequently associated with TOH is a subchondral stress fracture.<sup>3,4</sup> The absence of subchondral stress fractures in some cases may suggest that TOH is a cause rather than a consequence of such fractures.

TOH often presents clinically in a pattern similar to early stage osteonecrosis.<sup>1,3,7</sup> Osteonecrosis is an irreversible condition that can be categorized as primary or secondary.<sup>3</sup> Secondary osteonecrosis is caused by an ischemic lesion and is associated with trauma, alcoholism, corticosteroid use, and hematological disorders. Primary (or spontaneous) osteonecrosis is idiopathic and therefore not associated with the aforementioned risk factors.<sup>3</sup> Early osteonecrosis of the femoral head will display the radiographic signs of subchondral sclerosis of the rim of the femoral head which is known as the crescent or half-moon sign.<sup>3,9</sup> MR imaging of early osteonecrosis typically reveals a low signal intensity serpentine band surrounding a normal appearing epiphyseal area on T1 weighted images; while advanced cases reveal epiphyseal collapse, subchondral fractures, and subchondral cysts.<sup>9</sup>

TOH spontaneously resolves within a four to nine month period with conservative treatment which focuses on hip sparing activities and postures which decrease loading on the hip joint.<sup>4</sup> Surgical decompression is occasionally performed to shorten the healing period but is unnecessary.<sup>3</sup> Ringe et al<sup>10</sup> found that administering an intravenous dose (four mg initial dose with an optional second two mg dose at three months) of ibandronate, a potent nitrogen-containing bisphosphonate, decreased visual analogue pain scales by an average of 94.3% with a decrease of at least 75% in all patients (N=12). Furthermore, the bone mineral density between the affected and unaffected femoral neck regions (N=7) decreased from 10.1 to 2.6% at the six month follow-up. TOH does not result in osteoarthritic changes to the bone or joint<sup>1</sup> and does not progress to osteonecrosis<sup>3</sup>. It is therefore imperative that TOH be differentiated from osteonecrosis in the early stages as the prognosis and treatment of these two conditions differs substantially (refer to Table 2 for differential diagnoses).<sup>1</sup>

The most common treatment options for osteonecrosis are rotational osteotomy, core decompression, and free vascularized fibular grafting.<sup>11</sup> Outcomes are af-

Table 2  
*Differential Diagnosis of Adult Hip Disorders*<sup>3,10,11,15</sup>

	<b>Transient Osteoporosis</b>	<b>Osteonecrosis</b>	<b>Stress Fracture</b>
Signs, Symptoms, and Physical Exam	Acute onset of hip pain Limping gait Decreased ROM	Acute onset of hip pain Limping gait Decreased ROM	Acute onset of hip pain Limping gait Decreased ROM
Etiology	Unknown Possible association with CRPS	Ischemic trauma Risk factors: fracture, steroid use, alcohol, etc	Mechanical trauma Fatigue (healthy bone) Risk factors: overuse, repetitive running Stress (weak bone) Risk factors: osteoporosis
Imaging Findings	Bone edema Joint effusion ± Stress fracture	Bone edema Subchondral collapse Subchondral cysts ± Subchondral fracture Osteoarthritic changes XR: crescent sign MR: low intensity serpentine band surrounding normal tissue on T1	Bone edema XR: fracture line MR: low intensity line on T1
Progression	Spontaneous resolution Possible migration	Irreversible	Reversible Possible progression to osteonecrosis
Treatment	No weight bearing activities Nonsteroidal anti-inflammatory drugs (NSAIDs) Analgesics Corticosteroids Possible ibandronate	Surgery	No weight bearing activities Possible surgery

ected by the patient's age, etiology, stage of osteonecrosis, size, and location of the necrotic lesion. Conservative treatment (e.g. partial weight bearing) of early stage osteonecrosis has been proven ineffective in 80 to 90% of patients.<sup>11</sup> Osteotomies attempt to realign the femoral articulating surface to reduce the weight-bearing zone of the necrotic area. Hasegawa et al<sup>12</sup> reported five and ten year transtrochanteric rotational osteotomy survival rates without failure as 71% and 61%, respectively. Core decompression is an alternative treatment option that is one of the least invasive surgical procedures to manage osteonecrosis. Malizos et al<sup>11</sup> reported further surgical intervention was necessary in 16%, 37%, and 71% after core decompression of osteonecrosis stages I, II, and III, respectively. Decompression procedures have higher success rates with segmental lesions prior to articular collapse. Free vascularized fibular grafting is a procedure

that has a survival of 61%–96% at mid-term (4–7 years) follow-up.<sup>13</sup> Yoo et al<sup>13</sup> followed 110 patients (124 hips) who underwent vascularized fibular grafting for a minimum of 10 years. The average Harris hip score improved from 72 to 88 while 13 patients (13 hips) failed treatment and had to undergo total hip arthroplasty. The ultimate purpose of osteotomies, decompression procedures, and grafts is to prevent or delay total hip arthroplasty.<sup>10</sup>

### Conclusion

TOH should be considered in the differential diagnosis of middle-aged males presenting with acute hip pain, limping gait, and limited ranges of hip motion. Early radiographic findings of TOH are usually unremarkable, but may show diffuse osteopenia of the femoral head and neck beyond six to eight weeks post-onset of pain. Symptom progression following treatment may require advanced

imaging to differentiate TOH from other conditions such as osteonecrosis. TOH differs from osteonecrosis in its risk factors; its absence of radiographic findings of subchondral or focal lesions; and its self-limiting resolution with conservative management.

## References

1. Balakrishnan A, Schemitsch EH, Pearce D, McKee MD. Distinguishing transient osteoporosis of the hip from avascular necrosis. *Can J Surg*. 2003;46(3):187-192.
2. Kim YL, Nam KW, Yoo JJ, Hong SH, Kim HJ. CT evidence for subchondral trabecular injury of the femoral head in transient osteoporosis of the hip: a case report. *J Korean Med Sci*. 2010; 25:192-5.
3. Fernandez-Canton G. From bone marrow edema to osteonecrosis. *New Concepts. Reumatol Clin*. 2009;5(5):223-7.
4. Ergun T, Lakadamyali H. The relationship between MRI findings and duration of symptoms in transient osteoporosis of the hip. *Acta Orthop Traumatol Turc*. 2008;42(1):10-5.
5. Hayes CW, Conway WF, Daniel WW. MR imaging of bone marrow edema pattern: transient osteoporosis, transient bone marrow edema syndrome, or osteonecrosis. *Radiographics*. 1993;13:1001-11.
6. Hadidy AM, Al Ryalat NT, Hadidi ST, Tarawneh ES, Hadidi MT, Samara OA, Abu-Labn DM, Al-Rousan LM, Hiyasat DA, Hamamy HA. Male transient hip osteoporosis: are physicians at a higher risk? *Arch Osteoporos*. 2009;4:41-45.
7. Kim YM, Oh HC, Kim HJ. The pattern of bone marrow oedema on MRI in osteonecrosis of the femoral head. *J Bone Joint Surg (Br)*. 2000;82-B:837-41.
8. Swoopes F, Mazzini N, Centonze M, Fancellu G. It is true that regional migratory osteoporosis has a full remission? A follow-up after 14 years: a case report. *Euro J Phys Rehabil Med*. 2011;47:1-2.
9. Vande Berg BE, Malghem JJ, Labaisse MA, Noel HM, Maldague BE. MR imaging of avascular necrosis and transient marrow edema of the femoral head. *Radiographics*. 1993;13:501-20.
10. Ringe JD, Dorst A, Faber H. Effective and rapid treatment of painful localized transient osteoporosis (bone marrow edema) with intravenous ibandronate. *Osteoporos Int*. 2005;16:2063-8.
11. Malizos KN, Karantanas AH, Varitimidis SE, Dailiana ZH, Bargiotas K, Maris T. Osteonecrosis of the femoral head: Etiology, imaging, and treatment. *Eur J Radiol*. 2007;63:16-28.
12. Hasegawa Y, Sakano S, Iwase T, Iwasada S, Torii S, Iwata H. Pedicle bone grafting versus transtrochanteric rotational osteotomy for avascular necrosis of the femoral head. *J Bone Joint Surg [Br]*. 2003;85-B:191-8.
13. Yoo MC, Kim K, Hahn CS, Parvizi J. Long-term followup of vascularized fibular grafting for femoral head necrosis. *Clin Orthop Relat Res*. 2008;466(5):1133-1140.
14. Cleland JA, Koppenhaver S. *Netter's Orthopaedic Clinical Examination: An Evidence-Based Approach*. 2<sup>nd</sup> ed. Philadelphia: Saunders, 2011: 267-75.
15. Souza TA. *Differential Diagnosis and Management for the Chiropractor: Protocols and Algorithms*. 4<sup>th</sup> ed. Sudbury, Massachusetts: Jones and Bartlett Publishers, 2009:353-56.

# Insufficiency fracture of the tibial plateau after anterior cruciate ligament reconstructive surgery: a case report and review of the literature

Jessica J. Wong<sup>1</sup>, BSc, DC, FCCS(C)  
Brad Muir<sup>2</sup>, HBSc (Kin), DC, FRCCSS(C)

*Peri-articular fractures after anterior cruciate ligament (ACL) reconstructive surgery are rare. To our knowledge, this case documents the first insufficiency fracture of the tibial plateau after ACL reconstruction, which presented three weeks after the procedure. A 25-year-old female recreational soccer player suffered an insufficiency fracture of the tibial plateau, extending 1.5 mm into the anterior wall of tibial tunnel and medial compartment under the anterior horn of medial meniscus, which presented as a diagnostic challenge. Clinically, the fracture mimicked a low-grade infection of the surgical site, while radiographically, the fracture resembled an avulsion fracture, later confirmed as a tibial tunnel fracture with computed tomography. With the ACL graft integrity not in jeopardy, four weeks of non-weightbearing and a delayed post-operative rehabilitation program was effective in allowing the fracture to heal. Good functional outcome was achieved after conservative management, with minimal loss of terminal knee extension and minimal pain at 22-month follow-up.*

**KEY WORDS:** tibial plateau, fracture, ACL reconstruction, complication, conservative management

*Les fractures péri-articulaires après une chirurgie reconstructive du ligament croisé antérieur (LCA) sont rares. À notre connaissance, ce cas représente la première fracture par insuffisance du plateau tibial après une chirurgie reconstructive du LCA, qui s'est présentée trois semaines après la procédure. Une joueuse amateur de soccer de 25 ans a subi une fracture par insuffisance du plateau tibial, se prolongeant 1,5 mm dans la paroi antérieure du tunnel tibial et dans le compartiment médian sous la corne antérieure du ménisque interne, ce qui présentait une difficulté de diagnostic. Du point de vue clinique, la fracture ressemblait à une infection légère du foyer opératoire, alors que d'un point de vue radiographique, cela ressemblait plus à une fracture par avulsion. Plus tard, la tomographie par ordinateur a confirmé une fracture du tunnel tibial. L'intégrité de la greffe n'étant pas en danger, quatre semaines sans porter aucune charge et un programme différé de réhabilitation postopératoire ont permis la guérison de la fracture. De bons résultats fonctionnels ont été atteints après la gestion conservatrice, avec une perte minimale de l'extension du genou terminal, et une douleur minimale après 22 mois de suivi.*

**MOTS CLÉS :** plateau tibial, chirurgie reconstructive du LCA, complication, gestion conservatrice

<sup>1</sup> Graduate Student, Clinical Sciences, Canadian Memorial Chiropractic College, Toronto, Ontario, Canada

<sup>2</sup> Assistant Professor, Division of Undergraduate Studies, Canadian Memorial Chiropractic College, Toronto, Ontario, Canada

Corresponding author: Jessica J. Wong, Graduate Student, Clinical Sciences, Canadian Memorial Chiropractic College, 6100 Leslie Street, Toronto, Ontario M2H 3J1. Phone: (416) 482-2340. Email: jes.wong@utoronto.ca.

Conflict of interest: none

Consent: Patient gave written consent to use file and images for the purpose of this case report.

Funding: none

Acknowledgements: The authors would like to thank Dr. Jayme Shaughnessy for her assistance with this case report.

©JCCA 2013

## Introduction

Injuries to the anterior cruciate ligament (ACL) are common in athletic populations, particularly in female athletes participating in soccer. The incidence of ACL injury ranges from 0.06-3.7 per 1000 hours of training and participation in soccer, and accounts for thousands of ACL tears annually.<sup>1,2</sup> Female soccer players have up to 6-times greater risk of an ACL tear than male counterparts.<sup>3</sup> In light of this, between 50,000 and 100,000 ACL reconstructive surgeries are performed annually in the United States<sup>4</sup>, while the rate of revision ACL reconstruction in Denmark is 4.1% after five years<sup>5</sup>. Post-surgical complications after ACL reconstruction vary widely and include stiffness, wound complications, infection, graft failure, deep venous thrombosis, pulmonary embolism, osteonecrosis and peri-articular fracture.<sup>6-8</sup> Peri-articular fractures involving the tibia plateau are rare, as only a few case reports describe this specific complication.<sup>9-19</sup>

Post-surgical complications related to ACL reconstruction have important clinical implications. In a retrospective hospital database review from 1997-2006, it was found that of 70,547 ACL reconstructive surgeries performed, 6.5% of cases had subsequent surgery on either knee within one year.<sup>5</sup> Predictors of subsequent knee surgery included female gender, concomitant knee surgery, and operation by lower-volume surgeons, while predictors of subsequent ACL reconstruction included age of less than 40 years, concomitant meniscectomy or other knee surgery, and surgery in lower-volume hospitals.<sup>5</sup> This suggests that while ACL reconstruction is a relatively safe procedure, there remains a noted risk of subsequent operation on either knee, which is increased by a number of predictors, including those who are younger and female. It is therefore important to conduct timely assessment of those presenting with knee complaints after ACL reconstruction surgery to facilitate appropriate management, in aims to minimize the need for subsequent operation.

To our best knowledge, this case report details the first published case of an insufficiency fracture of the tibial plateau presenting three weeks after ACL reconstructive surgery. It was a diagnostic challenge, as its clinical presentation mimicked that of an infection or septic arthritis, but appropriate and timely imaging and investigative procedures detected the fracture. The early detection may have also mitigated its severity and allowed for uncomplicated non-invasive management of the fracture. Discus-

sion will surround the incidence, pathogenesis, clinical presentation, imaging and management of this post-surgical complication.

## Case Report

A 25 year-old female recreational soccer player sustained a left knee injury while playing soccer. During the game, she received an impact from another player to the medial aspect of her knee as her foot was planted, taking a varus force to the left knee. There was no audible pop or click during this injury, though she was unable to weightbear immediately after and had to use crutches to ambulate. She also reported noticeable swelling at the left knee. The patient did not report any previous injuries to this knee and did not experience any numbness or tingling into the lower extremity. She was otherwise healthy with no known medical conditions. Past medical history was remarkable for a wrist fracture fifteen years ago and a fracture of the right lateral malleolus ten years ago. She was taking oral contraceptive pills and doxycycline for acne, was a social drinker and did not smoke.

The patient immediately followed RICE principles and went to a chiropractic clinic two days after the injury for an assessment. Based on history and physical examination findings, the initial diagnosis was a left lateral collateral ligament (LCL) sprain with a suspected lateral meniscal tear and the patient was referred to a family physician for an MRI. The subsequent MRI found a full thickness ACL tear and suspected partial LCL tear in the left knee and the patient was referred to an orthopedic surgeon for consultation. Prior to the surgical consultation, the patient was treated with tolerable rehabilitation exercises and laser therapy at the chiropractic clinic twice a week for four weeks in aims to minimize muscle atrophy.

At her surgical consultation four weeks later, the patient was able to ambulate with a cane, but experienced recurrent mild dull pain at the anteromedial knee and episodes of instability when the left knee was in extension. Physical examination by the orthopedic surgeon revealed no swelling or effusion within the knee and no tenderness along the joint line. Left knee range of motion was passively full, but mildly lacked terminal flexion with active motion and lacked 5 degrees of genu recurvatum when compared to the right knee. It was difficult to perform ligamentous testing due to patient apprehension, though varus and valgus stability appeared intact. There was a



grade 1 positive Lachman test and a grade 1 positive pivot shift test with soft end feel. Anterior drawer test, dial testing, examination of other ligaments and lower limb neurovascular examination were unremarkable. While clinical examination did not show prominent laxity, the patient's left knee ACL deficiency was deemed symptomatic and confirmed on MRI. Due to the patient's desire to return to sport and her good candidacy for ACL reconstruction using a hamstring autograft, surgery was agreed upon. After ACL reconstruction, the patient had an uncomplicated recovery, and was discharged home by the orthopedic surgeon with pain medication, rehabilitation protocol and a follow-up appointment in 3-5 weeks' time.

At three weeks post-surgery, the patient began experiencing tenderness at the surgical site, with redness, swelling, warmth and decreased knee range of motion due to pain. There was no preceding trauma, and the patient had not yet returned to sport. She was also closely adhering to her rehabilitation protocol of daily open chain range of motion and light strengthening exercises of the knee within pain tolerance. At the chiropractic clinic, knee radiographs were ordered, which found moderate joint effusion and soft tissue swelling at the medial joint space, and suggestion of cortical offset at the medial tibial epiphysis (Figures 1a and 1b).

Upon further review, these radiographs showed a small

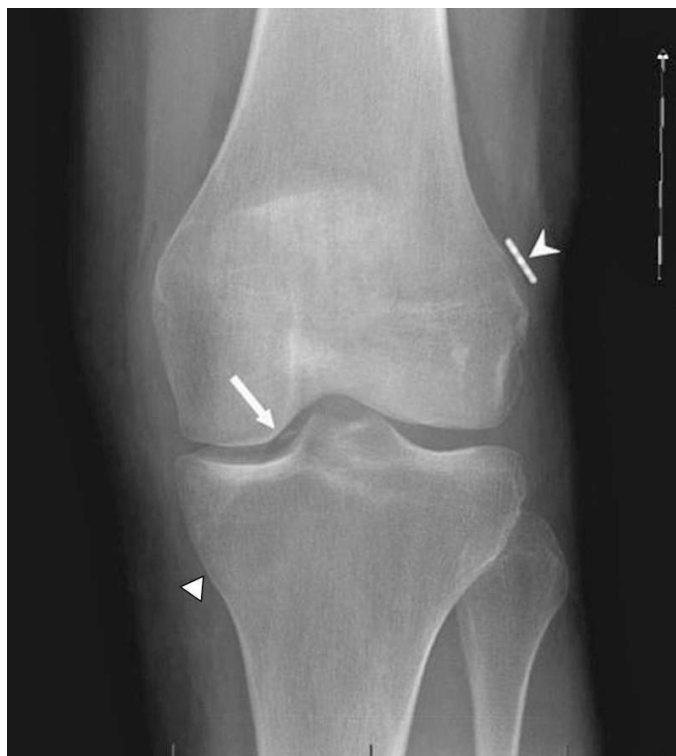

FIGURE 1a. AP Knee View

Significant soft tissue swelling is observed at the medial aspect of the left knee, near the pes anserine attachment. There is evidence of ACL reconstruction with a tibial tunnel (triangle) at the medial tibial plateau and a ligament anchor (Endobutton device) at the lateral femoral condyle (arrowhead). A cortical offset at the medial tibial epiphysis is suggested at the entrance of the tunnel (arrow).

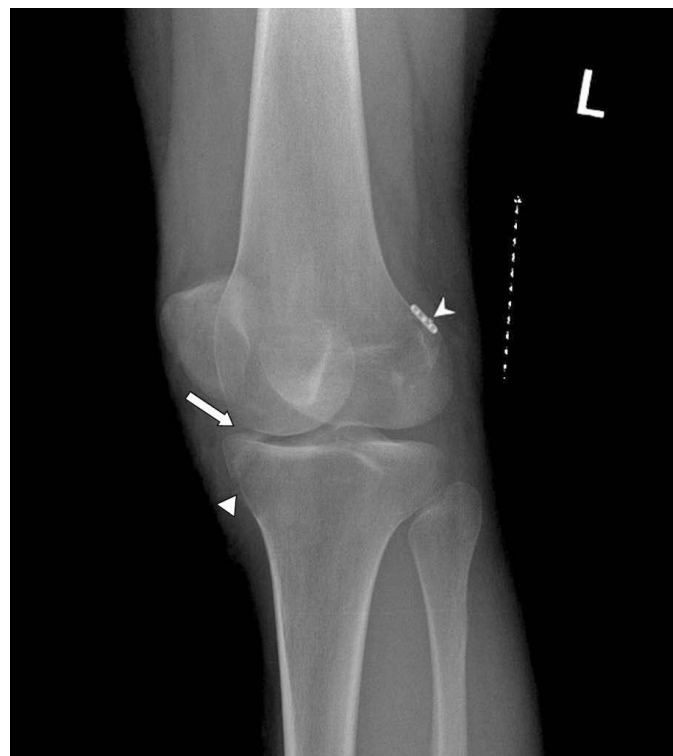


FIGURE 1b: Lateral Oblique Knee View

Moderate joint effusion is detected in the left knee with fullness of the suprapatellar recess and blurring of the posterior portion of the Hoffa's fat pad. A cortical defect at the proximal tibia (arrow), the tibial tunnel (triangle), and a ligament anchor (Endobutton device) at the lateral femoral condyle are noted (arrowhead).

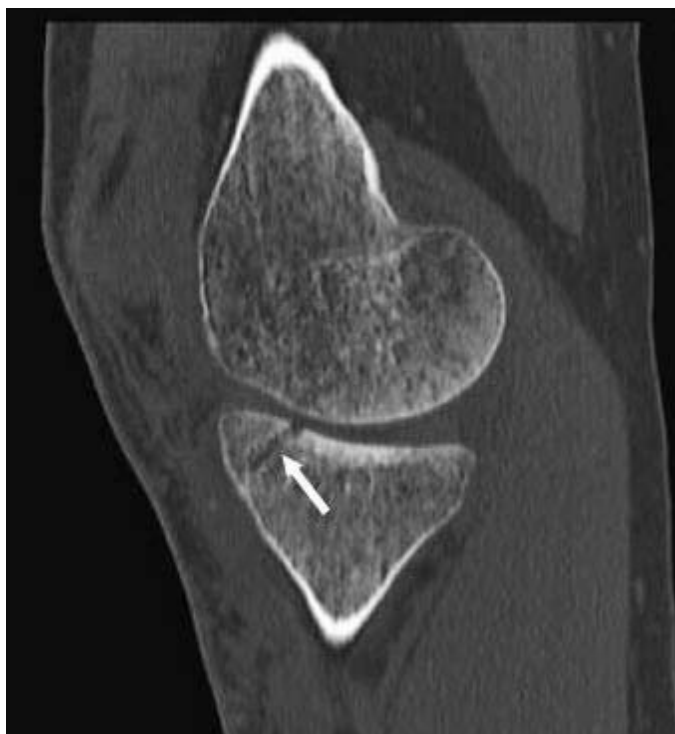triangular shaped fracture fragment well margined posteriorly and laterally by an oblique lucent line traversing the anteromedial aspect of the tibial plateau. This resulted in the cortical offset noted at the articular surface of the medial tibial plateau. The oblique lucent line is just superomedial to the tibial tunnel created by the orthopaedic surgeon to fix the reconstructed ACL.

Due to the amount of soft tissue swelling and joint effusion noted in radiographs, possible low-grade infection or septic arthritis could not be ruled out at the time, so she was sent to the emergency department for blood tests, which were unremarkable. A follow-up appointment with the orthopaedic surgeon was advised.

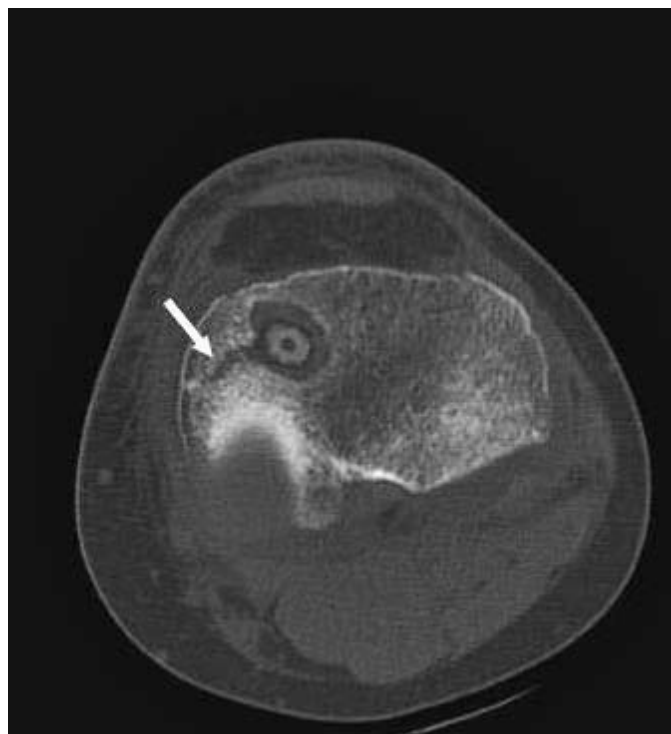
At her follow-up appointment with the orthopaedic surgeon five weeks post-surgery, the patient continued to report pain and persistent warmth around the surgical

site. On examination, the patient walked with slightly flexed knee gait, though passively she could extend her knee fully and flex to within 10 degrees of the other side. While she had a moderate-sized effusion at the left knee, her wounds were well healed and she was afebrile. Her quadriceps femoris were contracting but moderately inhibited, and there was noted tenderness proximal to the tibial wound. Lachman test and pivot shift of her left knee were negative.

Computed tomography (CT) of her left knee revealed a 1.5 mm cortical defect into the anterior portion of the medial compartment, underneath the anterior horn of the medial meniscus, with mild joint effusion present (Figures 2a and 2b). The CT images, read by a medical radiologist, confirmed the presence of a subacute, undisplaced intra-articular fracture involving the anteromedial corner



**FIGURE 2a:** CT Knee – Sagittal Slice  
*A cortical defect is noted at the anterior portion of the medial compartment, underneath the anterior horn of the medial meniscus, confirming the presence of an intra-articular fracture (arrow). Mild joint effusion is present.*



**FIGURE 2b:** CT Knee – Axial Slice  
*The cortical defect is shown extending into the tibial tunnel by 1.5 mm without displacement (arrow).*

of the medial tibial plateau and extending into the tibial tunnel by 1.5 mm. Joint effusion was also noted and the ACL graft was intact.

With the ACL graft integrity intact, non-weightbearing for four weeks with use of crutches, with a delay in the rehabilitation protocol, was prescribed to see if the fracture would heal. A follow-up appointment was given in four weeks' time. At follow-up, physical examination of her left knee found no swelling or pain on palpation, with only minimal loss of terminal knee extension. A repeat CT scan of the left knee revealed that the tibial plateau fracture was healed, and the patient was allowed to resume her rehabilitation protocol.

At 13 months post-surgical follow-up, the patient reported minimal pain of 1/10 intensity localized to the fracture site at the medial-anterior tibial. On palpation, a small bony abnormality is noted at the fracture site. Full knee range of motion was noted, with the exception of a 5 degree loss of genu recurvatum with the injured knee. The orthopaedic surgeon suspected that the surgical screw was slightly protruding from the tibial tunnel and leading to the residual pain. A lidocaine injection into the medial joint line of the knee was effective in eliminating the pain temporarily. At this point, the patient opted to tolerate the minor degree of pain without pursuing further interventions, and was able to return to certain sports (volleyball and basketball) on a regular basis.

At 22 months post-surgical follow-up, the minimal pain of 1/10 intensity at the fracture site remained, with aggravation of pain only after prolonged sitting (2 hours or more), or long distance running (5 km or more), where the intensity would increase to 3/10. The patient deemed this pain tolerable and continued with her recreational sports without difficulty.

## Discussion

### *Incidence:*

Tibial plateau fracture presenting as a complication following ACL reconstruction surgery is rare, with only ten English-language case reports documenting this occurrence.<sup>9-18</sup> Thietje et al described a tibial fracture after ACL reconstruction surgery, but as the article was written in German, details could not be obtained.<sup>19</sup> Although rare, it is important to be aware of this post-operative complication, as most cases required surgical fixation

of the fracture.<sup>10-12,15,16</sup> This warrants an in-depth understanding of the pathogenesis and clinical presentation of this post-surgical complication to aid in recognition and management.

### *Pathogenesis:*

Although its pathogenesis is not completely understood, there are contributing factors that predominantly relate to bone strength, tibial tunnel and graft harvest site. It has been proposed that in young healthy individuals with ACL reconstruction, the loss of trabecular cancellous bone is greater than cortical bone loss after the operative procedure. Even though trabecular cancellous bone constitutes only 20% of bone mass, there is a decreased transosseous bone strength as a result of the normal surgical procedure.<sup>20-22</sup> While there are no studies that specifically measure bone strength of the tibia following graft harvest or tibial tunnel drilling, biomechanical studies have found that bone defects, such as screw holes, can concentrate stress and decrease bone strength to torsional loading.<sup>23,24</sup> For instance, diaphyseal drill holes with a diameter greater than 20% of the bone have been shown to reduce bone strength by 55-90%.<sup>23,25-27</sup>

This can be further complicated by additional factors. Authors have also suggested that other biomechanical factors, such as motion of the graft within the tunnel and fixation methods/devices, and biological factors, such as graft swelling and use of allograft tissue, may also contribute to tunnel enlargement.<sup>28,29</sup> Further, with patellar tendon grafts, authors suggest that the tibial harvest site, combined with the tibial tunnel, may synergistically act as stress-risers to reduce proximal tibial bone strength.<sup>9-11,14</sup> In four of the cases of tibial fractures after ACL reconstruction, the patellar tendon autografts were involved.<sup>9-11,14,16,18</sup> In our case, the patient suffered a tibial plateau fracture with a gracilis-semitendonosis autograft, which was similar to two other cases found in the literature.<sup>13,15</sup> This may suggest that the tibial tunnel plays a larger role as a stress-riser when compared to the harvest graft site.

### *Clinical Presentation:*

The details of previous relevant case reports on tibial plateau fractures after ACL reconstruction are outlined in Table 1. Cases had an age range of 20-61 years, with 4 cases involving females and 8 cases in males. Most cases

Table 1:  
Published Case Reports on Tibial Plateau Fractures after ACL Reconstruction

Author(s), Year	Age, gender, type of fracture, graft	Presentation, trauma, onset after ACL surgery	Imaging confirming fracture	Outcome, follow-up
El-Hage et al., 1998 <sup>12</sup>	20 year-old male, intra-articular tibial plateau fracture extending into tibial tunnel, allograft	Pain, swelling after road traffic accident, 18 months	CT	Open reduction and internal fixation of fracture, full recovery at 7 months
Moen et al., 1998 <sup>14</sup>	29 year-old female, tibial fracture at graft harvest site, patellar tendon	Pain, swelling, inability to weightbear after minor fall, 6 weeks	X-rays	Protected weightbearing with cast and crutches, outcome not reported
Morgan and Steensen, 1998 <sup>9</sup>	30 year-old male, minimally displaced tibial plateau fracture extending into tibial tunnel, patellar tendon	Pain, swelling after direct trauma from baseball bat, 7 months	X-rays	Non-weightbearing for 4 weeks, full recovery at 4 weeks
Delcogliano et al., 2001 <sup>10</sup>	27 year-old male, displaced tibial plateau fracture extending into tibial tunnel, patellar tendon	Pain, swelling after motorcycle accident, 7 months	X-rays	Open reduction and internal fixation of fracture, mild quadriceps weakness at 1 year, early knee degeneration at 2 years
Mithofer et al., 2004 <sup>11</sup>	61 year-old female, bicondylar tibial plateau fracture extending into tibial tunnel, patellar tendon	Pain, swelling, inability to weightbear, crepitation after falling down stairs, 7 months	X-rays and CT	Minimally invasive surgical fixation, mild decrease in motion at 3 months
Sundaram et al., 2005 <sup>13</sup>	40 year-old female, undisplaced tibial plateau fracture extending into tibial tunnel, gracilis-semitendonosis	Pain, swelling, hemarthrosis after falling onto knee when walking, 12 months	MRI (not detected with x-rays)	6-week non-weightbearing cast and 6-week weightbearing knee brace, mild decrease in motion at 3 months
Thaunat et al., 2006 <sup>18</sup>	24 year-old male, fracture at tibial fixation site, patellar tendon	Pain, inability to weightbear, hemarthrosis after 4-ft fall, 4 years	CT	6-week non-weightbearing cast and 2-week weightbearing knee brace, full recovery at 7 months
Voos et al., 2007 <sup>16</sup>	43 year-old female, oblique metaphyseal tibial fracture extending into donor site, patellar tendon	Pain, swelling after falling while jogging on treadmill, 4 years	X-rays and CT	Open reduction and internal fixation of fracture, full recovery at 12 months
Polyzois et al., 2009 <sup>15</sup>	43 year-old male, distal femoral and tibial plateau fracture, gracilis-semitendinosis	Pain, swelling after road traffic accident, 2 weeks	X-rays	Open reduction and internal fixation of fracture, full recovery at 12 months
Gobbi et al., 2011 <sup>17</sup>	41 year-old male, tibial plateau fracture involving medial condyle and extending into tibial tunnel, semitendinosis	Pain, swelling, giving way after running backwards in soccer game, 4.5 years	X-rays and CT	Open reduction and internal fixation of fracture, full recovery at 12 months

used patellar tendon autograft<sup>9,11,14,16,18</sup>, with two cases using gracilis-semitendinosis autograft<sup>13,15</sup>, one case using double strand semitendonosis graft<sup>17</sup> and one case using a freeze-dried Achilles tendon allograft<sup>12</sup>. Most fractures involved either the tibial tunnel<sup>9-13,17</sup>, tibial fixation site<sup>14,18</sup> or graft harvest/donor site<sup>14,16</sup>. The case described by Polyzois et al had femoral and tibial fractures in the opposite direction of the ACL femoral and tibial tunnels, but it should be noted that the injury was preceded by high energy trauma from a road traffic accident, with the patient suffering multiple fractures.<sup>15</sup> All cases presented

with knee pain and a degree of swelling, and were preceded by some form of trauma, namely falls or motor vehicle accidents. One case was preceded by minimal trauma of running backwards during soccer, though it cannot be determined whether the onset of fracture occurred before or after the minimal trauma.<sup>17</sup> Three cases involved patients who could not weightbear after the incident.<sup>11,14,18</sup>

In our case, the patient also presented with pain and swelling, though there was no preceding trauma. To our best knowledge, this is the first published insufficiency fracture of the tibial plateau after ACL reconstruction

surgery, presenting only three weeks after the surgical procedure. Other authors have noted that it is important to rule out more sinister causes of swelling, including wound complications<sup>8</sup> and septic arthritis<sup>30,31</sup>. In a prospective consecutive cohort of subjects with primary ACL reconstruction in England from 2008-2010, it was found that a small percentage subsequently suffered from symptomatic deep venous thrombosis (0.30%), pulmonary thromboembolism (0.18%) or wound complication (0.75%).<sup>8</sup> Our patient was sent to the emergency department by the chiropractor to undergo blood tests and investigate the possibility of an infection or septic arthritis. This suggests that pain at the surgical site with persistent swelling should heighten the clinician's suspicion for a post-surgical complication, such as septic arthritis or peri-articular fracture, regardless of whether there was preceding trauma.

#### *Imaging:*

A brief review of the ACL reconstruction surgery is warranted to further understand the imaging findings on radiographs and advanced imaging. One of the primary ACL reconstruction procedures is the autologous doubled semitendinosis and gracilis tendon graft (also known as four-strand hamstring graft). This procedure involves a femoral tunnel positioned at the lateral femoral condyle and a tibial tunnel positioned through the medial tibial plateau. Various methods are used to secure the graft within the tunnels until bony union occurs, including interference screws and the distal femoral Endobutton device.<sup>32</sup>

Some of the previous case reports describing tibial plateau fractures were detected on knee radiographs<sup>10,11,14-17</sup> though other cases used solely computed tomography<sup>12,18</sup>. In cases where the fracture was found on CT, it was not reported whether knee radiographs had initially detected the fracture. Sundaram et al noted that their subject's undisplaced tibial plateau fracture was not detected with knee AP or lateral oblique radiographs and was only found on subsequent MRI.<sup>13</sup> Thus, it was recommended that all acutely painful and swollen knees from trauma, following ACL reconstruction, should undergo an MRI when knee radiographs are read as normal.<sup>13</sup> MRI has been shown to be a sensitive instrument to exclude occult fractures not detected on plain radiographs.<sup>33,34</sup> In our case, while the initial radiographs detected a cortical defect at the medial tibial plateau, CT was required to determine the precise

location and extent of the fracture. This supports the role of advanced imaging in cases where post-surgical fracture is suspected based on clinical presentation.

#### *Management:*

Treatment of tibial plateau fractures after ACL reconstruction has been variable.

In previous reports, five cases were surgically managed with open reduction and internal fixation<sup>10,12,15-17</sup>, one case was surgically managed with minimally invasive surgical fixation<sup>11</sup>, and four cases were managed with 4-6 weeks of non-weightbearing<sup>9,13,14,18</sup>. The surgical cases tended to be associated with moderate-to-high degrees of trauma and more severe fractures, such as displaced fractures. Mithofer et al successfully used minimally-invasive fracture fixation of an intra-articular tibial plateau fracture, which involved the use of indirect fracture reduction and new plate designs, and no ACL revision was necessary.<sup>11</sup> The distinct characteristic of our case is the early and insufficiency fracture onset. In all previous cases, the subjects were examined in a tertiary care setting, underscoring the importance of referring suspected cases of peri-articular fractures after ACL reconstruction to orthopedic specialists by primary contact providers.

In our patient's case, early detection of this fracture may have minimized the need for invasive treatment. The patient had pain and swelling only three weeks after her ACL reconstruction, and was assessed at a chiropractic clinic. Prompt investigations ordered by the chiropractor included knee radiographs, which detected a possible infection or septic arthritis, and facilitated an immediate referral to the emergency department. Delayed assessment and diagnosis of the tibial plateau fracture may have led to further progression of the fracture and possible indication for more invasive management, such as surgical fixation of the fracture or ACL revision if the graft was in jeopardy. An appropriate index of suspicion for post-surgical complications is important, particularly in primary care providers focused on post-surgical rehabilitation. For instance, a recent case report describes active post-operative ACL reconstruction rehabilitation combined with soft tissue therapy in a chiropractic clinic that facilitated successful recovery and return to function.<sup>35</sup> Authors emphasized the need to be up-to-date on the most recent evidence in post-surgical ACL rehabilitation, including early active exercise.<sup>35,36</sup> As highlighted in our patient's

case, effective management of post-surgical rehabilitation should not only include evidence-based rehabilitation protocols, but should also include an understanding of potential post-surgical complications, including tibial plateau fractures. This facilitates detection and appropriate management in both orthopedic surgeons and primary care providers, including chiropractors.

### Summary:

This case report described the occurrence of a tibial plateau fracture presenting three weeks after ACL reconstruction, without any preceding trauma. Discussion surrounded the role of bony defects caused by transosseous tibial tunnels from ACL reconstruction that may have contributed to the post-operative tibial plateau fracture. In this case, early detection allowed for conservative management in the form of four weeks of non-weightbearing and delayed rehabilitation protocol to allow the fracture to heal, avoiding the need for surgical fixation of the fracture. This suggests that all acutely painful knees with persistent swelling, whether preceded by trauma or not, should be carefully investigated by both primary care and tertiary care providers to determine the underlying pathology and rule out peri-articular fractures.

### References

1. Bjordal JM, Arnoy F, Hannestad B, Strand T. Epidemiology of anterior cruciate ligament injuries in soccer. *Am J Sports Med.* 1997; 25:341-345.
2. Fauno P, Wulff Jakobsen B. Mechanism of ACL injuries in soccer. *Int J Sports Med.* 2006; 27:75-79.
3. Arendt E, Dick R. Knee injury patterns among men and women in collegiate basketball and soccer. NCAA data and review of literature. *Am J Sports Med.* 1995; 23:694-701.
4. Fineberg MS, Zarins B, Sherman OH. Practical considerations in anterior cruciate ligament replacement surgery. *Arthroscopy.* 2000; 16: 715-724.
5. Lind M, Mehnert F, Pedersen AB. Incidence and outcome after revision anterior cruciate ligament reconstruction: results from the Danish registry for knee ligament reconstructions. *Am J Sports Med.* 2012; May 4 [Epub ahead of print].
6. Allum R. Complications of arthroscopic reconstruction of the anterior cruciate ligament. *J Bone Joint Surg Br.* 2003; 85:12-16.
7. Sekiya JK, Ong BC, Bradley JP. Complications in anterior cruciate ligament surgery. *Orthop Clin North Am.* 2003; 34:99-105.
8. Jameson SS, Downen D, James P, Serrano-Pedraza I, Reed MR, Deehan D. Complications following anterior cruciate ligament reconstruction in the English NHS. *Knee.* 2011, DOI:10.1016/j.knee.2010.11.011
9. Morgan E, Steensen RN. Traumatic proximal tibial fracture following anterior cruciate ligament reconstruction. *Am J Knee Surg.* 1998; 11:193-4.
10. Delcogliano A, Chiossi S, Caporaso A, Franzese S, Menghi A. Tibial plateau fracture after arthroscopic cruciate ligament reconstruction. *Arthroscopy.* 2001; 17:E16.
11. Mithofer K, Gill TJ, Vrahas M. Tibial plateau fracture following anterior cruciate ligament reconstruction. *Knee Surg Sports Traumatol Arthrosc.* 2004; 12:325-8.
12. El-Hage ZM, Mohammed A, Griffiths D, Richardson JB. Tibial plateau fracture following allograft anterior cruciate ligament (ACL) reconstruction. *Injury.* 1998; 29:73-4.
13. Sundaram RO, Cohen D, Barton-Hanson N. Tibial plateau fracture following gracilis-semitendinosus anterior cruciate ligament reconstruction: the tibial tunnel stress-riser. *Knee.* 2006; 13:238-240.
14. Moen KY, Boynton MD, Raasch WG. Fracture of the proximal tibia after anterior cruciate ligament reconstruction: a case report. *AM J Orthop.* 1998; 27:629-630.
15. Polyzois I, Manidakis N, Graham S, Tsiridis E. An unusual periarticular fracture following ipsilateral anterior cruciate ligament reconstruction. *Knee Surg Sports Traumatol Arthrosc.* 2009; 17:503-507.
16. Voos JE, Drakos MC, Lorich DG, Fealy S. Proximal tibia fracture after anterior cruciate ligament reconstruction using bone-patellar tendon-bone autograft: a case report. *HSSJ.* 2008; 4: 20-24.
17. Gobbi A, Mahajan V, Karnatzikos G. Tibial plateau fracture after primary anatomic double-bundle anterior cruciate ligament reconstruction: a case report. *Arthroscopy.* 2011; 27(5):735-40.
18. Thauat M, Nourissat G, Gaudin P, Beaufile P. Tibial plateau fracture after anterior cruciate ligament reconstruction: role of the interference screw resorption in the stress riser effect. *Knee.* 2006; 13(3): 241-3.
19. Theitje R, Faschingbauer M, Nurnberg HJ. Spontaneous fracture of the tibia after replacement of the anterior cruciate ligament with absorbable interference screws: a case report and review of the literature. *Unfallchirurg.* 2000; 103: 594-596.
20. Kartus J, Stener S, Nilssen R, Nilsson U, Eriksson BI, Karlsson J. Bone mineral assessments in calcaneus after anterior cruciate ligament injury: an investigation of 92 male patients before and two years after reconstruction or revision surgery. *Scan J Med Sci.* 1998;8:449-455.
21. Ejerhed L, Kartus J, Nilssen R, Nilsson U, Kullenberg R, Karlsson J. The effect of anterior cruciate ligament surgery on bone mineral in the calcaneus: a prospective study with

- a 2-year follow-up evaluation. *Arthroscopy*. 2004; 20: 352-359.
22. Nyland J, Fisher B, Brand E, Krupp R, Caborn DNM. Osseous deficits after anterior cruciate ligament injury and reconstruction: a systematic literature review with suggestions to improve osseous homeostasis. *Arthroscopy*. 2010; 26(9): 1248-1257.
  23. Burstein AH, Currey J, Frankel VH et al. Bone strength: the effect of screw holes. *J Bone Joint Surg AM*. 1972; 54: 1143-1156.
  24. Uthoff HK. Mechanical factors influencing the holding power of screws in compact bone. *J Bone Joint Surg Br*. 1973; 55(3): 633-9.
  25. Brooks DB, Burstein AH, Frankel VH. The biomechanics of torsional fractures: the stress concentration effect of a drill hole. *J Bone Joint Surg AM*. 1970; 52:507-514.
  26. Johnson BA, Fallat LM. The effect of screw holes on bone strength. *J Foot Ankle Surg*. 1997; 36:446-451.
  27. Rosson J, Egan J, Shearer J, Monro P. Bone weakness after the removal of plates and screws. Cortical atrophy or screw holes? *J Bone Joint Surg Br*. 1991; 73(2): 283-6.
  28. Konan S, Haddad FS. Femoral fracture following knee ligament reconstruction surgery due to an unpredictable complication of bioabsorbable screw fixation: a case report and review of literature. *J Orthop Traumatol*. 2010; 11(1): 51-5.
  29. Wilson TC, Kantaras A, Atay A, Johnson DL. Tunnel enlargement after anterior cruciate ligament surgery. *Am J Sports Med*. 2004; 32(2): 543-9.
  30. Mouzopoulos G, Fotopoulos VC, Tzurbakis M. Septic knee arthritis following ACL reconstruction: a systematic review. *Knee Surg Sports Traumatol Arthrosc*. 2009; 17:1033-1042.
  31. Wang C, Ao Y, Wang J, Hu Y, Cui G, Yu J. Septic arthritis after arthroscopic anterior cruciate ligament reconstruction : a retrospective analysis of incidence, presentation, treatment and cause. *Arthroscopy*. 2009; 25(3): 243-249.
  32. Meyers AB, Haims AH, Menn K, Moukaddam H. Imaging of the anterior cruciate ligament repair and its complications. *AJR*. 2010; 194: 476-484.
  33. Remplik P, Stabler A, Merl T, Roemer F, Bohndorf K. Diagnosis of acute fractures of the extremities: comparison of low-field MRI and conventional radiography. *Eur Radiol*. 2004; 14(4): 625-30.
  34. Oka M, Monu JU. Prevalence and patterns of occult hip fractures and mimics revealed by MRI. *Am J Roentgenol*. 2004; 182(2): 283-8.
  35. Solecki TJ, Herbst EM. Chiropractic management of a postoperative complete anterior cruciate ligament rupture using a multimodal approach: a case report. *J Chiropr Med*. 2011; 10(1): 47-53.
  36. Beynon BD, Uh BS, Johnson RJ, et al. Rehabilitation after anterior cruciate ligament reconstruction: a prospective, randomized, double-blind comparison of programs administered over 2 different time intervals. *Am J Sports Med*. 2005;33:347-59.

# Therapeutic interventions employed by Greater Toronto Area chiropractors on pregnant patients: results of a cross-sectional online survey

Tammy Yuen, BSc(Hons)  
 Kayla Wells, BKin(Hons)  
 Samantha Benoit, BSc  
 Sahila Yohanathan, BSc(Hons)  
 Lauren Capelletti, BKin(Hons)  
 Kent Stuber, BSc, DC, MSc\*

**Introduction:** *Due to different biomechanical, nutritional, and hormonal considerations, it is possible that chiropractors may employ different therapeutic interventions and recommendations for pregnant patients than non-pregnant ones. The objective of this study was to determine the therapeutic interventions that chiropractors who are members of the Ontario Chiropractic Association in the Greater Toronto Area most commonly provide to pregnant patients.*

**Methods:** *An introductory e-mail was sent in October 2011 to 755 members of the Ontario Chiropractic Association within the Greater Toronto Area five days prior to a 15 question survey being distributed via e-mail. Reminder e-mails were sent 13 days and 27 days later. Using descriptive statistics, demographic information was reported along with reported use of different treatments and recommendations for pregnant patients*

**Results:** *A response rate of 23% was obtained. The majority of the respondents (90%) reported using the Diversified technique on pregnant patients, followed by soft tissue therapy (62%) and Activator (42%). The most common adjunctive therapy recommended to pregnant patients was referral to massage therapy (90%). Most of the respondents (92%) indicated that they prescribe stretching exercises to pregnant patients and recommend a multivitamin (84%) or folic acid (81%) to pregnant patients.*

**Introduction :** *En raison de considérations biomécaniques, nutritionnelles et hormonales différentes, il est possible que les chiropraticiens emploient différentes interventions thérapeutiques et différentes recommandations pour les patientes enceintes et les patientes non-enceintes. L'objectif de cette étude était de déterminer les interventions thérapeutiques que les chiropraticiens membres de l'Association chiropratique de l'Ontario dans la région du Grand Toronto proposent aux patientes enceintes.*

**Méthodologie :** *Un courriel d'accueil a été envoyé en octobre 2011 aux 755 membres de l'Association chiropratique de l'Ontario dans la région du Grand Toronto, cinq jours avant l'envoi d'un sondage de 15 questions par courriel. Des courriels de rappel ont été envoyés 13 et 27 jours après. À l'aide de statistiques descriptives, des informations démographiques ont été rapportées ainsi que l'administration de différents traitements et recommandations pour les patientes enceintes.*

**Résultats :** *Un taux de réponse de 23 % a été obtenue. La majorité des répondants (90 %) a indiqué utiliser la technique diversifiée sur les patientes enceintes, suivi par les traitements des tissus mous (62 %) et l'activateur (42 %) Les traitements auxiliaires les plus fréquemment recommandés aux patients sont les massothérapies (90 %). La plupart des répondants (92 %) ont indiqué prescrire des exercices d'étirements pour les patientes enceintes et recommander des comprimés multivitaminés (84 %) ou de l'acide folique (81 %) aux patientes enceintes.*

\*Division of Graduate Education & Research, Canadian Memorial Chiropractic College

Corresponding author and contact information:

Kent Stuber BSc, DC, MSc, 19-8 Weston Drive SW, Calgary, Alberta, T3H 5P2; kstuber@cmcc.ca, 403-685-5252.

The authors declare that there are no disclaimers or declarations to be made in the preparation of this manuscript. The authors did not receive any support in the preparation of this manuscript.

©JCCA 2013



**Conclusion:** *In agreement with previous research on chiropractic technique usage on non-pregnant patients, the majority of respondents indicated treating pregnant patients with the Diversified technique, with other chiropractic techniques being utilized at varying rates on pregnant patients. Most respondents indicated prescribing exercise, and making adjunctive and nutritional recommendations frequently for their pregnant patients.*

**KEY WORDS:** chiropractic, pregnancy, interventions, therapy

---

**Conclusion :** *En accord avec des précédentes recherches sur l'utilisation de techniques chiropratiques sur les patientes non-enceintes, la majorité des répondants a indiqué traiter les patients avec la technique diversifiée, ainsi que d'autres techniques chiropratiques utilisées à différents fréquences sur les patientes enceintes. La plupart des répondants ont indiqué fréquemment prescrire des exercices, et faire des recommandations auxiliaires et nutritionnelles pour leurs patientes enceintes.*

**MOTS CLÉS :** chiropratique, grossesse, interventions, thérapie

---

## Introduction

Reducing patient discomfort and musculoskeletal pain during pregnancy and potentially helping facilitate an uncomplicated labour and delivery have been described as the aims of chiropractic care for pregnant patients.<sup>1</sup> The 2005 National Board of Chiropractic Examiners Job Analysis of Chiropractic surveyed American chiropractors and found that on average they indicated that they “rarely” treat pregnant women.<sup>2</sup> However, at least 50% of pregnant women experience back pain at some time throughout their pregnancy<sup>3</sup>, and 50% to 75% experience back pain during labour<sup>4</sup>. Previous studies have indicated that both patients and chiropractors report safe and successful treatment of pregnancy related back pain through chiropractic treatment.<sup>5-9</sup>

With only a small spectrum of drugs considered safe to use during pregnancy<sup>10</sup>, alternative therapies that have a history of safety and effectiveness for the treatment of musculoskeletal pain may be sought out by this population. Chiropractic manual therapy, exercise, massage and techniques of local anesthesia such as Lidocaine<sup>11</sup> are all alternative treatments that can be sought out by pregnant women. While there is limited evidence to support spinal manipulation and mobilization for the chiropractic care of pregnant patients, there continues to be pregnant women who seek out chiropractic care for treatment of various

pregnancy related complaints including, but not limited to, back pain, posterior pelvic pain, costovertebral injuries, carpal tunnel syndrome, lower extremity pain, and headaches.<sup>12</sup>

Chiropractors may employ a variety of different treatment technique systems when treating non-pregnant patients. A survey regarding technique systems used by post-1980 graduates of the Canadian Memorial Chiropractic College (CMCC) by Mykietiuk et al<sup>13</sup>, revealed that the technique systems most commonly used in private practice in Ontario were Diversified Technique, followed by Activator®, Thompson, and Active Release Techniques®.

The objective of this study was to determine the most commonly used treatments that chiropractors in the Greater Toronto Area (GTA) provide to their pregnant patients. It is possible that the treatments provided to pregnant patients may be different from those offered to the non-pregnant population when accounting for their unique biomechanical, nutritional, and hormonal considerations. The resulting information may be useful for clinicians and chiropractic students who may benefit from learning which treatments and therapies are most commonly employed on pregnant patients by their colleagues and then follow the principles and process of evidence based practice to investigate their potential value for their

pregnant patients. The information will also be of value to researchers in planning further research on chiropractic treatment of pregnant patients as the most commonly used treatments should likely be among the first and most investigated.

## Methods

### *Subjects*

Ethics approval was provided by the CMCC Research Ethics Board (project number 111013). The participants were selected from the 2009 Canadian Chiropractic Association (CCA) digital database as this was the last publicly available CD-ROM based directory. The participants in this study were chiropractors located in the GTA (consisting of the Halton Region, Peel Region, York Region, City of Toronto and Durham Region) and who were members of the Ontario Chiropractic Association (OCA). The GTA was selected as previous surveys have used this population<sup>14</sup> and OCA members were used as this is the largest professional group representing chiropractors in Ontario. There were no limits on type of practice or techniques employed, but the inclusion criteria consisted of actively practicing OCA members in the GTA who see pregnant patients in their practices. Subjects were excluded if they no longer practiced in the GTA or did not see pregnant patients. No compensation was provided for completing the survey. As this was a descriptive survey, there was no allocation to different groups in this study. Participant identities were kept confidential, only visible to study team members and the CMCC Office of Research Administration and response items were reported in aggregate form.

### *Pilot Study*

Prior to distribution of the survey to all eligible chiropractors in the GTA, a brief pilot study was conducted. An initial draft of the survey was completed confidentially by ten clinicians at the CMCC campus clinic in Toronto. This allowed for identification of any problem areas such as unclear, ambiguous, or lengthy questions and allowed for determination of the amount of time for survey completion. Feedback from the pilot study was provided from each individual clinician, and guided necessary changes before distribution of the survey itself. The results from the pilot study group were not reported.

### *Survey*

The survey is available from the corresponding author upon request and consisted of 15 multiple-choice style questions developed by the authors to identify the proportion of responding chiropractors who utilize the treatments of interest on pregnant patients. Face validity was assessed continuously through the development and pilot study periods by the authors and the final survey was deemed to have face validity. Items included questions eliciting demographic information and specific questions regarding chiropractic techniques and other treatments employed when seeing pregnant patients. The survey was administered by e-mail using the e-mail address provided in the 2009 CCA digital database.

### *Survey Distribution*

Prior to the commencement of the survey in October 2011, a preliminary e-mail was sent to the selected chiropractors to notify them of the study. The survey was then distributed five days later. The survey e-mail message consisted of a study information and informed consent sheet. Those who agreed to participate were required to click on an "I Agree" button which linked them securely to the survey via the CMCC Survey Monkey™ account. Thirteen days following the survey launch, a reminder e-mail was sent to the chiropractors who did not complete the survey. An additional reminder was sent 14 days following the first reminder (27 days following the initial distribution). Thus there were a total of four possible contacts distributed (including the pre-notification message) in order to increase the response rate. Participants were given the opportunity to receive the results of this study once it was completed by indicating interest at the end of the survey and providing their e-mail address.

### *Data Analysis*

Aggregated survey responses were provided to the authors from CMCC's Survey Monkey™ account by CMCC's Office of Research Administration in the form of a Microsoft Excel spreadsheet. The data was printed and stored in a secure filing cabinet by one of the authors (KJS). Descriptive statistics were used to analyze this cross-sectional survey using Microsoft Excel.

### *Results*

E-mail messages were sent to 755 e-mail addresses of

Table 1.  
*Chiropractic Colleges attended by respondents  
(n=140, 3 missing a response).*

Chiropractic College	Number of Respondents	Percentage of Respondents (%)
Canadian Memorial Chiropractic College	119	85
Logan College of Chiropractic	5	3.6
National University of Health Sciences	5	3.6
New York Chiropractic College	2	1.4
Life University	2	1.4
Life Chiropractic College West	1	0.7
Cleveland Chiropractic College	1	0.7
Texas Chiropractic College	1	0.7
Palmer College of Chiropractic	1	0.7
Palmer College of Chiropractic West	1	0.7
Western States Chiropractic College	1	0.7
Anglo-European College of Chiropractic	1	0.7

Table 2.  
*Respondent year of graduation  
(n=138, 5 missing a response).*

Year of Graduation	Number of Respondents	Percentage of Respondents (%)
Last 5 years (2007-2011)	16	11.6
Last 6-10 years (2002-2006)	33	23.9
Last 11-15 years (1997-2001)	26	18.8
Last 16-20 years (1992-1996)	13	9.4
Last 21-25 years (1987-1991)	9	6.5
Last 26-30 years (1982-1986)	17	12.3
Last 31-35 years (1977-1981)	16	11.6
Last 36-40 years (1972-1976)	6	4.3
Last 41-45 years (1967-1971)	2	1.4

Table 3.  
*Location in which the responding chiropractors practice,  
organized by region  
(n=136, 7 missing a response).*

Location	Number of Respondents	Percentage of Respondents (%)
City of Toronto	74	54.4
York Region	27	19.9
Halton Region	23	16.9
Durham Region	16	11.8
Peel Region	10	7.4

Table 4.  
*Further training received by responding chiropractors  
(n=28, 115 missing a response).*

Further Training	Number of Respondents	Percentage of All 143 Respondents (%)
International Chiropractic Pediatric Association (ICPA)	11	7.7
Fellow of the Royal College of Chiropractic Sports Sciences	8	5.6
Fellow of the College of Chiropractic Sciences	5	3.5
Fellow of the College of Chiropractic Rehabilitation Sciences	5	3.5
Fellow of the College of Chiropractic Orthopedists	2	1.4

chiropractors in the Greater Toronto Area. Of these, 125 of the e-mail messages were returned as undeliverable due to change of clinic e-mail addresses or addresses which no longer existed. As such, 630 e-mail addresses were sent successfully and 143 respondents gave consent to fill out the online survey. Therefore, the adjusted response rate was calculated as 22.7%. However, there were not necessarily 143 responses to each of the questions on the survey as some of the respondents did not complete all of the questions. The questions with the lowest response rates were those pertaining to further training (28 responses, 115 missing a response) and nutritional supplement recommendations (70 responses and 73 missing a response).

### Demographics

Approximately 39% of respondents were female and 61% were male. Tables 1 and 2 indicate the chiropractic college of graduation of the respondents and ranges of graduation years, respectively. Table 3 depicts the different geographic regions where the responding chiropractors practice within the GTA. Of the 143 respondents, only 29 (20.3%) indicated that they completed training provided by any of the Canadian recognized Fellowship programs or the International Chiropractic Pediatrics Association (ICPA) as seen in Table 4.

**Frequency of Treating Pregnant Patients**

When asked how often they treat pregnant patients, 10.9% of the respondents stated they “Always” treat them, which was defined as several per week, 34.1% stated “Often” (defined as several per month), 54.3% stated “Seldom” (defined as a few per year), and 0.7% stated “Never”.

**Techniques Used to Treat Pregnant Patients**

When asked which chiropractic technique systems they use when treating pregnant patients, over half of the respondents reported using Diversified technique (89.9%) and soft tissue therapy (61.6%), followed by Activator (42.0%) as shown in Table 5.

Table 5.

*Chiropractic technique systems used by respondents when treating pregnant patients (n=138, 5 missing a response).*

Technique System	Number of Respondents	Percentage of Respondents
Activator	58	42.0%
Acupuncture	31	22.5%
Applied Kinesiology	8	5.8%
BEST	1	0.7%
CBP	3	2.2%
Cox-Flexion Distraction	1	0.7%
Cranial Therapies	7	5.1%
Diversified	124	89.9%
Cranial Sacral	9	6.5%
Gonstead	9	6.5%
Graston	8	5.8%
Logan Basic	12	8.7%
Meric	3	2.2%
Network	1	0.7%
Nimmo	9	6.5%
NUCCA	1	0.7%
Palmer HIO	5	3.6%
Soft-Tissue Therapy (ART/MRT)	85	61.6%
SOT	17	12.3%
Spinal Stressology	0	0.0%
Thompson	27	19.6%
Trigenics	7	5.1%
Torque Release	3	2.2%
Webster Technique	35	25.4%
Total Body Modification (TBM)	2	1.45%
Koren Specific Technique (KST)	1	0.7%
Kinesiotaping	1	0.7%
Strain-counterstrain	1	0.7%
Rehabilitation	1	0.7%
Exercise/mobilizations/education	2	1.45%

Table 6.

*Adjunctive treatments utilized on pregnant patients by respondents (n=125, 18 missing a response).*

Answer Options	Response Percentage	Response Count
Orthotics	66.4%	83
Referral to Massage Therapy	90.4%	113
Postural Belts (Pelvic Stabilization Belts, Trochanteric Belt, Pelvic Sling, etc.)	55.2%	69
Other:		
Arvigo Technique (Maya Abdominal Therapy)	1	0.8%
Compression Stockings/Socks	2	1.6%
Kinesio Taping	1	0.8%
Referral to Cranial Sacral Therapist	1	0.8%
TCM practitioner referral	2	1.6%
Naturopath referral	1	0.8%
Nutritionist referral	1	0.8%
Total Body Modification (TBM)	1	0.8%
Education	1	0.8%
Pillows	1	0.8%

Table 7.

*Forms of exercise prescribed by responding chiropractors to pregnant patients (n=130, 13 missing a response).*

Answer Options	Response Percent	Response Count
Stretching Exercises	91.5%	119
Strengthening Exercises	66.9%	87
Core Stabilization Exercises	59.2%	77
Proprioceptive/Balance Exercises	30.8%	40
Cardio Exercises	25.4%	33

**Additional Treatments Used on Pregnant Patients**

When asked what additional treatments were used on pregnant patients, most respondents reported referrals for massage therapy (90.4%), with orthotics being the second most common adjunctive treatment at 66.4%, as seen in Table 6.

**Exercises Prescribed to Pregnant Patients**

When asked which forms of exercise were prescribed to pregnant patients it was found that stretching exercises were prescribed by 91.5% of respondents, and strengthening exercises were prescribed by 66.9% of the respondents as shown in Table 7.

**Nutritional supplement recommendations made by chiropractors to their pregnant patients**

When asked about nutritional supplements recommended to pregnant patients, a variety of suggestions were made by the respondents, with 84.3% recommending multivitamins and 81.4% recommending folic acid, several other supplements are also indicated in Table 8.

**Estimates of Percentage of Patients Returning for Post-Partum care**

When asked about the percentage of their pregnant patients who returned for post-partum care, 59.3% of the respondents estimated that at least 80% of their pregnant patients returned for post partum care, as seen in Table 9.

**Discussion**

To our knowledge this is the first study to investigate which techniques and treatments are used most commonly by chiropractors specifically when treating pregnant patients. Previously, a survey of a small group of chiropractors conducted by Stuber<sup>7</sup> found that most of the respondents used spinal manipulative therapy, soft tissue therapy, exercise therapies and patient education on pregnant patients with back and/or neck pain, headaches, or benign vertigo. However, the extent to which different techniques and therapies are actually being utilized on that particular population by chiropractors was not reported.

**Chiropractic Technique Usage**

The majority of chiropractors from the current survey indicated using Diversified technique when treating preg-

Table 8.

*Nutritional supplement recommendations made by responding chiropractors to their pregnant patients (n=70, 73 missing a response).*

Supplement	Response Percent	Response Count
Folic acid	81.4%	57
Multivitamin	84.3%	59
Iron Supplementation	25.7%	18
Calcium Supplementation	35.7%	25
Vitamin E	14.3%	10
Vitamin A	14.3%	10
Other		
Nutritionist referral	1.4%	1
Parturition preparation	1.4%	1
Combination/fetal development & clearing remedies	1.4%	1
Primary health care provider referral	1.4%	1
Naturopath referral	5.7%	4
Omega 3 fatty acids	5.7%	4
Probiotics	2.9%	2
Registered Dietitian referral	1.4%	1
Vitamin B-50 complex	1.4%	1
Multivitamins	2.9%	2
Vitamin D	1.4%	1
Omega 6 fatty acids	2.9%	2
Prenatal vitamins	4.3%	3
Magnesium	1.4%	1
Vitamin B	1.4%	1
Bioflavonoids	1.4%	1
Nutrition Advice/Education	2.9%	2
Eicosanoids (EEA's)	1.4%	1

Table 9.

*Respondent estimates of percentage of patients returning for post-partum care (n = 101, 42 missing a response).*

Answer Options of Percentage of Pregnant Patients who return for post-partum care	Number of Respondents who Indicated	Percentage of Respondents who Indicated
10%	7	6.9%
20%	5	5.0%
30%	2	2.0%
40%	2	2.0%
50%	14	13.9%
60%	3	3.0%
70%	8	8.0%
80%	18	17.8%
90%	26	25.7%
100%	16	15.8%

nant patients. This is consistent with the findings of a previous survey of Canadian chiropractors by the National Board of Chiropractic Examiners<sup>15</sup> who indicated that 87.3% of their respondents primarily used Diversified technique to treat their patients, albeit without dividing their patient populations into different subgroups such as pregnant patients. The majority of the respondents in the current survey were educated at the CMCC where Diversified technique is taught exclusively. However, according to the 2005 Job Analysis of Chiropractic in the United States, 96.5% of responding chiropractors use the Diversified technique and 71.5% of patients were treated with this technique, regardless of belonging to any particular subgroups, such as pregnancy.<sup>2</sup>

The second most popular technique reported by chiropractors in this survey when treating pregnant patients was soft tissue therapies (STT) such as Active Release Technique® (ART®) and Myofascial Release Technique (MRT), followed by use of the Activator®. These findings are in line with those of Mykietiuk et al<sup>13</sup> who found that 24% of their Canadian respondents utilized soft tissue therapies, while 15% used the Activator on their general patient populations. Thus from the current survey it would appear that a larger proportion of chiropractors reported using Activator and/or STT on pregnant patients, although this could represent an increase in the use of these techniques across patient groups.

### *Exercise Prescription*

Nearly all of the respondents indicated prescribing exercises to their pregnant patients and this appears to follow an evidence-based perspective, and is similar to exercise utilization rates by chiropractors previously reported by the NBCE.<sup>2</sup> As stated by Fast et al<sup>16</sup>, during pregnancy physical activity may prevent or manage chronic conditions such as hypertension, obesity, gestational diabetes, dyspnea and pre-eclampsia. Regular physical activity may help women meet gestational weight gain targets and thus positively influence maternal-fetal outcomes, as well as improving well-being and quality of life.<sup>17</sup>

Approximately two-thirds of our respondents reported prescribing strengthening exercises to their pregnant patients. Although it was not specified for which areas of the body respondents were prescribing these strengthening exercises, while roughly three out of five respondents indicated prescribing core stabilization exercises. Borrgren<sup>1</sup>

has suggested that targeting the transversus abdominis muscle specifically during pregnancy to potentially prevent some of the postural alterations in the third trimester, therefore potentially reducing the amount of pain experienced. The PARmed-X for Pregnancy from the Canadian Society for Exercise Physiology also supports exercises of the abdomen as being important during pregnancy to promote good posture and prevent low back pain, prevent diastasis recti and strengthen the muscles of labour.<sup>18</sup> The PARmed-X also suggests strengthening exercises for the upper and lower back to promote good posture. The buttocks and lower limbs should be strengthened to facilitate weight bearing and prevent varicose veins. It also advocates Kegel exercises to strengthen the pelvic floor and prevent incontinence. Stretches, proprioceptive/balance exercises, and cardiovascular activity were also reportedly prescribed by respondents to their pregnant patients. The PARmed-X suggests warm up and cool down exercises be done and should include range of motion exercises for all major joints and static stretching for all major muscle groups. Regarding cardiovascular activity while pregnant, some alterations must be made as a result of reduced maximal heart rate reserve during gestation and modified target heart rate zones are provided in the PARmed-X for Pregnancy Guidelines. In a study by Wolfe and Weissgerber<sup>19</sup> it was recommended that pregnant women engage in aerobic exercise regularly for at least 15 minutes, three days per week at the target intensity. Exercise frequency can be increased to four to five days per week and the duration can be increased to 25 to 30 minutes per session at the target intensity to increase maternal physical fitness. To illustrate the need for pregnant women to avoid exercising too frequently or infrequently, the study by Campbell and Matola<sup>20</sup> indicated that women who participate in structured exercise five or more times per week have an increased chance of delivering a low birth weight infant compared with women who exercised three or four times per week. Women who exercised two days or less per week were also at increased risk for low birth weight.

In a recent study by Stafne et al<sup>21</sup> it was found that pregnant women who adhered to a prescribed exercise protocol (consisting of moderate intensity exercise of 45 to 60 minutes in duration, three days per week) tended to have lower weight, had a lower BMI, and reported less evening pain when compared with control women. While the two groups in that study were similar in terms of lumbopelvic

pain prevalence, the women who adhered to the exercise protocol had less disability compared to the women in the control group, taking less time for sick leave due to lumbopelvic pain.

### *Dietary and Nutritional Supplement Recommendation*

Requirements for many, but not all, micronutrients increase during pregnancy.<sup>22</sup> Chiropractors frequently provide nutritional and dietary recommendations to patients.<sup>2</sup> As a component of prenatal care micronutrient supplementation may reduce maternal morbidity and mortality directly by treating a pregnancy-related illness, or indirectly by lowering the risk of complications at delivery. Nevertheless, the effectiveness of supplementation programs, notably of iron and folate, has tended to focus on infant outcomes, perinatal mortality, preterm delivery, and low birth weight.<sup>23</sup> In the current survey multivitamins and folic acid were the most commonly recommended nutritional supplements to pregnant patients by respondents. This high percentage of respondents prescribing folic acid is in line with recommendations by the World Health Organization.<sup>24</sup> The WHO states that folate dietary allowances during pregnancy increase substantially, by 147%. This increase is necessary in order to build or maintain maternal stores and to meet the needs of rapidly growing maternal and fetal tissues.<sup>24</sup> The administration of folic acid in the periconceptional period reduces the number of births with neural tube defects by 75%<sup>25</sup>; thus, folic acid administration is recommended as standard prenatal care by the International Nutritional Anemia Consultative Group. The maximum dosage for folate is 1000 µg/d.<sup>23</sup>

Vitamin E and Vitamin A were each recommended to pregnant patients by approximately one in seven of this survey's respondents. The Food and Agriculture Organization/WHO recommended that the daily allowance for vitamin A be 20% higher for pregnant women than for non-pregnant, non-lactating women because of the extensive cell proliferation and development of the fetus.<sup>26</sup> One explanation for Vitamin E being prescribed less than other vitamins and supplements could be due to discrepancies in the literature. According to Ladipo<sup>22</sup> Vitamin E supplementation is not needed in pregnancy because most diets containing plant oils, fruit, and vegetables should provide an adequate supply of Vitamin E, and pregnancy adds no further Vitamin E requirements or needs. Conversely,

the National Research Council<sup>26</sup> stated that Vitamin E is needed for fetal growth and they recommended that Vitamin E intake increase by 25% in pregnancy.

Additional nutritional supplement recommendations reportedly made by chiropractors to their pregnant patients in this survey, albeit at much lower rates, included eicosanoids (EEA's), combination fetal development and clearing remedies, Omega-3 and Omega-6 fatty acids, probiotics, vitamin B-50 complex, vitamin D, pre-natal vitamins, magnesium, vitamin B, and bioflavonoids. Referrals of pregnant patients to other health care professionals were also indicated by respondents such referrals as to the patient's other primary health care provider, or to a naturopathic practitioner, nutritionist, or registered dietitian for dietary advice.

According to the Food and Agriculture Organization's recommendations, the dietary allowance of Vitamin D for pregnant women increases 300% to account for the calcium deposition and bone mineralization occurring in the fetus.<sup>27</sup> Conversely, other sources, such as the Institute of Medicine<sup>28</sup> have indicated that vitamin D supplementation is likely not necessary during pregnancy except perhaps in high-risk population groups, for example, in women whose clothing limits exposure to direct sunlight and in women who live in northern latitudes with few hours of daylight. They also note that vitamin D can be toxic to both the mother and fetus if given in large doses during pregnancy, although the intake at which this occurs is uncertain because inter-individual sensitivity to excessive intake varies.<sup>27</sup> They recommend women take smaller, daily doses compared to a few large doses to decrease the risk of toxicity. Vitamin B6 and B12 deficiency rarely occurs (other than in strict vegetarians) so the FAO/WHO has not recommended additional requirements for pregnant women.<sup>26</sup>

### *Adjunctive Treatment Recommendations*

The most common adjunctive treatment recommended to pregnant patients was massage therapy, followed by recommendations for orthotics and trochanteric belts. According to the 2005 NBCE Job Analysis of Chiropractic, the rates of massage therapy utilization by responding chiropractors were 84.9%, compared with 81.8% for orthotics.<sup>2</sup> Additional recommended products included compression socks, kinesiotaping and pillows. Respondents also indicated referring their pregnant patients

to Traditional Chinese Medical (TCM) practitioners, naturopaths, nutritionists, or other chiropractic technique therapists at varying, albeit low, frequencies. Pregnant patients often present with a variety of conditions and the need for gynecological consultations, thus it is paramount that chiropractors and other health professionals work collaboratively.

### *Post-Partum Chiropractic Treatment*

According to this survey, nearly 60% of respondents estimated that at least 80% of their pregnant patients return for chiropractic care after delivery. Post-partum patients are still undergoing hormonal and anatomic changes to return to the pre-pregnancy stage. Postpartum health is under-addressed by researchers, clinicians, and women themselves as approximately 90% of women report at least one health problem soon after delivery.<sup>29</sup> Conditions such as low back pain, urinary stress incontinence, fecal incontinence, urinary frequency, depression and anxiety, hemorrhoids, frequent headache and migraines cause distress for new mothers. Up to one third of women have reported back pain lasting up to three months after childbirth.<sup>30</sup> Chiropractors can assist post-partum women with musculoskeletal dysfunction and educate new mothers regarding new physical and mental challenges in order to cope and manage appropriately.

### *Limitations*

There were several limitations to this study. Surveys were only sent to chiropractors who were members of the OCA within the GTA, thus it is possible that the results are not representative of the wider population of chiropractors across the country, particularly as the majority (85%) of respondents were graduates of CMCC. This is higher than the actual percentage of Canadian chiropractors who are CMCC graduates, which has decreased over recent years due to an influx of graduates from chiropractic educational institutions in the United States and internationally.<sup>13</sup> Current data provided by the OCA indicated that 76% of their members province-wide were CMCC graduates (personal communication with KJS September 18, 2012). The large percentage of respondents who were CMCC graduates may have been influenced by a larger proportion of CMCC graduates practicing in the GTA owing to CMCC's location in Toronto. It is thus possible that our results could be influenced by a potential association be-

tween the educational institution where the majority of our respondents trained and their practice style. Furthermore, 54% of our respondents graduated between 1997 and 2011, compared with 60% of OCA members, while 46% of our respondents graduated either in or prior to 1996, compared with 37% of OCA members province-wide currently (personal communication with KJS September 18, 2012). The low response rate of 22.7%, and the relatively small sample size could again lead to questions as to whether or not the results may be representative of all Canadian chiropractors. Some technical difficulties were encountered when initially distributing the survey as well as the first reminder, which required two attempts when sending each e-mail message, and unfortunately that may have affected the response rates. We may have been able to increase the response rate by attempting a telephone call to those chiropractors whose e-mail messages were returned as undeliverable; however due to time constraints we were unable to do so. Finally, our results were only presented descriptively; future research could look for bivariate and multivariable associations between particular demographic variables and different treatment-related variables.

One strength of this study was that while the survey was only distributed to members of the OCA within the GTA, there was a good distribution of respondents across the GTA. In an attempt to improve response rates, this survey employed pre-notification, which Russell et al<sup>31</sup> found to have a non-significant trend towards a higher response rate in previous surveys of chiropractors. Several e-mail messages were distributed to recipients and the response rate for this survey was within ranges previously reported in the literature for previous surveys of chiropractors, albeit well below the mean of 54% reported by Russell et al<sup>31</sup>. Russell et al<sup>31</sup> found a significant association between the number of mailings of a survey and response rate by chiropractors, where surveys with fewer than three mailings had a significantly lower average response rate than those where three or more mailings were employed. We utilized four mailings (pre-notification, an initial mailing and two reminders) and offered survey results to respondents, a technique that has also been found to increase response rates<sup>32</sup> and yet we still had a low response rate and this does potentially threaten the validity of our findings. One potential factor that may have been detrimental to our response rate was that this was an online study, which is a



convenient and cost-effective means of surveying potential participants but can have lower response rates than paper based surveys.<sup>32</sup> Furthermore, it has been noted that health professionals are becoming increasingly resistant to completing surveys, with one reason being that some health professionals have simply instituted policies against completing surveys.<sup>33</sup> It has also been found that response rates tend to be higher in surveys that are personalized, have a deadline for completion, have some form of incentive, indicate that others have responded, or are not anonymous, and applying these principles may have helped increase our response yield.<sup>31,32</sup>

## Conclusions

This study represents the first known investigation into specific treatment usage by chiropractors on their pregnant patients. The chiropractors who responded appear to employ many different treatment techniques and modalities on their pregnant patients, many at a frequency similar to those reportedly used on non-pregnant patients. It is recommended that future studies employ a larger sample and include a larger population of chiropractors to obtain a representative sample of the profession and also investigate the stages of pregnancy that different interventions are employed. Further research into the utilization, safety, and effectiveness of chiropractic care during the pregnancy and post-partum periods is still necessary.

## References

1. Borggren CL. Pregnancy and chiropractic: a narrative review of the literature. *J Chiropr Med.* 2007; 6: 70-74.
2. Christensen MG, Kollasch MW. *Job Analysis of Chiropractic.* Greeley: National Board of Chiropractic Examiners, 2005.
3. Bjorklund K, Bergstrom S. Is pelvic pain in pregnancy welfare compliant? *Acta Obstet Gynecol Scand.* 2000; 79: 24-30.
4. Phillips CJ, Meyer JJ. Chiropractic care, including craniosacral therapy, during pregnancy: a static-group comparison of obstetric interventions during labor and delivery. *J Manip Physiol Ther.* 1995; 18: 525-529.
5. Stuber KJ, Smith DL. Chiropractic treatment of pregnancy-related low back pain: a systematic review of the evidence. *J Manip Physiol Ther.* 2008; 31(6): 447-454.
6. Khorsan R, Hawk C, Lisi AJ, Kizhakkeveettill A. *Obstet Gynecol Surv.* 2009; 64(6): 416-427.
7. Stuber K. The safety of chiropractic during pregnancy: a pilot e-mail survey of chiropractors' opinions. *Clin Chiropr.* 2007; 10: 24-35.
8. Lisi AJ. Chiropractic spinal manipulation for low back pain of pregnancy: a retrospective case series. *J Midwifery Women Health.* 2006; 51: e7-e10.
9. Stuber KJ, Wynd S, Weis CA. Adverse events from spinal manipulation in the pregnant and postpartum periods: a critical review of the literature. *Chiropr Man Ther.* 2012; 20:8.
10. Ostensen M, Forger F. Management of RA medications in pregnant patients. *Nature Reviews Rheumatology.* 2009; 5: 382-390.
11. Dillane D, Finucane BT. Local anesthetic systemic toxicity. *Can J Anesthesia.* 2010; 57: 368-380.
12. Borg-Stein J, Dugan SA, Gruber J. Musculoskeletal aspects of pregnancy. *Am J Phys Med Rehab.* 2005; 84: 180-192.
13. Mykietiuik C, Wambolt M, Pillipow T, Mallay C, Gleberzon, BJ. Technique systems used by post-1980 graduates of the Canadian Memorial Chiropractic College practicing in five Canadian provinces: a preliminary survey. *J Can Chiropr Assoc.* 2009; 53: 32-39.
14. Longo M, Grabowski M, Gleberzon B, Chappus J, Jakym C. Perceived effects of the delisting of chiropractic services from the Ontario Health Insurance Plan on practice activities: a survey of chiropractors in Toronto, Ontario. *J Can Chiropr Assoc.* 2011; 55(3): 193-203.
15. Christenson MG, Morgan DRD. *Job Analysis of Chiropractic in Canada: A Report, Survey Analysis, and Summary of the Practice of Chiropractic within Canada.* Greeley, CO: National Board of Chiropractic Examiners, 1993.
16. Fast ASD, Ducommun EJ, Friedmann LW, Bouklas T, Flowman Y. Low back pain in pregnancy. *Spine.* 1987; 12: 368-371.
17. Montoya AV OBL, Aguilar de Plata AC, Mosquera EM, Ramírez-Vélez R. Aerobic exercise during pregnancy improves health-related quality of life: a randomised trial. *J Physiother.* 2010; 56: 253-258.
18. Canadian Society for Exercise Physiology. *PARmed-x for pregnancy – Physical activity readiness medical examination.* <http://www.csep.ca/cmfiles/publications/parq/parmed-xpreg.pdf>. Accessed August 12, 2012.
19. Wolfe L, Weissgerber T. Clinical physiology of exercise in pregnancy: a literature review. *J Obstet Gynecol Can.* 2003;25:473-483.
20. Campbell MK, Mottola MF. Recreational exercise and occupational activity during pregnancy and birth weight: a case-control study. *Am J Obstet Gynecol.* 2001; 184: 404-408.
21. Stafne SN, Salvesen KA, Romundstad AR, Stuge B, Morkved S. Does regular exercise during pregnancy influence lumbopelvic pain? A randomized controlled trial. *Acta Obstet Gynecol Scand.* 2012; 91: 552-559.
22. Ladipo OA. Nutrition in pregnancy: mineral and vitamin supplements. *Am J Clin Nutr.* 2000; 72: 280-290.

23. Rooney C. Antenatal care and maternal health: how effective is it. A review of the evidence. Geneva: World Health Organization, 1992.
24. Institute of Medicine. Dietary reference intakes. Thiamin, riboflavin, niacin, vitamin B-6, folate, vitamin B-12, pantothenic acid, biotin, and choline. Washington, DC: National Academy Press (pre publication edition), 1998.
25. Department of Health, Scottish Office, Home and Health Department, Welsh Office, Department of Health and Social Services, Northern Ireland. Folic acid and the prevention of neural tube defects: report from an expert advisory group. London: Department of Health, 1992.
26. Wallingford JC UBA. Vitamin A deficiency in pregnancy, lactation, and the nursing child. In: Bauernfeind JC, ed. Vitamin A deficiency and its control. New York: Academic Press. 1986;101-152.
27. Pitki RM. Calcium metabolism in pregnancy and the perinatal period: a review. *Am J Obstet Gynecol.* 1985; 151: 99–109.
28. National Academy Press. Standing committee on the scientific evaluation of dietary reference intakes, food and nutrition board, institute of medicine. DRI: Dietary Reference Intakes for calcium, phosphorus, magnesium, vitamin D, and fluoride. Washington, DC. 1999.
29. Borders N. After the afterbirth: a critical review of postpartum health relative to method of delivery. *J Midwifery Women Health.* 2006; 51(4): 242-248.
30. Glazener CMA, Abdalla M, Stroud P, Naji S, Templeton A, It R. Postnatal maternal morbidity: Extent, causes, prevention and treatment. *Br J Obstet Gynaecol.* 1995; 102: 282-287.
31. Russell ML, Verhoef, MJ, Injeyan HS, McMorland DG. Response rates for surveys of chiropractors. *J Manip Physiol Ther.* 2004; 27(1): 43-48.
32. Edwards PJ, Roberts I, Clarke MJ, Diguseppi C, Wentz R, Kwan I, Cooper R, Felix LM, Pratap S. Methods to increase response to postal and electronic questionnaires. *Cochrane Database Syst Rev.* 2009; 8(3):MR000008.
33. Wiebe ER, Kaczorowski J, MacKay J. Why are response rates in clinician surveys declining? *Can Fam Phys.* 2012; 58: e225-228.

# Straight Back Syndrome: positive response to spinal manipulation and adjunctive therapy – A case report

Paul M. Gold, BSc(H), DC\*  
 Brianna Albright\*\*  
 Sabine Anani\*\*  
 Heather Toner, BSc (Kin)\*\*

*Straight Back Syndrome (SBS) has been recognized for over 50 years. Not to be confused with flat back syndrome in the lumbar spine, SBS patients present with an obvious loss of the thoracic kyphosis accompanied by apparent heart symptoms. The main purpose of this article is to describe a patient diagnosed with SBS, whose symptoms were successfully managed using spinal manipulative therapy as well as ancillary modalities. The use of diagnostic and laboratory tests are essential to differentially diagnose cardiac disease from SBS. Genesis and incidence of this condition is also discussed as well as roentgenometric analysis. A suggested diagnostic algorithm is presented as well.*

**KEY WORDS:** *syndrome, straight back, thoracic, kyphosis, mitral valve*

*Le syndrome du dos droit (SBS) est reconnu depuis plus de 50 ans. À ne pas confondre avec le syndrome du dos plat de la partie lombaire de la colonne vertébrale, les patients souffrant du SBS présentent une importante diminution de la cyphose dorsale accompagnée de symptômes cardiaques apparents. L'objectif principal de cet article est de décrire le diagnostic d'un patient qui souffre du SBS, et dont les symptômes ont été repérés avec succès grâce à la manipulation vertébrale ainsi que des moyens auxiliaires. L'utilisation d'un diagnostic et de tests en laboratoire sont essentiels pour différencier un diagnostic de maladie cardiaque d'un diagnostic de SBS. L'origine et l'incidence de cette maladie sont également discutées, ainsi que l'analyse radiologique chiropratique. Une proposition d'algorithme de diagnostic est également présentée.*

**MOTS CLÉS :** *syndrome, dos droit, dorsale, cyphose, valvule mitrale*

## Introduction

Straight back syndrome (SBS) is a thoracic deformity characterized by loss of the normal upper thoracic spinal kyphosis. This deformity leads to a reduced antero-posterior diameter of the chest causing a compression or “pancaking” of the heart and great vessels so as to appear enlarged. This is accompanied by a leftward displacement of the heart, resulting in cardiac murmurs<sup>1</sup>, chest pain and tracheal compression<sup>2</sup>. Mitral valve prolapse (MVP) has

been reported in 64% of patients.<sup>2</sup> Misdiagnosis of straight back syndrome as pericardial absence has also been cited.<sup>3</sup> A study investigating the relationship between SBS and MVP showed echocardiograms to be normal in 36% of patients diagnosed with SBS; however, 58% of these patients demonstrated mitral valve prolapsed.<sup>4</sup> Despite the fact that this syndrome has been recognized for over 50 years, it is not commonly considered as a differential diagnose and thus the incidence is unknown.<sup>5</sup> However, given that this

\* Private Practice / Instructor, Canadian Memorial Chiropractic College, Toronto, ON, Department of Chiropractic Therapeutics, Division of Foundational and Professional Education

\*\* Senior Interns, Canadian Memorial Chiropractic College, Toronto, ON

Address all correspondence to Dr. P. Gold, 4800 Leslie St., Suite 409, Toronto, ON. M2J 2K9, Tel. 416-492-0012

Disclaimer: No funding was received for this report. The Author has no commercial associations that might pose a conflict of interest in connection with the article.

©JCCA 2013

syndrome is often associated with heart symptoms, it is important that health care practitioners are made aware of SBS and consider it as a differential diagnosis in a patient presenting with symptoms that can appear to be cardiac in nature. This is especially true in cases of atrial septal defect which can resemble the symptom picture of SBS.<sup>6</sup> This particular study describes the case of a patient with thoracic pain, who presented to a chiropractor also with cardiac symptoms but was ultimately diagnosed with and treated for symptoms related to SBS.

### Case Report

All written consents, Research Ethics Board (CMCC) approvals were obtained from the patient prior to publishing this manuscript.

### History

A 38 year old Caucasian, non-smoking male, presented to a chiropractic clinic with complaints of intermittent left arm paresthesia and left-sided chest pain and tightness rated at 3-4/10 (0=no pain, 10=most pain) and unremitting. He also reported chronic, intermittent, daily mid-thoracic pain and tightness over the past year. Symptoms of mid-thoracic pain were verbally rated at 7/10. Shortness of breath was also reported once per month. Chronic daily fatigue has also been an issue over the past year following his recent divorce. Trauma or prior surgeries were denied. Occupational factors (sitting, computer work) aggravated his arm and chest symptoms which seemed to abate during his off-time. There did not appear to be any association between his arm pain and cervical stiffness, but his mid-thoracic and chest symptoms often occurred together.

His employment required him to work night shifts for the past six years. Between 2007 and 2009, the patient underwent a number of medical diagnostic procedures, including blood work, echocardiogram, cardiac stress test, echocardiography and electrocardiogram (ECG) which were all deemed within normal limits. He attended a walk-in clinic and was diagnosed with “thoracic strain” and was prescribed Naproxen, physiotherapy and massage therapy. Treatments were ongoing for approximately six weeks and included upper back stretches and ultrasound applied to the upper trapezius. Unfortunately, all interventions had no effect on managing his thoracic, arm or chest symptoms.

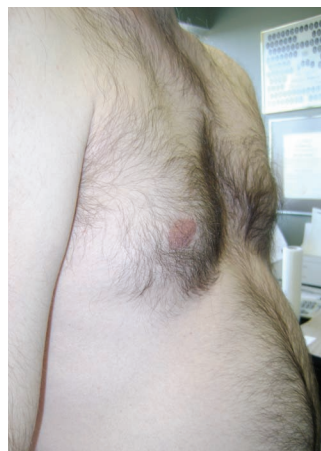

FIGURE 1:  
*pectus excavatum*

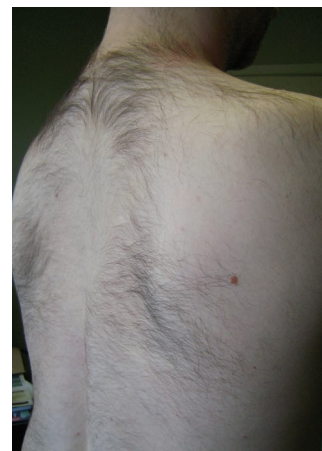

FIGURE 2:  
*loss of thoracic kyphosis*

### Social History

No family history of cardiovascular or MSK disorders was reported. He had not been taking any vitamins, minerals or nutraceuticals and reported having little time for any form of exercise as he was caring for his two young children.

### Physical Assessment / Examination

#### *a. Vitals*

Blood pressure was recorded at 118/77, pulse 71. He was 170 cm and weighed 69 kg.

#### *b. Prior Medical Testing*

A sleep study showed obstructive apnea with oxygen desaturation and sleep fragmentation. X-ray report of the cervical spine stated cervical lordotic reversal, apex at C4-5 with mild joint / foramina narrowing. The C5-6 level was similarly involved. Mild thoraco-lumbar scoliosis, convex to the right was also reported.

#### *c. Posture*

Examination showed moderate s-shaped scoliosis and anterior head carriage. He exhibited mild pectus excavatum (Figure 1). There was moderately limited but pain-free active cervical mobility with posterior joint dysfunction located at C5-6. An obvious reduction of the thoracic kyphosis (Figure 2) was noted. There was reduced bulk of the rhomboid muscles bilaterally resulting in a concave-

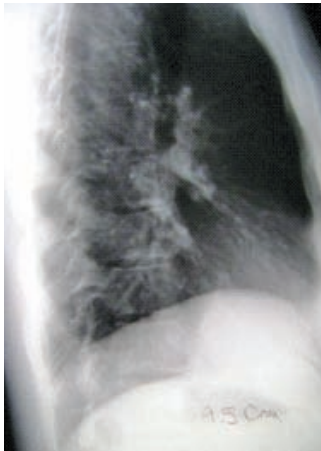


FIGURE 3: lateral chest film showing thoracic spine flattening with a 9.5 cm antero-posterior measurement (T8 to posterior sternum)

appearing upper thoracic spine. Active left and right lateral flexion of the thoracic spine showed an obvious loss of global movement throughout, with focal mobility at the T8-9 region only (“bent-stick” motion pattern: absence of segmental lateral flexion above and below an apex at T8-9).

#### d. Palpation

Rhomboid and levator scapulae muscles were reduced in girth, palpably rosy, taut and tender. Deep palpation of the latter provoked local and referred pain into the upper border of the trapezius. Motion and static palpation revealed severe loss of thoracic zygapophyseal/joint function from T1-9. Exquisite tenderness was also noted with posterior-anterior facet challenge at these levels. No referral was elicited on para-spinal examination. Costo-vertebral articulations were limited in their “bucket handle”<sup>7</sup> movement in this region with focal pain on direct palpation of the non-articulating tubercle of the first rib.

#### e. Orthopedic Testing

All orthopedic tests including Kemp’s, cervical compression, thoracic compression and thoracic outlet provocation were unremarkable.<sup>8</sup> Neurologically, no obvious motor changes were seen in the upper extremities; however there was loss of sensation over the right C5 dermatome at the deltoid tuberosity.

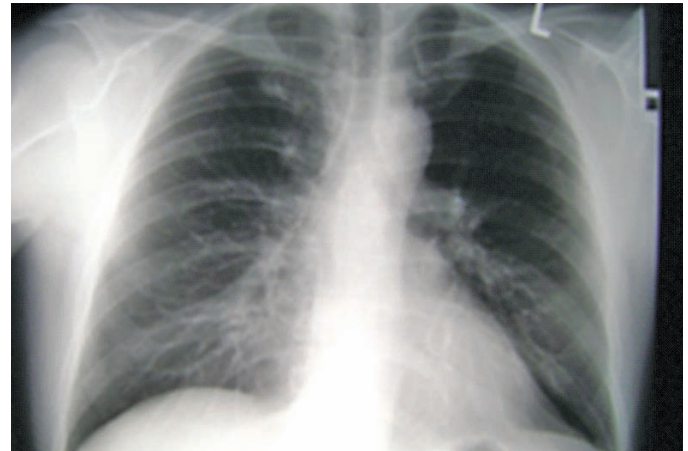


FIGURE 4: Normal AP chest; no evidence of heart pancaking in the patient

#### Current Radiographic Assessment

Suspicion of SBS following initial physical examination led to chest and thoracic x-ray examination. It confirmed the moderate, s-shaped scoliosis. There was obvious loss of thoracic kyphosis (Figure 3). Chest AP was unremarkable for heart silhouette widening/pancaking (Figure 4). There are a number of roentgenometric procedures that have been used to determine the degree of thoracic kyphosis and alteration of the retro-sternal and retro-cardiac spaces. The method chosen in this case was documented by Davies<sup>1</sup>, whereby a measurement is made from the anterior body of T8 to the posterior aspect of the sternum. The range of normal thoracic kyphosis varied from 12.68cm to 13.59cm. When reduced values are noted, the “straight back” nomenclature is applied. A second method used involves measuring the horizontal distance from T8 to a vertical line connecting T4 to T12.<sup>1</sup> AP values measured in the lateral chest projection were 9.5cm and therefore the SBS diagnosis was confirmed. (Figure 3).

#### Management

The patient was diagnosed with chronic, idiopathic SBS. Treatment focused on symptomatic relief of chest tightness and constant thoracic symptoms. A pre-modulated bipolar electrotherapeutic current (80-120hz) was applied to the rhomboids and upper trapezius muscles. Spinal manipulative therapy from T3-8 was performed in a supine manner (Anterior Thoracic procedure)<sup>7</sup> for a period of 8

weeks, 2-3 times per week (total of 18 visits), followed by a simple, active pectoralis muscle stretch involving shoulder extension with scapular retraction (3 sets of 20 sec. inter-scapular contraction, 10 sec. rest). The patient was instructed to perform this 3 times per day to improve flexibility.

## Results

The patient experienced considerable reduction of symptoms at the 6 week mark monitored using the Vernon – Mior neck pain / disability scale and Rolland Morris inventory. Values dropped from a rating of 8 to 2 and from 12 to 1 respectively. Absence of anterior chest pain was noted with reported reduction of thoracic stiffness rating of 7/10 to 2/10. Arm symptoms became less frequent (daily report to twice monthly) but upper trapezius tightness remained, requiring continued manipulation to the upper thoracic spine. Follow-up reporting at 6 months and re-examination at 23 months post treatment confirmed continued absence of chest symptoms including tightness, pain and shortness of breath.

## Discussion

A review of the literature was conducted using search words: straight back syndrome, flat back syndrome, mitral valve prolapse using EBSCO, MEDLINE and Index to Chiropractic Literature data bases. Fifteen relevant articles were found, none more recent than 2007, the majority of which were published at least 20 years ago.

Rawlings<sup>9</sup> first proposed the straight back syndrome (SBS) in 1960 in the American Journal of Cardiology and described it as the absence of the normal dorsal curvature in the thoracic part of the spine resulting in the reduced antero-posterior diameter of the thorax. At that time, it was considered a form of ‘pseudo-heart disease’ but current perspective is more often associated with valvular heart disease.<sup>10</sup>

Diagnosis of straight back syndrome has changed slightly over the years. In 1956 De Leon et al.<sup>4</sup> first proposed the diagnostic criteria as follows: the antero-posterior diameter “a” is defined as the distance from the anterior border of T8 to the posterior border of the sternum on the lateral radiograph and the lateral diameter “b” is defined at the level of the diaphragm on the frontal radiograph. SBS is diagnosed when a/b is 1/3 or less.

In 1980, Davies et al.<sup>1</sup> modified the diagnostic criteria

to evaluate a larger proportion of the chest diameter. They proposed that the lateral chest radiograph should be used to measure the distance, ‘a’ from the middle of the anterior border of T8 to a vertical line connecting T4 (top of anterior border) and T12 (bottom of anterior border). SBS is diagnosed when ‘distance a’ is smaller than 1.2cm.

As in Datey<sup>15</sup>, the 2006 diagnostic criteria used by Yochum and Rowe<sup>11</sup>, includes a lateral chest projection is taken and the distance between the posterior sternum and the anterior surface of the T8 body is measured. A measured average saggital diameter of less than 13cm in males and less than 11cm in females may indicate the presence of SBS. It is important to ensure that SBS is not confused with *flat back syndrome*, which is defined as the loss of the normal lordotic curvature of the lumbar spine most commonly associated with spinal fusion surgery.<sup>12</sup> Above all, it may be important for all health practitioners to consider SBS as a differential diagnosis for patients presenting with a chest complaint and to understand that such presentations are not always cardiovascular in nature. We have proposed a diagnostic algorithm (appendix 1) to heighten clinicians’ awareness to this syndrome. Such yellow flags that are illustrated include: decreased antero-posterior chest dimensions, pectus excavatum and straightening of the thoracic spine. X-ray finding may include a pancaking cardiac silhouette appearing as cardiomegaly and prominence of the pulmonary artery.

There is much debate as to the etiology of straight back syndrome. It has been suggested that it is an autosomal dominant condition and antigenic determinants may be located on chromosome 6.<sup>1</sup> Though it had previously been suggested that the deformity occurs in intrauterine life, making it a congenital condition<sup>13</sup>, other recent discussions tends to support that straight back syndrome may be a postnatal acquired condition<sup>5</sup>. Present literature remains unclear as to the cause of this syndrome.

Straight back syndrome usually comes to attention due to systolic cardiac murmurs detected during routine examination.<sup>3</sup> However, this is not always the case. In one study, half the patients diagnosed with SBS were asymptomatic<sup>3</sup>; therefore it is not plausible to only rely on incidentally found systolic cardiac murmurs for the diagnosis of this syndrome. Other common cardiac findings associated with SBS are: pulmonic ejection murmurs, palpable left para-sternal systolic impulses, loud delayed sounds of tricuspid valve closure, and exaggerated respiratory split-

ting of the second heart sound.<sup>11</sup> Palpitations and chest pain may be noted.<sup>14</sup> In some rare cases, SBS has been associated with tracheal compression and respiratory failure.<sup>5,14</sup> These symptoms are thought to be caused by compression of the heart and great vessels.<sup>5</sup>

Upon radiographic examination of patients with SBS, the PA chest view may demonstrate an unusual downward angulation of the anterior rib ends and the heart may appear displaced toward the left and appear enlarged.<sup>11</sup> However, the most significant and diagnostic finding is thought to be the straightening of the dorsal spine, visible on inspection, which is thereafter confirmed by palpation and a lateral radiograph of the thoracic spine which can be evaluated using the diagnostic criteria elaborated by Yochum and Rowe.<sup>10,14</sup> Electrocardiogram is normal in most cases, solidifying that SBS is not an actual organic cardiac complaint but rather a pseudoheart condition.<sup>9</sup> In one study, echocardiograms were normal in 36% and abnormal in 64% of patients.<sup>4</sup>

As previously stated, straight back syndrome has been associated with valvular defects. One study showed a strong association between SBS and mitral valve prolapse. In this study, 58% of patients with SBS were found to also have mitral valve prolapse (MVP).<sup>10</sup> Davies et al.<sup>1</sup> found that 67% of subjects with SBS had clinical or echocardiographic evidence of mitral valve prolapse while only 17.5% of subjects without SBS had evidence MVP. Muraki et al.<sup>15</sup> studied the mechanism responsible for mitral valve prolapse in patients with SBS and concluded that antero-posterior flattening of the left ventricle predisposes to asynchronous motion of the papillary muscles at end-systole, causing leaflet malcoaptation (malalignment) resulting in mitral regurgitation. In contrast, Chen et al.<sup>13</sup> found that straight back syndrome does not increase the familial occurrence of mitral valve prolapse. They postulated that both SBS and MVP might be features of a more generalized disorder. These two features may occur together in the same individual or they may be dissociated. This evidence shows that though not all patients presenting with straight back syndrome have mitral valve prolapse, there is, however, an increased chance of its presence. Therefore, in the interest of caution, some authors suggest patients be investigated for associated mitral valve prolapse if a diagnosis of SBS is suspected.<sup>1, 10</sup> Even if complicated with MVP, specific treatment for SBS is generally not required.<sup>5</sup> Others, like Yochum and Albers<sup>16</sup>

contend that the clinicians' familiarity with this syndrome could prevent unnecessary and expensive testing as well as having the psychological benefit to the patient that they do not have organic heart disease.

## Summary

This manuscript described the successful management of a patient with musculoskeletal symptoms related to SBS. Although SBS has gained increased recognition since its initial reporting by Rawlings in 1960, further research is still required in order to comprehend the scope of this syndrome and to guide health practitioners towards its proper diagnosis and, in some cases, management of its associated musculoskeletal issues. Further studies will help provide a greater understanding and appreciation of its overall incidence as well as its correlation with MVP. The incidence of SBS is unknown owing partially to its under-diagnosis within the clinical realm. As successfully shown in this case study, patients with SBS may not require any form of invasive treatment and often benefit from conservative care for symptomatic relief. Here, it consisted of chiropractic manipulative therapy, soft tissue treatment, and active exercise. Above all, it is important for the chiropractic practitioner to rule out cardiogenic causes by way of medical referral prior to any treatment regimen for patients presenting with a chest complaint.

## Acknowledgement

I would like to thank Dr. Brian Gleberzon for his tireless assistance with editing / proof reading and Dr. William Hsu for performing the roentgenometric analysis.

## References

1. Davies MK, Mackintosh P, Cayton RM, Page AJF, Shiu MF, Littler WA. The straight back syndrome. *Q J Med.* 1980;49: 443-460.
2. Grillo HC, Wright CD, Darteville PG, Wain JC, Murakami S. Tracheal compression caused by straight back syndrome, chest wall deformity, and anterior spinal displacement: techniques for relief. *Ann Thorac Surg.* 2005; 80:2057-2062.
3. Ostovan MA, Mollazadeh R. Congenital absence of pericardium and straight back syndrome: do they have similarities? *The Internet J Cardiol.* 2007; 4:834.
4. De Leon Jr AC, Perloff JK, Twigg H, Majd M. The straight back syndrome – clinical cardiovascular manifestations. *Circulation.* 1965; 32:193-203.

5. Kambe M. Straight back syndrome and respiratory failure. *Japan Med Assoc J.* 2006; 49: 176-179.
6. Serrato M, Kezdi P. Absence of the physiologic dorsal kyphosis, cardiac signs and hemodynamic manifestations. *Ann Internal Med.* 1963;6:938-945.
7. Gleberzon B, Ross K. *Manual of Diversified Diagnostic and Therapeutic Procedures* Canadian Memorial Chiropractic College. 2007; 34-45. (Self published).
8. Magee DJ. *Orthopedic Physical Assessment.* 5<sup>th</sup> Edition. Saunders, 2008; 163-7.
9. Rawlings MS. The straight back syndrome: a new case of pseudoheart disease. *Am J Cardiol.* 1960; 5: 333-338.
10. Ansari A. The “straight back” syndrome: current perspective more often associated with valvular heart disease than pseudoheart disease: a prospective clinical, electrocardiographic, roentgenographic, and echographic study of 50 patients. *Clinical Cardiology.* 1985; 8: 290-305.
11. Yochum TR, Rowe LJ. *Essentials of Skeletal Radiology.* 3rd Edition. Vol. 1. Philadelphia: Lippincott/Williams & Wilkins, 2000; 215-6.
12. Wiggins GC, Ondra SL, Shaffrey CI. Management of iatrogenic flat-back syndrome. *Neurosurgical Focus.* 2003; 15: 15 (3).
13. Chen WWC, Chan FL, Wong PHC, Chow JFS. Familial occurrence of mitral valve prolapse: Is this related to the straight back syndrome? *Br Heart J.* 1983; 50:97-100.
14. Grillo HC, Wright CD, Darteville PG, Wain JC, Murakami S. Tracheal compression caused by straight back syndrome, chest wall deformity, and anterior spinal displacement: techniques for relief. *Ann Thoracic Surg.* 2005; 80:2057-62.
15. Datey KK, Deshmukh MM, Engineer SD, Dalvi CP. Straight back syndrome. *Br Heart J.* 1964; 26: 614-619.
16. Yochum TR, Albers VL. The straight back syndrome. *ACA J Chiro.* 1982; 9: 62-64.



**Appendix 1: Diagnostic Algorithm comparing mitral Valve prolapsed to Straight Back Syndrome**

**----- Probable Diagnosis: Straight Back Syndrome (SBS)**

**———— Probable Diagnosis: Mitral Valve Prolapse**

**PRESENTING SYMPTOMS**  
 --Chest, arm pain, dorsalgia  
 -Occasional respiratory complaint

**PHYSICAL ASSESSMENT**

**OBSERVATION**  
 -Decreased antero-posterior chest dimensions  
 -Pectus Excavatum  
 -Low body weight  
 -Straightening of the spine

**PALPATION/AUSCULTATION**  
 -Palpable pulmonary artery pulsation  
 -Ejection systolic murmurs in pulmonic area  
 -Palpable impulse in left lower sternal border  
 -Accentuation and delay in tricuspid valve closure  
 -Exaggerated inspiratory splitting of the second heart sound  
 -Increase in amplitude of aortic and pulmonary closure.  
 -May or may not reveal a cardiac murmur.

**OBSERVATION**  
 -Asthenic body habitus  
 -Low body weight or body mass index (BMI)  
 -Straight-back (thoracic)  
 -Scoliosis or kyphosis  
 -Pectus excavatum  
 -Hypermobility (articular)  
 -Marfan, Ehlers-Danlos syndromes

**AUSCULTATION**  
 -Mid-to-late systolic click  
 -May or may not be followed by a high-pitched, mid-to-late systolic murmur at the cardiac apex.  
 -Valsalva maneuver results in an early click close to S1 and a prolonged murmur  
 -In the supine position, especially with the legs raised for increased venous return, left ventricular diastolic volume is increased, resulting in a click later in systole and a shortened murmur

**REPORTED SYMPTOMS**  
 -Symptoms of autonomic dysfunction: easy fatigability, dizziness, and atypical chest pain

**SPECIAL IMAGING**

**CHEST X-RAY**

-Pancake appearance simulating cardiomegaly  
 -Low position of heart  
 -Prominence of the main pulmonary artery  
 -A measured saggital dimension of <13cm in males and <11cm in females may indicate the presence of straight back syndrome

-Heart size is increased  
 -Leaflets are hypertrophied

**ECG**

-May be negative  
 -Right bundle branch block in V<sub>1</sub> and small terminal r waves in aV<sub>R</sub> lead.

**ECHO**

-Usually normal

- ECHO is the gold standard for cardiac pathology including MVP  
 -Thickening of the mitral leaflets >5 mm and leaflet displacement >2 mm indicates classic mitral valve prolapse

-Usually normal  
 -Can show nonspecific ST-segment and T-wave abnormalities especially in leads II, III, & aVF.

# Myxopapillary ependymoma as a cause of back pain in a young male – A case report

Trung P Ngo<sup>1</sup>, BSc, DC  
 John Dufton<sup>1,2</sup>, DC, MSc, MD  
 Paula J Stern<sup>1</sup>, BSc, DC, FCCS(C)  
 Omar Islam<sup>2</sup>, MD, FRCPC, DABR

**Objective:** *Primary spinal cord tumours are rare causes of low back pain but can be a significant cause of morbidity if undiagnosed and untreated. The following is a case of a young male patient presenting with low back pain and radicular symptoms caused by myxopapillary ependymoma.*

**Clinical Features:** *A nineteen year old male presented to an orthopaedic surgeon with a long history of back pain. He was initially diagnosed with soft tissue injuries and discharged. He began to experience erectile and bowel dysfunction two years later and was re-referred to the orthopaedic surgeon by his family physician but was lost to follow-up. The patient did not present to the surgeon until two years after his symptom profile changed. At that point, MRI examinations revealed a large myxopapillary ependymoma extending from T12 to L4 that was confirmed by a pathologist.*

**Intervention and Outcome:** *The tumour was surgically resected with subsequent adjuvant radiotherapy. After one year, the patient required continued catheterization and had poor anal tone. His back and leg complaints were almost normal. Follow-up MRI examinations revealed no disease progression or new spinal lesions at 4 years after the initial diagnosis.*

**Conclusion:** *The clinical presentation of primary spinal cord tumours is non-specific and can easily be missed. In cases of chronic back pain, signs and*

**Objectif :** *Les tumeurs primaires de la moelle épinière sont des causes rares de lombalgies, mais peuvent être une importante cause de morbidité si elles sont pas diagnostiquées ni traitées. Le cas suivant concerne un jeune homme qui présente une lombalgie et des symptômes radiculaires causés par un épendymome myxopapillaire.*

**Caractéristiques cliniques :** *Un homme de dix-neuf ans s'est présenté chez un chirurgien orthopédique avec de longs antécédents de douleur dorsale. Il lui a d'abord diagnostiqué des blessures des tissus mous et il a été libéré par la suite. Deux ans après, il a commencé à souffrir de dysfonctionnement érectile et intestinal et a été renvoyé vers le chirurgien orthopédique par le médecin de famille mais a été perdu au suivi. Le patient s'est présenté au chirurgien deux ans après que son profil de symptôme a changé. À ce moment-là, les examens par IRM ont révélés un épendymome myxopapillaire se prolongeant de T12 à L4, confirmé par un pathologiste.*

**Intervention et résultat :** *La tumeur a été prélevée chirurgicalement à l'aide d'une radiothérapie adjuvante subséquente. Après un an, le patient avait besoin d'un cathétérisme continu et présentait un tonus anal faible. Il ne se plaignait presque plus de douleurs au dos et aux jambes. Les examens de suivi par IRM n'ont pas révélé de progression de la maladie ou de nouvelles lésions de la moelle épinière, quatre ans après le diagnostic initial.*

**Conclusion :** *La présentation clinique de tumeurs primaires de la moelle épinière n'est pas spécifique et peut facilement ne pas être repérée. Dans les cas de*

<sup>1</sup>Canadian Memorial Chiropractic College, Toronto, Ontario, Canada

<sup>2</sup> Department of Diagnostic Radiology, Kingston General Hospital, Queen's University, Kingston, Ontario, Canada

Corresponding author: Trung P Ngo, Graduate Student, Clinical Sciences, Canadian Memorial Chiropractic College, 6100 Leslie Street, Toronto, Ontario M2H 3J1. Phone: (416) 482-2340 ext. 208. Email: trungptngo@gmail.com

Conflict of interest: none

©JCCA 2013

*symptoms should be regularly monitored for changes indicative of progressive neurological compromise such as sensory, motor and bowel/bladder dysfunction. If there is deterioration of clinical signs and symptoms, a spinal tumour should be considered in the list of differential diagnoses. Delayed diagnosis and treatment of these rare causes of back pain could lead to poor outcomes; therefore, a referral to a surgeon should be done immediately with proper follow up to ensure continuity of care.*

**KEY WORDS:** Spinal cord tumour, ependymoma, back pain, case reports

*douleurs dorsales chroniques, les signes et symptômes devraient être contrôlés régulièrement dans le cas de changements indiquant des troubles neurologiques progressifs tels que les dysfonctionnements sensoriels, moteurs, intestinaux et érectiles. Dans le cas de dégradation des signes et symptômes cliniques, une tumeur de la moelle épinière devrait être considérée parmi les diagnostics différentiels. Un diagnostic tardif et un traitement de ces causes rares de douleur dorsale peut mener à de pauvres résultats; et un renvoi chez un chirurgien devrait par conséquent être effectué dans les plus brefs délais avec un suivi approprié pour assurer la continuité des soins.*

**MOTS CLÉS :** Tumeurs de la moelle épinière, épendymome, dorsalgie, études de cas

## Introduction

Low back pain caused by neoplasia accounts for less than 1% of cases of back pain<sup>1</sup> but can be a significant cause of morbidity if undiagnosed and untreated. Primary spinal cord tumours represent approximately 15% of all neoplasms of the central nervous system (CNS).<sup>2,3</sup> These tumours pose a diagnostic challenge for practitioners since the symptoms are often non-specific with the most common initial symptom being pain.<sup>3</sup>

Spinal cord tumours are classified according to their anatomical location and are separated into three broad categories: intramedullary, intradural extramedullary, and extradural.<sup>2</sup> Intramedullary tumours are predominantly gliomas (astrocytomas and ependymomas), extramedullary tumours are most commonly peripheral nerve sheath tumours or meningiomas, and extradural lesions are usually metastatic. The most common primary spinal cord tumour in adults is ependymoma.<sup>4,5</sup>

Spinal cord tumours can significantly compress and displace the spinal cord, nerve roots or surrounding structures, impacting the neurologic status.<sup>3</sup> Therefore, early recognition of the signs and symptoms of primary spinal cord tumours allows for early treatment, potentially minimizing neurologic morbidity and improving outcome. The following is a case of a young male patient presenting with low back pain and radicular symptoms caused by myxopapillary ependymoma.

## Case History

A 19 year old male student presented to an orthopaedic surgeon with complaints of a 3 year history of back pain. He was referred to the surgeon by the family physician. He attributed the onset to being unexpectedly struck in the kidney area, after which he had ongoing recurring back pain. He was physically active but noted increasing pain in his lower back with some vague radicular discomfort into his proximal thighs more towards the end of the day. Systems review was unremarkable. His lumbar spine range of motion was slightly restricted in forward flexion with a mild list to the right. Straight leg raising was to 90° bilaterally with no evidence of nerve root tension signs. Sacroiliac and hip joint dysfunction tests were negative. On neurological examination of the lower limbs, deep tendon reflexes were 3+ but symmetric, his muscle strength was graded 5/5 and he had normal sensation. Palpation revealed L4/5 and L5/S1 local tenderness.

Conventional radiographs and a CT scan showed a spina bifida occulta of S1 but no pathology that would account for his symptomatology. The patient was diagnosed with soft tissue injuries and prescribed NSAIDs and analgesics to be taken on an as needed basis and discharged with no further follow-up scheduled.

Approximately one year later he visited his family physician because he needed a form to be filled out for a motor vehicle accident. When he was asked about his

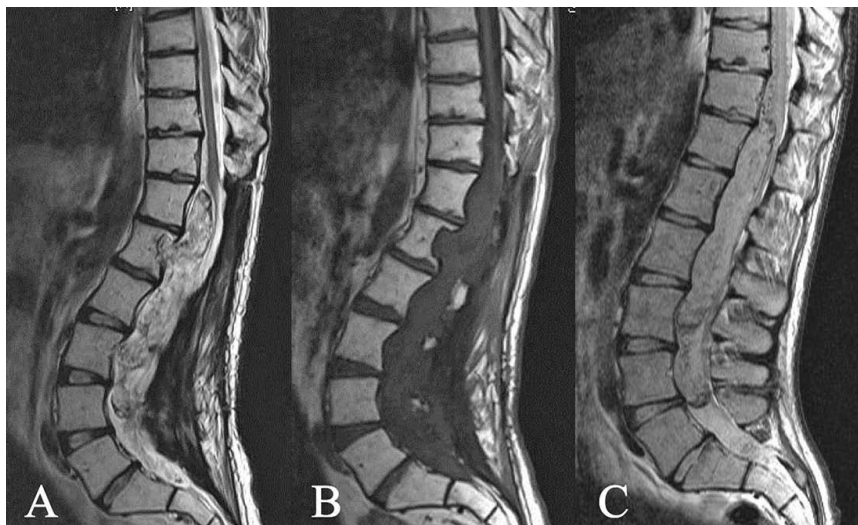


Figure 1: Magnetic Resonance Imaging Mid-Sagittal Lumbar Spine (A) Hyperintense intradural spinal canal mass noted on T2-weighted MRI; (B) The mass was hypointense on T1-weighted MRI and showed avid enhancement (C). Both images demonstrate that the upper extent of the mass is inseparable from the distal spinal cord with a large exophytic component. The spinal canal is expanded with posterior vertebral body scalloping extending from T12 to L4. Intra- and extra-lesional flow voids represent hypervascularity at the upper aspect of the mass surrounding the distal spinal cord.

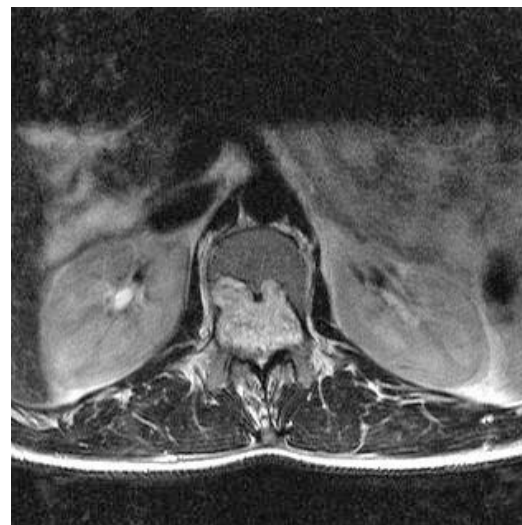


Figure 2: Axial Magnetic Resonance Image Lumbar Spine T2-weighted MRI showing the erosion of the L1 vertebral body

low back pain, he stated that it was episodic but was not troubling him that much overall since he was managing with home exercises, and Diclofenac (Voltaren).

Another year later, at the age of 21, the patient returned to his family physician with similar episodic low back pain, but at this time reported intermittent erectile dysfunction and subjectively stated that he needed to bear down harder in order to have a bowel movement. At this point, he was re-referred to the orthopaedic surgeon; however, he did not follow up with the surgical consultation.

Another two years had elapsed before the patient returned to his family physician for reasons unrelated to his back pain (he had recently broken-up with his partner and was going through a custody battle and experiencing depression). At this point, he was 23 years old. When asked about his low back and the surgical consultation, he stated that he was never contacted by the orthopedic clinic and did not think much about it. He reported that he continued

to experience the erectile and bowel dysfunction so was again referred to the orthopaedic surgeon.

Four months later, the patient was seen by the orthopaedic surgeon. At this consultation, he presented with back pain radiating into his legs with weakness and numbness in his legs and bowel, bladder and erectile dysfunction. He ambulated independently with a limp. His deep tendon reflexes were absent bilaterally whereas they were 3+ four years earlier. The remainder of the physical examination was unremarkable. An MRI examination revealed a large heterogenous, T1 hypointense, T2 hyperintense, enhancing spinal canal mass that invaded multiple neural foramina bilaterally and eroded the posterior one third of the L1 vertebral body. There was posterior vertebral body scalloping extending from T12 to L4 with expansion of the spinal canal (Figures 1 and 2). Pathologic examination confirmed a neuroepithelial neoplasm, favouring myxopapillary ependymoma.

An orthopaedic surgeon and neurosurgeon performed a conjoint procedure that involved T12 to S2 laminectomies, excision of the intradural spinal tumour and a spinal duraplasty. Adjuvant radiotherapy was recommended since the tumour could not be completely resected. Initially post surgery, he had significant bowel, bladder and erectile dysfunction. After one year, he still needed catheterization and had poor anal tone but his back and leg complaints were almost totally alleviated. Multiple bi-yearly follow-up MRI examinations revealed marrow changes secondary to radiation therapy. At 4 years after his initial diagnosis, the most recent post-operative MRI examinations revealed no disease progression or new spinal lesions.

## Discussion

Spinal ependymal tumours are glial tumours derived from ependymal cells in the spinal cord and represent 40-60% of primary spinal cord tumours.<sup>6-8</sup> The myxopapillary subtype of ependymomas (MPE) occurs mostly in the thoracolumbar region and is the most common form of ependymoma in the lumbar spine<sup>4,8-10</sup>, accounting for 13% of all spinal ependymomas and 90% of tumours in the conus medullaris<sup>4-10</sup>. It is considered a benign tumour since it is usually encapsulated and anatomically isolated from direct access to lymphatic or other routes of dissemination.<sup>7</sup> The key pathological characteristics of MPE are mucinous degeneration within the vascular connective tissue cores of papillary tumours.<sup>11</sup>

MPE usually occurs in the adult population in the third and fourth decades of life and affect males more frequently than females.<sup>4,12,13</sup> Clinically, the most common finding is lumbar, sacral or radicular pain<sup>5,14</sup> which is often worse in the recumbent position and, thus, at night<sup>7</sup>. To a lesser extent, sensory changes, motor deficits, bladder abnormalities and impotence/ejaculation dysfunctions also occur.<sup>5,14</sup> The average duration of symptoms preceding diagnosis ranges from 13 months to 8.3 years<sup>5,12,15</sup> since they are slow growing. Differential diagnoses for MPE include other primary spinal cord tumours and metastases, or possibly disc herniation depending on the symptoms.<sup>7</sup>

Diagnosis of MPE is best accomplished with magnetic resonance imaging (MRI). MRI findings typically include an intradural mass that tends to be hypointense or isointense with the spinal cord on T1 weighted images,

hyperintense on T2 weighted images and will have intense homogenous enhancement after the administration of intravenous contrast material.<sup>4-7,11,13</sup> On average, the lesions affect 2 to 4 vertebral body levels.<sup>4-6,11,13</sup> Confirmation of the diagnosis cannot be made until the excised tumour tissues are examined pathologically.

Treatment for MPE mainly involves surgical excision of the tumour. If the capsule ruptures or the tumour is not confined to the filum terminale, the mass could infiltrate and adhere to the cauda equina and/or conus medullaris or disseminate via the cerebral spinal fluid.<sup>5,11</sup> Therefore, adjuvant radiotherapy is recommended when en bloc excision (removal of the entire tumour as one piece) cannot be accomplished.<sup>11,12</sup> However, the efficacy of radiation therapy has not been established and can result in adverse effects such as radiation myelopathy<sup>5,12</sup> and residual dysuria<sup>11</sup>. The 5-year survival rate of spinal ependymomas ranges from 57-100%<sup>12,14,15</sup> and 10-33% of patients will experience local invasion of the tumour or recurrence<sup>8,14</sup>. Metastasis is rare in MPE but there have been several reported cases.<sup>16-29</sup> A good prognosis is correlated with both a greater extent of resection<sup>5</sup> and a high preoperative functional status<sup>2</sup>. Longer symptom duration prior to treatment is correlated with poorer functional outcomes<sup>30</sup>; therefore, early detection of the tumour is also associated with a better prognosis<sup>11,30</sup>.

In the chiropractic literature, three cases of spinal ependymomas have been published in two articles.<sup>31,32</sup> One patient presented with chronic (six months duration) back pain whereas the other two presented with acute exacerbations of back pain. The clinical presentations were variable but each had an unusual characteristic: one had atrophy and weakness of the left hand; the second had bowel and bladder dysfunction; and the third experienced a disproportionate amount of pain relative to the mechanism of his injury. Ependymomas in the cervical spine (in the first case) and lumbar spine (in the latter two cases) were revealed via MRI and all cases had good outcomes after surgical excision of the tumour. The subtypes of ependymomas were not discussed in these three cases.

In the present case, it is unlikely that the initial presentation of chronic low back pain was associated with the ependymoma. It could be argued that since MPE is a slow growing tumour, it could have begun to develop at that time. However, he did not report any red flags, the physical examination did not reveal any gross abnormalities and

the conventional radiographs and CT scan were negative. Although his reflexes were 3+ in the lower extremities initially, this is not necessarily indicative of disease.<sup>33</sup> If the original low back pain was indeed of a soft tissue nature as opined by the orthopaedic surgeon, then this case reinforces the necessity to regularly re-evaluate patients for changes in signs and symptoms.

The patient's symptom profile changed between the ages of 20 and 21 when he reported erectile and bowel dysfunction to the family physician. No physical examination was performed during that visit so it cannot be determined when signs of neurological deterioration would have appeared. He was referred back to the orthopaedic surgeon but unfortunately, no appointment occurred. Treatment may have been further delayed had he not returned to the family physician for unrelated reasons 2 years later. At the time of the second surgical consultation, the patient had weakness in his legs, bowel and bladder dysfunction, erectile dysfunction and night pain. Physical findings further revealed a change from 3+ reflexes bilaterally to absent reflexes.

This delayed diagnosis perhaps contributed to his slow healing and residual bladder and anal tone dysfunction after treatment. This highlights the importance of follow-up by the primary contact provider to ensure proper management of the case. If the patient had seen the specialist closer to the time of initial symptom change, surgical resection could have been performed sooner, perhaps resulting in a better clinical outcome.

## Conclusion

Myxopapillary ependymomas are the most common primary tumours in the region of the conus medullaris and filum terminale. The clinical presentation of these tumours is non-specific with lumbar and radicular pain being the most common symptoms. In cases of chronic back pain, signs and symptoms should be regularly monitored for changes indicative of progressive neurological compromise such as sensory, motor and bowel/bladder dysfunction. If there is deterioration of clinical signs and symptoms, a spinal tumour should be considered in the list of differential diagnoses. Delayed diagnosis and treatment of these rare causes of back pain could lead to poor outcomes; therefore, a referral to a surgeon should be done immediately with proper follow up to ensure continuity of care.

## References

1. Jarvik JG, Deyo RA. Diagnostic evaluation of low back pain with emphasis on imaging. *Annals Internal Medicine*. 2002; 137:586-97.
2. Grimm S, Chamberlain MC. Adult primary spinal cord tumours. *Expert Review of Neurotherapeutics*. 2009; 9:1487-95.
3. Arnautovic K, Arnautovic A. Extramedullary intradural spinal tumours: A review of modern diagnostic and treatment options and a report of a series. *Bosnian J Basic Medical Sciences*. 2009; 9(Supplement):S40-S45.
4. Choi JY, Chang KH, Yu IK, et al. Intracranial and spinal ependymomas: Review of MR images in 61 patients. *Korean J Radiol*. 2002; 3:219-228.
5. Sakai Y, Matsuyama Y, Katayama Y, et al. Spinal myxopapillary ependymoma: Neurological deterioration in patients treated with surgery. *Spine*. 2009; 34:1619-1624.
6. Wippold FJ, Smirniotopoulos JG, Moran CJ, Suojanen JN, Vollmer DG. MR imaging of myxopapillary ependymoma: Findings and value to determine extent of tumour and its relation to intraspinal structures. *Am J Radiol*. 1995; 165:1263-67.
7. Bagley CA, Wilson S, Kothbauer KF, Bookland MJ, Epstein F, Jallo GI. Long term outcomes following surgical resection of myxopapillary ependymomas. *Neurosurg Rev*. 2009; 32:321-334.
8. Bavbek M, Altinors MN, Caner HH, Bilezikci B, Agildere M. Lumbar myxopapillary ependymoma mimicking neurofibroma. *Spinal Cord*. 2001; 39:449-452.
9. Sonneland PR, Scheithauer BW, Onofrio BM. Myxopapillary ependymoma: A clinicopathologic and immunohistochemical study of 77 cases. *Cancer*. 1985; 56:883-93.
10. Celli P, Cervoni L, Cantore G. Ependymoma of the filum terminale: Treatment and prognostic factors in a series of 2 cases. *Acta Neurochir*. 1993; 124: 99-103.
11. Nakamura M, Ishii K, Watanabe K, et al. Long-term surgical outcomes for myxopapillary ependymomas of the cauda equine. *Spine*. 2009; 34:E756-760.
12. Volpp PB, Han K, Kagan AR, Tome M. Outcomes in treatment for intradural spinal cord ependymomas. *Int J Radiation Oncology Biol Phys*. 2007; 69:1199-1204.
13. Sun B, Wang C, Wang J, Liu A. MRI features of intramedullary spinal cord ependymomas. *J Neuroimaging*. 2003; 13:346-351.
14. Hanbali F, Fourney DR, Marmor E, et al. Spinal cord ependymoma: Radical surgical resection and outcome. *Neurosurgery*. 2002; 51:1162-74.
15. Asazuma T, Toyama Y, Suzuki N, et al. Ependymomas of the spinal cord and cauda equine: An analysis of 26 cases and a review of the literature. *Spinal Cord*. 1999; 37:753-59.
16. Friedman DP, Hollander MD. Neuroradiology case of the day. *Radiographics*. 1998; 18:794-98.

17. Patterson RH Jr, Campbell WG Jr, Parsons H. Ependymoma of the cauda equina with multiple visceral metastases. *J Neurosurg.* 1961; 18:145–150.
18. Agapitos E, Kavantzias N, Karaitianos J, Davaris P. Subcutaneous sacrococcygeal myxopapillary ependymoma: a case report. *Archives d’anatomie et de cytologie pathologiques.* 1995; 43:157–159.
19. Al Moutaery K, Aabed MY, Ojeda VJ. Cerebral and spinal cord myxopapillary ependymomas: a case report. *Pathology.* 1996; 28:373–376.
20. Helwig EB, Stern JB. Subcutaneous sacrococcygeal myxopapillary ependymoma: a clinicopathologic study of 32 cases. *Am J Clin Pathol.* 1994; 81:156–161.
21. Ilhan I, Berberoglu S, Kutluay L, Maden HA. Subcutaneous sacrococcygeal myxopapillary ependymoma. *Medical and Pediatric Oncology.* 1998; 30:81–84.
22. Kline MJ, Kays DW, Rojiani AM. Extradural myxopapillary ependymoma: report of two cases and review of the literature. *Pediatric Pathology and Laboratory Medicine.* 1996; 6:813–822.
23. Kramer GW, Rutten E, Sloof J. Subcutaneous sacrococcygeal ependymoma with inguinal lymph node metastasis. *J Neurosurg.* 1988; 68:474–477.
24. Pulitzer DR, Martin PC, Collins PC et al. Subcutaneous sacrococcygeal (“myxopapillary”) ependymal rests. *Am J Surgical Pathology.* 1988; 12:672–677.
25. Woesler B, Moskopp D, Kuchelmeister K et al. Intracranial metastasis of a spinal myxopapillary ependymoma. A case report. *Neurosurgery Review.* 1998; 21:62–65.
26. Graf M, Blaeker H, Otto HF. Extranural metastasizing ependymoma of the spinal cord. *Pathology Oncology Research.* 1999; 5:56–60.
27. Mavroudis C, Townsend JJ, Wilson CB. A metastasizing ependymoma of the cauda equine: case report. *J Neurosurg.* 1977; 47:771–775.
28. Rubinstein LJ, Logan WJ. Extranural metastases in ependymoma of the cauda equina. *J Neurol Neurosurg Psychiatry.* 1970; 33:763–770.
29. Rickert CH, Kedziora O, Gullotta F. Ependymoma of the cauda equine. *Acta Neurochir.* 1999; 141:781–2.
30. Quigley DG, Farooqi N, Pigott TJD, et al. Outcome predictors in the management of spinal cord ependymoma. *Eur Spine J.* 2007; 16:399–404.
31. O’Shaughnessy J, Bussieres A. Subtle clinical signs of a spinal cord ependymoma at the cervicothoracic level in an adult: A case report. *JCCA.* 2006; 50:244–48.
32. Lensgraf AG, Young KJ. Ependymoma of the spinal cord presenting in a chiropractic practice: 2 case studies. *J Manipulative Physiol Ther.* 2006; 29:676–81.
33. Bickley LS, Szilagy PG. *Bates’ Guide to Physical Examination and History Taking.* 8th ed. Philadelphia: Lippincott Williams & Wilkins; 2003

# Interexaminer reliability of cervical motion palpation using continuous measures and rater confidence levels

Robert Cooperstein, MA, DC\*  
Morgan Young, DC\*  
Michael Haneline, DC, MPH\*\*

*Introduction: Motion palpators usually rate the movement of each spinal level palpated, and their reliability is assessed based upon discrete paired observations. We hypothesized that asking motion palpators to identify the most fixated cervical spinal level to allow calculating reliability at the group level might be a useful alternative approach.*

*Methods: Three examiners palpated 29 asymptomatic supine participants for cervical joint hypomobility. The location of identified hypomobile sites was based on their distance from the T1 spinous process. Interexaminer concordance was estimated by calculating Intraclass Correlation Coefficient (ICC) and mean absolute differences (MAD) values, stratified by degree of examiner confidence.*

*Results: For the entire participant pool, ICC [2,1] = 0.61, judged "good." MAD=1.35 cm, corresponding to mean interexaminer differences of about 75% of one cervical vertebral level. Stratification by examiner confidence levels resulted in small subgroups with equivocal results.*

*Discussion and Conclusion: A continuous measures*

*Introduction : Généralement, la palpation évalue le mouvement de chaque niveau de la moelle épinière palpé, et sa fiabilité est évaluée sur des observations jumelées et séparées. Nous avons émis l'hypothèse que l'utilisation de la palpation afin d'identifier le niveau de la moelle épinière cervicale le moins mobile, dans le but de permettre le calcul de sa fiabilité à l'échelle du groupe pourrait être une approche alternative utile.*

*Méthodologie : Trois examinateurs ont palpé 29 participants asymptomatiques allongés atteints d'hypomobilité de l'articulation cervicale. L'emplacement de ces segments hypomobiles s'est fondé sur leurs distances par rapport à l'apophyse épineuse T1. La concordance entre les examinateurs a été estimée en calculant le coefficient de corrélation interne (ICC) et les valeurs de la différence absolue moyenne (MAD), stratifiés selon le degré de confiance de l'examineur.*

*Résultats : Pour tout le bassin de participants, ICC [2,1] = 0,61, jugé « bon ». MAD = 1,35 cm, ce qui correspond à la différence moyenne entre les examinateurs d'environ 75 % d'un segment de la colonne vertébrale. La stratification par le niveau de confiance de l'examineur a entraîné des petits sous-groupes avec des résultats équivoques.*

*Discussion et conclusion : Une méthodologie ayant recours à des mesures continues pour l'évaluation de*

\* Palmer Center for Chiropractic Research, San Jose, CA, USA

\*\* International Medical University, Kuala Lumpur, Malaysia

Research conducted at Palmer College of Chiropractic; San Jose, CA, USA

Responsible author:

Robert Cooperstein, Palmer Chiropractic College, 90 East Tasman Drive, San Jose CA 95134

408 944 6009 voice

408 944 6118 fax

Work supported exclusively by Palmer Center for Chiropractic Research

**Protection of human participants**

The methods used in this study conformed to the ethical standards of the institutional review board of the college and to the Helsinki Declaration.

©JCCA 2013



*study methodology for assessing cervical motion palpation reliability showed more examiner concordance than was usually the case in previous studies using discrete methodology.*

KEY WORDS: motion palpation, fixation, cervical spine, concordance

*la fiabilité de la palpation de la colonne vertébrale a indiqué une plus grande concordance entre les examinateurs qu'à l'accoutumée lors des précédentes études, qui utilisaient la méthodologie séparée.*

MOTS CLÉS : palpation, focalisation, colonne vertébrale, 1concordance

## Introduction

Motion palpation (MP) in one form or another is integral to most chiropractic techniques, and is found within the core curriculum at virtually every institution where manual therapy procedures are taught and practiced. Given its ubiquity and strategic importance in training programs, the intraexaminer and interexaminer reliability of MP have been extensively studied and summarized in systematic and annotated reviews.<sup>1-5</sup> In their review of 44 MP studies, Haneline et al<sup>6</sup> reported that only 8 showed high levels of reliability, and that only 2 of these 8 studies could be judged to be of high quality. MP has been found so unreliable<sup>7-9</sup> that some have controversially called for abandoning this diagnostic procedure<sup>10</sup>, while Hestbaek and Leboeuf-Yde concluded “The esteem chiropractors have for motion palpation in particular has not been substantiated by scientific data”<sup>11</sup>.

Cooperstein et al<sup>12</sup> hypothesized that the design methods of previous interexaminer MP reliability studies may not have been optimal to evaluate interexaminer agreement. All such studies, despite some differences, shared the method of analyzing agreement on a segmental basis. That is, the examiners tested and compared impressions for each spinal level considered separately.

Some of the earlier studies reported the results in terms of percentage agreement, but as Haas pointed out<sup>13</sup>, this does not correct for chance agreement. All the more recent studies have assessed concordance using the kappa statistic, which does indeed correct for chance agreement. Sim and Wright have described several factors that can influence the magnitude of kappa, including prevalence and bias, and discussed ways of interpreting the magnitude of obtained kappa values.<sup>14</sup>

Assessing agreement level by level may not reflect the conceptual model that some doctors in clinical practice use when asked to compare opinions for a specific patient

on the location of hypomobility. For example, asked to evaluate the cervical spine of a patient with a “stiff neck,” we suspect some doctors would attempt to identify the most hypomobile level in the neck. The levels they found could then be judged to be either *relatively close to or distant* from one another. Then, we could conclude the doctors had closely agreed upon, almost agreed upon, or simply disagreed about the location of the most hypomobile segment. Cooperstein et al<sup>12</sup> studied the interexaminer reliability of thoracic MP using this conceptual model and the statistical method best adapted to this type of analysis, the Intraclass Correlation Coefficient (ICC). Although the kappa statistic performs calculations on discrete paired observations, ICC performs calculations on continuous data at the group level.

Cooperstein et al<sup>12</sup> also reasoned that many participants in previous MP studies (often done using largely asymptomatic students) may have lacked a significant hypomobile location, forcing examiners to opine “fixated” or “not-fixated” at each level including cases where they were simply not sure of their findings. To take this into account, examiners in their thoracic study were asked to rate their confidence in the finding each time they palpated a participant. Then, in analyzing the results, examiner agreement could be calculated among several subsets of study participants, stratified by the degree of doctor confidence. Without stratification by doctor confidence, interexaminer reliability was “poor”: ICC[2,1] = .3110 (95% CI, 0.0458, 0.5358). In contrast, when both examiners were very confident, interexaminer agreement was “excellent”: ICC[2,1] = 0.8266 (95% CI, 0.6257, 0.9253). The objective of our present study was to apply Cooperstein’s thoracic spine methodology to the cervical spine, for which, to our knowledge, no data using continuous analysis and stratified confidence ratings have been previously reported.

## Methods

This study required and received approval from the Institutional Review Board at our college. All participants were required to provide informed written consent prior to being enrolled in the study. The participants were a convenience sample of asymptomatic chiropractic students who volunteered to participate during a technique laboratory class. Participants with reported cervical pain greater than 2/10 or intolerance to the palpation procedure for any reason were excluded. There were no other exclusion criteria. Participants (n=29) were mostly male (n=19), mean 27.1 years of age, mean weight 71.2 kg, and mean height 172.3 cm. The mean pain level was 0.8 on an 11-point numeric pain scale, as established by participant-completed questionnaires. No potential participants were excluded.

The 3 examiners used in this study were licensed chiropractors, two with more than 20 years of clinical experience and one with approximately 3 years of experience. The participants were instructed not to speak to the examiners during the examination process and were unaware of the palpatory results. The sequence of examiners was randomized for each participant by means of an (unblinded) research assistant drawing color-coded slips of paper from an envelope to prevent order effects. Each examiner was masked as to other examiners' findings.

Participants were first placed prone in order to permit a research assistant to mark the skin at the location of the T1 spinous process. Participants were then re-positioned supine to permit MP by the examiners between the C1 and C7 levels. To do so, the examiners used the lateral aspect of their index fingers to apply over-pressure at end-range to the lateral aspect of the cervical articular pillars, using a mostly posterior to anterior and somewhat lateral to medial vector. This created extension, ipsilateral lateral flexion and contralateral rotation to the side of contact. This would be described as an end-feel method of MP<sup>1,15</sup>, judging the quality of motion at end-range with pressure applied to one vertebra. The described over-pressure was equivalent to having taken each joint to end-range, left and right, as if to perform a traditional chiropractic adjustment commonly known as the modified rotary break, or more generically as the "supine proximal lateral index-transverse/articular pillar move."

After identifying the most hypomobile spinal site, the first examiner silently pointed out (by touching it) the lo-

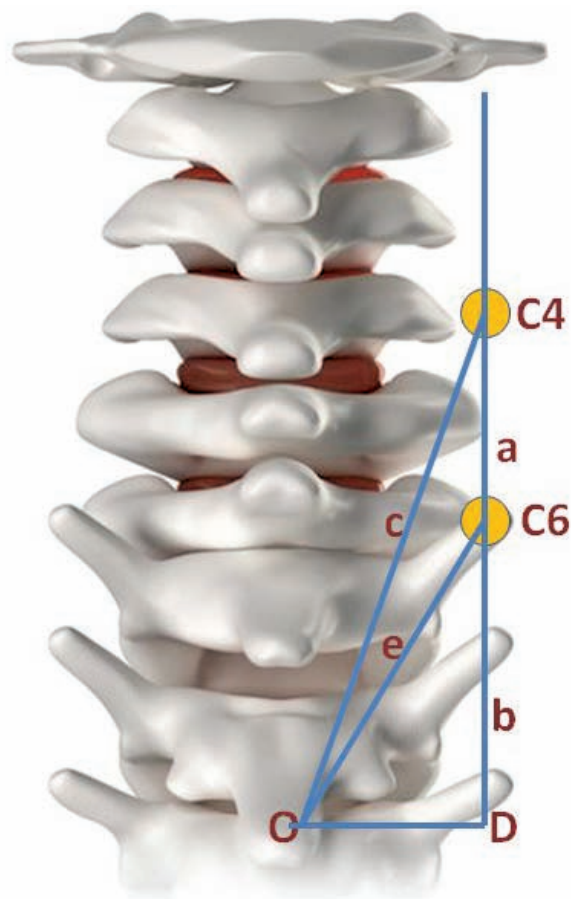


Figure 1. Method for computing the distances between the examiner's locations for hypomobility

cation to a research assistant, who placed a small adhesive backed marker on the participant's skin at the indicated location. The examiner also whispered to the research assistant whether he was "very confident" or "not confident" in the finding of hypomobility. The research assistant then recorded the distance in centimeters from this marker to the mark on the T1 spinous process with a soft measuring tape, and also recorded the examiner's confidence rating. The marker was then removed and then the second and third examiners repeated the procedure, allowing approximately 2 minutes between observations.

Figure 1 illustrates our method for computing the distances between the examiner's locations for hypomobility, using findings at C4 and C6 as an example. Having obtained the distances from the hypomobile sites identified by skin marks to the T1 spinous process, along lines O-C4

and O-C6, we used trigonometry to calculate distances a and b along the line D-C4. Line D-C4 is drawn 1.5 cm lateral to point O, based on a measurement taken from a dry spine. These calculations enabled us to transform the entire dataset of measurements taken from the spinous process of T1 to laterally situated hypomobile locations, to the actual vertical distances between examiners' findings. This heuristic calculation required three simplifying assumptions: (a) each level in the cervical spine was 1.8 cm in height<sup>16</sup> (even though vertebral height increases somewhat heading caudally); (b) the vertical length of the neck was uniform among participants; and (c) the skin marks were along a hypothetical line 1.5 cm from a hypothetical interspinous line.

We determined the spread of hypomobile findings across the range of C1-C7. We used the ICC statistic [2,1] (a two-way ANOVA model) to calculate group concordance and the root mean square error (RMSE) for all 27 analyzable participants, for all 3 examiners. We also calculated concordance among the 3 pair-wise combinations of examiners: 1&2 (n=29), 1&3 (n=27), and 2&3 (n=27). In each of the 4 datasets analyzed, the calculations were performed in three ways: for the sample as a whole (unstratified by doctor confidence), for a subset in which all examiners were confident in their findings, and for a subset in which at least one of the examiners lacked confidence. Thus, a total of 12 ICC and RMSE values were calculated. In addition, for each of these same 12 subsets we also calculated the mean absolute difference (MAD), the standard error of the mean (SEM), and 95% confidence intervals.

## Results

Although 29 participants satisfied the inclusion criteria, two data points were not recorded for examiner 3 (one failure to record the distance from T1 to the hypomobile location, and one failure to record the confidence rating). As a result, some of the interexaminer reliability and MAD calculations (involving examiners 1&2) are based on n=29, and the others (any involving examiner 3) on n=27. Likewise, the calculations based upon the entire participant pool are based on n=27. Some mild erythema was often induced during examination, but was so dispersed that each examiner's identification of the most hypomobile location was judged to have been effectively masked from the other examiners.

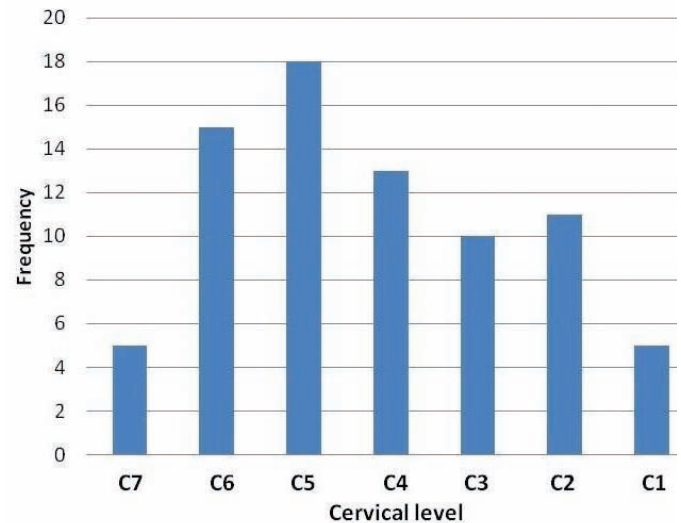


Figure 2. Approximate distribution of hypomobility findings for all examiners and all participants

Figure 2 is a histogram providing the approximate distribution of hypomobility findings for all examiners and all participants. Since the examiners did not attempt to nominate specific levels, but rather distances from a fixed point, we produced this histogram by distributing the actual measured locations into 7 bins within the C1-7 range. Since doing so required some simplifying assumptions, the histogram must be seen as a heuristic attempt to capture the results rather than representing exact numbers of findings at each segment. We assumed a uniform scale for the cervical spine with equally spaced segments; that at least one of the examiners' calls included C1; and that the vertical length of each participant's neck was uniform. Subject to these limits on interpretation, the hypomobile findings approximated a fairly smooth bell curve skewed to the left, with the peak frequency of hypomobile calls made at the approximate level of C5.

The overall agreement on side of hypomobility was 44%. For examiners 1&2 kappa= -.39, p=.09; for examiners 1&3, kappa= -.28, p=.17; and for examiners 2&3, kappa= -.19, p=.39.

The percentage of participants for which at least one examiner lacked confidence was 28%, 17%, and 11% for examiners 1, 2, and 3 respectively.

Table 1 summarizes the data for subgroups 1-4 based on examiner comparisons: (1) all examiners combined;

Table 1  
Interexaminer agreement

Set	Group description, sample size	Stratification state	Mean absolute difference	MAD 95% confidence interval		Standard error of mean	Intraclass correlation coefficient	
			MAD, cm	lower	upper	SEM	ICC	$\sigma_e$
1	All ex, n=27	non-stratified	1.35	1.12	1.57	0.12	0.61	1.22
	All ex, n=14	confident	1.13	0.88	1.39	.013	0.68	1.03
	All ex, 13	not confident	1.57	1.19	1.95	0.19	0.52	1.44
2	Ex 1&2, n=29	non-stratified	1.35	0.88	1.82	0.24	0.56	1.33
	Ex 1&2, n=16	confident	1.05	0.61	1.48	0.22	0.64	0.99
	Ex 1&2, n=13	not confident	1.72	0.85	2.59	0.44	0.50	1.70
3	Ex 1&3, n=27	non-stratified	1.28	0.96	1.60	0.17	0.68	1.10
	Ex 1&3, n=16	confident	1.47	1.06	1.88	0.21	0.57	1.19
	Ex 1&3, n=11	not confident	1.00	0.50	1.50	0.26	0.76	0.85
4	Ex 2&3, 27	non-stratified	1.38	1.82	1.73	0.18	0.60	1.19
	Ex 2&3, n=21	confident	1.23	0.81	1.61	0.20	0.67	1.10
	Ex 2&3, n=6	not confident	1.90	1.21	2.58	0.35	0.41	1.51

Ex=examiner;  $\sigma_e$  = root mean square error (RMSE), cm

(2) examiners 1&2; (3) examiners 1&3; and (4) examiners 3&4. In each subgroup, data are reported for 3 participant subsets: a non-stratified subset, a subset where all examiners were confident, and a subset where at least one examiner was not confident. The Shapiro–Wilk test was run on all subsets to confirm the populations were normally distributed prior to calculating reliability estimates.

Stratification by examiner confidence levels resulted in a series of relatively small subgroups for analysis. For the entire unstratified participant pool, ICC [2,1] = 0.61; the root mean square error (RMSE) indicated that accuracy of measurement was within 1.22 cm. The MAD in examiners' identification of the most hypomobile segment was 1.35 cm, 95% confidence interval: 1.12, 1.57 cm. Assuming an approximate 1.8 cm per cervical level<sup>16</sup>, both the RMSE and MAD calculations suggest a mean interexaminer difference of about 75% of a vertebral level, clinically equivalent to having identified the same motion segment as being hypomobile.

## Discussion

Possible explanations for the general poor reliability of

previous motion palpation studies have included poor interexaminer spinal level localization leading to possible misreported discrepancies.<sup>5,17</sup> Some investigators avoided the spinal level numeration problem by having the examiners denote particular skin marks (applied beforehand by a research assistant) to represent the level of fixation, rather than attempting to number the vertebral levels felt to be fixated. Our study avoids the numeration problem by recording the hypomobile location as a distance from a landmark rather than as a spinal level in the usual sense of the term.

Our study allowed the examiners to determine the most hypomobile cervical location and rate their findings by degree of confidence. Using the typical scale for classifying ICC values (below 0.40 = poor, 0.40-0.59 = fair, 0.60-0.74 = good, above 0.75 = excellent)<sup>14</sup>, interexaminer agreement for all participants, unstratified, was “good.” Although the ICC values obtained in the present study were somewhat lower than the highest ICC reported in the aforementioned thoracic study<sup>12</sup>, the results are generally comparable. MAD, the average of examiners' differences, was 1.35 cm, equivalent to having identified the same motion segment.

Our study was underpowered, resulting in subgroups that were exceedingly small. Thus, there was inadequate power to statistically determine significant differences in reliability among the confidence strata. Walter et al<sup>18</sup> developed a method for estimating the required sample size for ICC calculations, given the expected ICC, the lowest ICC that would be acceptable, and the number of raters. For example, using 3 examiners, had we been willing to accept ICC=0.4 (“fair”), and expecting ICC=.7 (comparable to a previous similar study<sup>12</sup>, we would have needed a sample size of 20. For comparisons using 2 examiners, the required sample size would have been n=33.

Study designs that permit analyzing continuous group data rather than discrete paired observations may provide an increased ability to discern interexaminer agreement, as does (to some degree) allowing the examiners to rate their level of confidence in their findings. The methods used in most if not all previous MP studies asked the examiners to judge each spinal level as either moving normally or being hypomobile, and analyzed the data using the kappa statistic. Judging agreement by *how near* the identified locations are to one another, as we did, may be a more subtle and clinically relevant an assessing of agreement. It may better mirror how many (but certainly not all) manual therapists detect hypomobility in typical clinical settings: the palpator examines the spine for hypomobile sites that are relatively near the area of the patient’s complaints.

Among the four dozen MP studies discussed in an annotated review of MP<sup>2</sup>, Potter et al<sup>19</sup> were one of only two groups of investigators who used a most-hypomobile-segment paradigm similar to ours, and they also used ICC for the purposes of analysis. Since theirs was an intraexaminer study, unlike ours, and furthermore considered other examination findings in addition to MP to determine agreement, we cannot directly compare the results of their study with our own. Ghokassian et al<sup>20</sup> also used a most fixated level protocol in an osteopathic study assessing the reliability of a percussive MP method developed by Johnston<sup>21</sup>. Even though they *could have* used ICC for the purposes of analysis, the investigators organized their data so as to use the kappa statistic, and doing so found negligible interexaminer agreement. When their data is reformatted so as to enable analysis using ICC, what becomes apparent is clinically relevant (although not high) agreement. Since the data in the Ghokassian

study<sup>20</sup> were presented such that they could be analyzed using either discrete or continuous statistical methods, in effect we have a direct head-to-head comparison whereby continuous analysis showed arguably more agreement than discrete analysis. An article re-analyzing this osteopathic study using continuous statistical methods is now in press.<sup>22</sup> It demonstrates that a head-to-head comparison of two measures of reliability, operating upon the same dataset, found greater reliability using continuous as compared with discrete analysis. However, this outcome may not be generalizable.

Interexaminer motion palpation studies generally assess agreement on the spinal level of hypomobility, but infrequently report the direction or side of restriction. Indeed, many by design constrain the examiners to study posterior to anterior glide only, or confine examination to one side only. In our study the overall agreement on the side of hypomobility was only 44%, although paradoxically, we found strong agreement on the spinal location of maximum hypomobility. Since the palpatory procedure involved applying mostly posterior to anterior pressure on the articular pillar and transverse process, the hard end-feel that the examiners perceived may have related more to vertebral resistance to extension (i.e., extension restriction) rather than axial rotation or lateral-to-medial translation. Under that assumption, the side contacted resulting in the judgement of extension hypomobility may have been perceptually unimportant.

We have no reason to think our results on side-specificity differ from those of other MP investigators, most of whom did not report their data on side-specificity. A cervical MP study by Cooperstein et al reported good examiner agreement on which participants in their study exhibited fixation, but not on the side.<sup>23</sup> There is some limited information available addressing cervical clinical outcomes as related to the side of intervention.<sup>24-26</sup>

Awareness seems to be growing that the kappa statistic has not been very useful in demonstrating examiner concordance in level-by-level study designs, and in fact needs to be made more useful by dint of using expanded definitions of agreement. For example, Abbot et al<sup>27</sup>, after checking each lumbar level individually for instability, collapsed the data into just 2 levels, to which they then applied kappa statistics: “For analysis of clinical examination data, both clinical and radiographic data were then collapsed into two regions, corresponding to upper lum-

bar and lower lumbar. This was decided a priori, and considered necessary because there is considerable evidence that therapists are not sufficiently accurate in identifying specific segmental levels by palpation, although they are usually within one level (up or down) and are generally reliable at locating again a segment they had previously located.” Heiderscheit et al<sup>28</sup> also realized that their prospects for finding segmental agreement using the kappa statistic was poor: “To account for potential segment level identification inaccuracies, an expanded definition of agreement was also used. Using this expanded definition, agreement with regard to the localization of findings was present if it was reproduced during the second examination session and located in the exact same spinal level or in a neighboring level ( $\pm 1$  spinal segment)”.

Our study design did not have to expand the bins to detect agreement. Examiners needed only to have been near each other in identifying the most hypomobile segment to be judged in agreement; and the closer they were, the higher the level of agreement. Our study was not designed to show that identifying the most fixated location is more clinically important than identifying a discrete level of care, nor address the clinical issues related to spinal manipulation based on any particular examination protocol. Rather, we attempted to show that examiners can be demonstrably concordant in identifying the most fixated location in the cervical spine, even though most prior cervical MP studies showed an unacceptable degree of agreement when assessing cervical motion level by level.

### *Limitations of the study*

- Although we randomized colored slips of paper to determine the order of examiners for each participant, we did not record the examiner order. This precluded determining if there were order effects based on which examiner was first, second, or third.
- The research assistant may have erred to some degree in placing the marker at the spot indicated by the examiners and in performing the measurements. In addition, the research assistant was not blinded to the examiners’ site designations.
- Since MP may alter the participant’s joint movements (either increasing or decreasing end-

range movement capability), using 3 examiners rather than the usual 2 might not have been a good design choice. It may have reduced the independence of the observations beyond what occurs using only 2 examiners.

- Lack of confidence in the examiners’ rating of the most hypomobile motion segment might have come about in 2 different ways: an examiner might not have found *any* motion segment significantly hypomobile or an examiner may have found multiple segments significantly but indistinguishably hypomobile.
- The finding that the highest ICC recorded in this study occurred in a subgroup where at least one examiner was not confident was counter-intuitive and remains unexplained. That stated, examiner confidence levels appeared to have a modest impact in the study overall.
- Our study was underpowered, resulting in subgroups that were exceedingly small. Thus, there was inadequate power to statistically determine significant differences in reliability among the confidence strata. Small sample sizes<sup>29</sup> may increase the variability of examiners’ observations.
- The study participants were largely asymptomatic, thus not reflective of symptomatic patients seeking care, jeopardizing the external validity in a manner that has been previously criticized<sup>5,11</sup>; lack of participant homogeneity<sup>30</sup> may increase variability. On the other hand there is some evidence that using more symptomatic participants does not appreciably change the outcome.<sup>31</sup>
- Without a reference standard we cannot confirm that there actually were any hypomobilities present in our study.

### **Conclusions**

The palpators in this study of cervical end-feel MP exhibited good interexaminer agreement, with findings generally within one level of each other, despite having used industry-standard methods that previous studies had found mostly unreliable. Examiner confidence levels seemed to have a modest impact on the reliability of cervical spine

MP, but the study did not have enough power to address this clearly. There may be benefits to repeating the study on a sample of symptomatic patients.

With so many previous studies having been performed in educational institutions that used mostly asymptomatic and minimally-symptomatic participants, it is not surprising that the protocol of examining the spine segment by segment became established, and propagated in clinical situations even where more symptomatic participants were available. After all, minus a significant participant complaint, a level-by-level approach may have seemed more appropriate compared with the more targeted approach we suspect is used by field doctors, who might be expected to seek the most fixated or otherwise symptomatic segment lying within the field of primary complaint. Our clinical protocol of identifying the most hypomobile level may better represent the practice of some but not all clinicians using MP.

Investigators who perform research in educational institutions often use a convenience sample of minimally symptomatic students, often a relatively small sample, usually due to research infrastructural limitations. These investigators understand it would have been better to use a larger sample of more heterogeneous participants, and know in advance their study will never achieve a high score using rating instruments like QAREL<sup>32</sup> for reliability or QUADAS<sup>33</sup> for validity studies. Institutional investigators in such circumstances do need to make it clear that their studies have limited external validity, and readers should be cautious to not over-interpret their results.

The better reliability seen in our study compared with most previous motion palpation studies is not attributable to any improvements to the end-feel palpation method, nor do they confirm a better method for identifying the most appropriate spinal site of care. We are not aware of any studies that report different outcomes for care based on examining every spinal level as compared with flagging the most relevant location within a patient's area of primary complaint. Therefore, these results do not call for clinicians to adopt new patient assessment methods or change their record-keeping protocols. They do suggest that researchers might consider designing their study protocols and research methods to explore reliability using the "most clinically relevant spinal site" protocol that some clinicians use. In fact, our results raise the possibility that the present inventory of mostly discrete

(certainly for MP) reliability studies may underestimate clinically relevant examiner agreement, thereby unduly discouraging further research and clinician interest in such research. It may be possible to repeat many other interexaminer reliability studies, including studies of examination procedures other than MP (thermography, x-ray line marking, etc.) with similar design modifications that may more meaningfully assess examiner agreement than the mostly discrete analysis that has been used up until now.

We should not allow the confidence module of this study, given that it addressed an important clinical issue, to obscure our central finding. The interexaminer reliability for all 3 examiners, and for all participants, was good.

#### Acknowledgment

We would like to thank the Palmer Center for Chiropractic Research for its support.

#### References

1. Haneline MT, Cooperstein R, Young M, Birkeland K. Spinal motion palpation: a comparison of studies that assessed intersegmental end feel vs excursion. *J Manip Physiol Ther.* 2008 Oct;31(8):616-26.
2. Haneline M, Cooperstein R, Young M, Birkeland K. An annotated bibliography of spinal motion palpation reliability studies. *J Can Chiropr Assoc.* 2009 Mar;53(1):40-58.
3. Seffinger MA, Najm WI, Mishra SI, Adams A, Dickerson VM, Murphy LS, et al. Reliability of spinal palpation for diagnosis of back and neck pain: a systematic review of the literature. *Spine.* 2004 Oct 1;29(19):E413-25.
4. Stockendahl MJ, Christensen HW, Hartvigsen J, Vach W, Haas M, Hestbaek L, et al. Manual examination of the spine: a systematic critical literature review of reproducibility. *J Manip Physiol Ther.* 2006 Jul-Aug;29(6):475-85, 85 e1-10.
5. Huijbregts PA. Spinal motion palpation: a review of reliability studies. *J Man Manip Ther.* 2002;10(1):24-39.
6. Haneline MT, Cooperstein R, Birkeland K. Spinal motion palpation: A comparison of studies that assessed intersegmental end-feel versus excursion. *J Chiropr Educ.* 2008;22(1):59-60.
7. Breen A. The reliability of palpation and other diagnostic methods. *J Manip Physiol Ther.* 1992;15(1):54-6.
8. Dishman RW. Static and dynamic components of the chiropractic subluxation complex: a literature review [see comments]. *J Manip Physiol Ther.* 1988;11(2):98-107.
9. Haas M, Panzer D, Raphael R. Reliability of manual end-play palpation of the thoracic spine. *Chiropr Tech.* 1995;7(4):120-4.

10. Troyanovich SJ, Harrison DD. Motion Palpation: It's time to accept the evidence. *J Manip Physiol Ther.* 1998;21(8):568-71.
11. Hestbaek L, Leboeuf-Yde C. Are chiropractic tests for the lumbo-pelvic spine reliable and valid? A systematic critical literature review. *J Manip Physiol Ther.* 2000;23(4):258-75.
12. Cooperstein R, Haneline M, Young M. Interexaminer reliability of thoracic motion palpation using confidence ratings and continuous analysis. *J Chiropr Med.* 2010 Sep;9(3):99-106.
13. Haas M. Statistical methodology for reliability studies. *J Manip Physiol Ther.* 1991 Feb;14(2):119-32.
14. Sim J, Wright CC. The kappa statistic in reliability studies: use, interpretation, and sample size requirements. *Phys Ther.* 2005 Mar;85(3):257-68.
15. Brown J, Cooperstein R. Why motion palpation is so confounding. *J Am Chiropr Assoc.* 2001;38(10):34-6.
16. Gilad I, Nissan M. Sagittal evaluation of elemental geometrical dimensions of human vertebrae. *J Anat.* 1985 Dec;143:115-20.
17. Billis EV, Foster NE, Wright CC. Reproducibility and repeatability: errors of three groups of physiotherapists in locating spinal levels by palpation. *Man Ther.* 2003 Nov;8(4):223-32.
18. Walter SD, Eliasziw M, Donner A. Sample size and optimal designs for reliability studies. *Stat Med.* 1998 Jan 15;17(1):101-10.
19. Potter NA, Rothstein JM. Intertester reliability for selected clinical tests of the sacroiliac joint. *Phys Ther.* 1985;65(11):1671-5.
20. Ghoukassian M, Nicholls B, McLaughlin P. Inter-examiner reliability of the Johnson [sic] and Friedman percussion scan of the thoracic spine. *J Am Osteopath Assoc.* 2001;4(1):15-20.
21. Johnston WL, Allan BR, Hendra JL, Neff DR, Rosen ME, Sills LD, et al. Interexaminer study of palpation in detecting location of spinal segmental dysfunction. *J Am Osteopath Assoc.* 1983 Jul;82(11):839-45.
22. Cooperstein R. Interexaminer reliability of the Johnston and Friedman percussion scan of the thoracic spine: secondary data analysis using modified methods. *J Chiropr Med.* 2012;11(3):154-159.
23. Cooperstein R, Gardner R, Nansel D. Concordance of two methods of motion palpation with goniometrically-assessed cervical lateral flexion asymmetry. *International Conference on Spinal Manipulation; 1991; Arlington, VA.: FCER.*
24. van Schalkwyk R, Parkin-Smith GF. A clinical trial investigating the possible effect of the supine cervical rotatory manipulation and the supine lateral break manipulation in the treatment of mechanical neck pain: a pilot study. *J Manip Physiol Ther.* 2000 Jun;23(5):324-31.
25. Cilliers KI, Penter CS. Relative effectiveness of two different approaches to adjust a fixated segment in the treatment of facet syndrome in the cervical spine. *J Neuromusculoskeletal System.* 1998;6(1):1-5.
26. Hubka MJ, Phelan SP, Delaney PM, Robertson VL. Rotary manipulation for cervical radiculopathy: observations on the importance of the direction of the thrust. *J Manip Physiol Ther.* 1997;20(9):622-7.
27. Abbott JH, McCane B, Herbison P, Moginie G, Chapple C, Hogarty T. Lumbar segmental instability: a criterion-related validity study of manual therapy assessment. *BMC Musculoskelet Disord.* 2005;6:56.
28. Heiderscheit B, Boissonnault W. Reliability of joint mobility and pain assessment of the thoracic spine and rib cage in asymptomatic individuals. *J Man Manip Ther.* 2008;16(4):210-6.
29. Bland JM, Altman DG. A note on the use of the intraclass correlation coefficient in the evaluation of agreement between two methods of measurement. *Comput Biol Med.* 1990;20(5):337-40.
30. Ekeberg OM, Bautz-Holter E, Tveita EK, Keller A, Juel NG, Brox JI. Agreement, reliability and validity in 3 shoulder questionnaires in patients with rotator cuff disease. *BMC Musculoskelet Disord.* 2008;9:68.
31. DeCamp Jr. N, editor. Objective analysis of the lumbo-sacral complex and occiput. *Sacro Occipital Research Society International Symposium; 1987; San Diego, California.*
32. Lucas NP, Macaskill P, Irwig L, Bogduk N. The development of a quality appraisal tool for studies of diagnostic reliability (QAREL). *J Clin Epidemiol.* 2010 Jan 5;63(8).
33. Whiting P, Rutjes AW, Reitsma JB, Bossuyt PM, Kleijnen J. The development of QUADAS: a tool for the quality assessment of studies of diagnostic accuracy included in systematic reviews. *BMC Med Res Methodol.* 2003 Nov 10;3:25.



# Frequency of use of diagnostic and manual therapeutic procedures of the spine currently taught at the Canadian Memorial Chiropractic College: A preliminary survey of Ontario chiropractors. Part 2 – procedure usage rates

Brian Gleberzon, DC, MHSc\*  
Kent Stuber, BSc, DC, MSc\*\*

*Objective: The purpose of this study was to determine which diagnostic and therapeutic procedures of the spine are most commonly utilized by chiropractors practicing in Ontario, based on a list of currently taught procedures at CMCC. In Part 1 of this study (published previously), the demographics and practice patterns of the respondents were presented. Part 2 of this study (presented here) reports on the utilization rates of spinal diagnostic and therapeutic procedures by the respondents.*

*Methods: The study consisted of a paper-based survey that was sent to 500 randomly selected Ontario chiropractors who responded confidentially. Survey questions inquired into demographic and practice style characteristics as well as the frequency with which spinal diagnostic and therapeutic procedures were performed.*

*Results: There were 108 respondents to the survey, giving a response rate of 22.4%. Frequency of use of diagnostic procedures fell into three broad categories: (i) those tests that are almost always performed, (ii) those tests that are almost always performed by two-*

*Objectif : Le but de cette étude était de déterminer les procédures diagnostiques et thérapeutiques de la colonne vertébrale les plus couramment utilisées par les chiropraticiens qui exercent en Ontario, en fonction d'une liste de procédures enseignées au Canadian Memorial Chiropractic College (CMCC). Dans la première partie de cette étude (publiée précédemment) les données démographiques et les habitudes de pratique des répondants ont été présentées. La deuxième partie de cette étude (décrite ici) rapporte les résultats des taux d'utilisation des procédures diagnostiques et thérapeutiques pour la colonne vertébrale utilisées par les répondants.*

*Méthodologie : L'étude a été menée par l'entremise d'un questionnaire papier envoyé à 500 chiropraticiens de l'Ontario, choisis de manière aléatoire et qui ont répondu de façon confidentielle. Les questions du sondage enquêtaient sur les données démographiques et les caractéristiques des styles de pratique ainsi que la fréquence à laquelle les procédures diagnostiques et thérapeutiques pour la colonne vertébrale sont effectuées.*

*Résultats : Il y avait 108 répondants au sondage, soit un taux de réponse de 22,4 %. La fréquence de l'utilisation de procédures diagnostiques se classe dans trois grandes catégories : (i) ces tests sont presque toujours effectués, (ii) ces tests qui sont utilisés sur deux-*

\* Professor, Chair of Department of Chiropractic Therapeutics, CMCC, 6100 Leslie St. Toronto, Ontario, M2H 3J1.  
E-mail: bgleberzon@cmcc.ca

\*\* Adjunct Professor, Division of Graduate Education & Research, Canadian Memorial Chiropractic College  
19-8 Weston Drive SW, Calgary, Alberta, T3H 5P2; kstuber@cmcc.ca, 403-685-5252.

The authors declare that there are no disclaimers or conflicts in the preparation of this manuscript.

Funding for postage for this study was provided by the Division of Graduate Education & Research, Canadian Memorial Chiropractic College  
©JCCA 2013

thirds to one-half of patients, and (iii) those tests that are virtually never used. By comparison, respondents utilized the same therapeutic procedures for patients care less consistently.

Conclusions: *Despite a low response rate, respondents reported mostly relying on static and motion palpation, joint play, neurological tests, and ranges of motion when assessing their patients. Due to a low response rate, the results of this study may not be generalizable to all Ontario chiropractors.*

KEY WORDS: chiropractors, manual therapy, physical examination, survey

## Introduction

Chiropractors are taught numerous diagnostic and therapeutic procedures during their undergraduate education and clinical internship. These procedures are principally directed towards the cervical, thoracic, lumbar and pelvic regions (the spine) and peripheral joints, although students are also taught how to assess other structures (eyes, ears, heart and so on) as well. Two previous studies sought to determine if the diagnostic and therapeutic procedures taught during the undergraduate programme at the Canadian Memorial Chiropractic College (CMCC) are required to be used by fourth year students during their internship when providing patient care under the direct supervisions of chiropractic clinicians.<sup>1,2</sup> In general, these studies reported a relatively high degree of vertical integration of procedures between the undergraduate and clinical internship with respect to the cervical, thoracic and lumbopelvic spine but a very low degree of vertical integration with respect to assessment procedures of the cranium.<sup>1,2</sup> This study took those investigations one step further by attempting to ascertain if the diagnostic and therapeutic procedures currently taught to students are subsequently utilized for patient care after graduation.

The overall purposes of this study were to: (i) characterize practice patterns and demographic information of a pseudo-random sample of Ontario chiropractors; (ii) determine which diagnostic tests of the spine and (iii) which

tiers à la moitié des patients, et (iii) ces tests qui ne sont presque jamais utilisés. En comparaison, les répondants ont utilisé les mêmes procédures thérapeutiques concernant les soins pour les patients de façon moins systématique.

Conclusion : *En dépit d'un taux de réponse faible, les répondants ont rapporté qu'ils utilisaient généralement la palpation statique et dynamique, des mobilisations d'articulation et plusieurs méthodes dynamiques lors de l'évaluation de leurs patients. En raison d'un faible taux de réponse, les résultats de cette étude ne devraient pas être généralisés à tous les chiropraticiens de l'Ontario.*

MOTS CLÉS : chiropraticiens, thérapie manuelle, examen physique, sondage

therapeutic procedures of the spine were utilized by a pseudo-randomized sample of Ontarian chiropractors as well as how often (i.e. at what frequency) they were being used. The first objective (characterization of practice patterns and demographic information) has been accepted for publication.<sup>3</sup> We present here the second and third objectives of this study; namely, which diagnostic and therapeutic procedures currently taught to chiropractic students are used by a pseudo-randomized sample of Ontario chiropractors and how often (i.e. at what frequency) these tests were being used.

## Methods

The methods employed in this study have been described in detail elsewhere<sup>3</sup>, and modelled after two previously published studies on this topic<sup>1,2</sup>. Briefly, this study received approval from the CMCC Research Ethics Board (project #112019) and funding from the CMCC Division of Graduate Education and Research. Subjects were mailed a cover sheet and consent form, a paper-based survey and an addressed postage paid envelope to return the survey. The survey consisted of demographic questions, questions regarding practice patterns, and several tables that listed and described all of the spinal diagnostic/examination procedures and manual mobilization and spinal manipulative therapies currently taught in the college's curriculum, ascertained by auditing courseware of

technique, orthopaedic and clinical diagnosis courses.<sup>4,5</sup> A six-point scale was provided for subjects to indicate the frequency with which they perform each procedure. Response options were “never used”, “rarely used”, “sometimes used”, “often used” and “almost always used” as well as “no clinical cause to use this test”. The survey was based on previous published studies on this topic by one of the authors<sup>1,2</sup>, and further pre-tested on a single independent external subject.

The surveys were distributed to a systematically pseudo-randomized sample of 500 licensed Ontario chiropractors selected from the directory of the College of Chiropractors of Ontario (CCO) (the licensing body of that province). Subjects were included if they were a practicing chiropractor registered with the CCO who was involved in patient care and signed the informed consent form for participation. Confidentiality was assured and participants could respond anonymously. Descriptive statistics were employed to determine the overall frequency with which the different procedures were performed, along with determining the results of the demographic and practice pattern questions and a response rate. The six options available to respondents used in the survey (see above) were collapsed into four categories to facilitate response pattern analysis. These categories were: ‘Never/Rarely’ (N/R) used, ‘Sometimes’ used (ST), ‘Almost Always/Often’ (AA/O) used and ‘Haven’t Had a Patient to Use it on’ (HH-P).

## Results

### Diagnostic Examination Procedures

#### *Cervical Spine (Table 1)*

All respondents (100%) reported they AA/O perform cervical ranges of motion, and almost all respondents reported they perform joint play (96.3%) and static palpation (95.4%) during examination of the cervical spine. Over 80% of respondents reported AA/O performing motion palpation (84.3%) and Kemp’s test (82.4%). Roughly half of respondents indicated they AA/O perform Cervical Compression (63%), Distraction (58.3%), Jackson’s (50.9%) and Spurling’s (46.3%) tests, while the Valsalva’s and Doorbell tests were AA/O performed by slightly less than half of respondents, although the results for these tests increase substantially if combined with

the responses from respondents who reported that they ‘sometimes’ perform them.

Conversely, over 85% of respondents reported they N/R performed Naffziger’s test. Houle’s test, a test that purportedly screens for patients at-risk of experiencing a vertebrobasilar stroke during cervical manipulation<sup>6</sup>, was never used by 70.4% of respondents. Other tests commonly N/R used included Cervical Flexion-Rotation, L’Hermitte’s, Upper Limb Tension and Soto-Hall. The Rotary Chair and Dix-Hallpike tests, used to differentially diagnose dizziness as either cervicogenic vertigo or benign paroxysmal positional vertigo (BPPV) respectively<sup>7</sup>, were both N/R used by 70.4% of respondents, with roughly 7% indicating that they never had opportunity or cause to perform these tests (see Table 1). Other tests commonly N/R used included EAST, Adson’s and Wright’s tests, used to diagnose Thoracic Outlet Syndrome as well as Kernig’s and Brudzinski’s tests, used to identify meningeal irritation.<sup>8</sup>

The majority of respondents indicated they AA/O conduct motor (85.3%), reflex (83.3%) and sensory (75%) neurological testing. However, only 10.2% indicated they AA/O perform Hoffman’s test.

#### *Thoracic Spine (Table 2)*

A high percentage of respondents reported they AA/O perform static palpation (96.2%), joint play (95.3%) and ranges of motion (93.4%) testing when assessing the thoracic spine, although only roughly two thirds perform Adam’s test. Many respondents indicated they AA/O perform a straight leg raise, motion palpation, Kemp’s, and rib springing. Other than Valsalva’s maneuver and Doorbell testing, most of the other tests on the questionnaire were never or rarely used, including Beevor’s test or Beevor’s sign, chest expansion test, Upper Limb Tension Testing, passive scapular approximation, Slump test, skin rolling, L’Hermitte’s, Soto-Hall, apparent or true leg length testing, and Kernig’s or Brudzinski’s tests. In this study, 56.1% of chiropractors reported they N/R performed chest percussion.

#### *Lumbopelvic Spine (Table 3)*

Respondents reported they AA/O perform a number of tests for the lumbopelvic spine, including static palpation (99.1%), joint play (96.3%), straight leg raise (95.3%), ranges of motion (95.3%), PSIS joint challenge (91.4%),

motion palpation (86.9%), gait analysis (85%), Kemp's (82.2%), crossed straight leg raise (79.2%), and Sacral Thrust (79%).

A number of tests were reportedly used AA/O by roughly one-half to two-thirds of the respondents, including the Patrick's FABER (Figure 4), Ely's, heel and toe walking, psoas palpation, Braggard's, Yeomans's, Hibb's, Thomas test, Valsalva's, Minor's sign, Gillet's (SI motion), tandem gait, and Bowstring's.

A number of tests were N/R used, including Schober's, Waddell's tests, FAIR, Thigh Thrust, Gaenslen's, spinous percussion, Ober's, Bowstring, Distraction, and Trendelenburg test. In this study, 61.3% of respondents never assessed lower limb pulses and 49.5% of respondents never performed abdominal percussion.

With respect to neurological testing, 90.6% of respondents indicated they AA/O performed motor testing, 84% AA/O assessed reflexes, and 74.5% assessed lower limb sensation. The plantar reflex was used AA/O by 53.8% of respondents. Conversely, 84.9% of respondents N/R assessed ankle-leg index, 81.9% N/R performed Heron-Pheasant's test and N/R assessed 53.8% muscle girth.

#### *Cervical Spine – manual therapeutic procedures (Table 4)*

The most commonly used cervical mobilization (cMOB) were long axis distraction (AA/O used by 76.2% of respondents), segmental rotation (65.7%), global lateral flexion (61.9%), segmental lateral flexion (60%), segmental extension (54.2%) and global rotation (49.5%). All listed mobilizations were used to some extent.

The cervical spinal manipulative procedures AA/O used by respondents in this study for the cervical spine were the Supine Rotary Cervical manipulation with Lateral Flexion (81%) and the Supine Rotary manipulation (74.3%). The next most commonly used procedures were the Lateral Break, Lateral Atlas, Seated and Prone cSMT. A number of other cSMT were N/R used by respondents, these were predominately the 'muscle adjustments'.

#### *Thoracic spine – manual therapeutic procedures (Table 5)*

With respect to thoracic spine mobilizations (tMOB), respondents reported AA/O or N/R using long axis distraction (50%), iliotransverse (42.5%), iliocostal (41.5%) and seated procedures (43.4%) in almost equal numbers.

The most commonly reported thoracic spinal manipulative therapies (tSMT) used AA/O were the Anterior (80.2%), Cross-Bilateral (74.5%), Carver (71.7%), Combination (65.1%) and Modified Anterior (61.3%). The other tSMT listed (Thumb Move, Reinforced Unilateral and First Rib) were AA/O or ST used by more than half of respondents. The only tSMT N/R used by a large number of respondents was the Lateral Recumbent Rib (67.9%).

#### *Lumbar spine – manual therapeutic procedures (Table 6)*

With respect to lumbar mobilizations (L-MOB), long axis distraction was used AA/O by 61.3% of respondents and iliomammillary mobilization was used AA/O by 49.1% of respondents

The lumbar spinal manipulative procedures most frequently reported as being AA/O used by respondents in this study were the Lumbar Roll ((81.1%), followed by the Lumbar Pull (68.9%), Lumbar Push (56.5%) and 'Bonyun'/Long Axis Distraction (54.5%). A number of other lumbar spinal manipulative therapies (L-SMT) were frequently reported as N/R, notably the Reverse Roll (84%), Seated (75.5%) and Disc Opening (61.3%) procedures.

#### *Pelvic spine – manual therapeutic procedures (Table 7)*

With respect to mobilizations of the pelvis, respondents reported to AA/O use the sacral pump, knee-chest, and iliofemoral, although it should be noted that 50% of respondents reported they N/R use the iliofemoral mobilization procedure.

The pelvic spinal manipulative procedure most frequently reported as being AA/O used by respondents in this study was the PSIS contact ('upper SI') spinal manipulative procedure (85.8%). Other pelvic spinal manipulative therapies (P-SMT) were AA/O used less frequently. In descending order these were Ischial contact ('lower SI'), Prone SI, and Sacral base. Respondents reported to AA/O or N/R use the Sacral Apex manipulative procedure at almost the same frequency (roughly 39%). The Sitting Iliac Flexion procedure was N/R used by 85.8% of respondents, lateral (or side posture) pelvic therapy was N/R used by 61.3% of respondents and the Supine Iliac Flexion procedure was N/R used by 59.4% of respondents.

## Discussion

Three distinct categories of tests can be discerned from the results of this survey. There appears to be one group of tests that respondents to this survey ‘Almost Always’ or ‘Often’ use. These mainly consist of segmental joint play, static and motion palpation, ranges of motion and neurologic testing of the different spinal regions. Triano et al<sup>6</sup> reported there was good evidence for some of these tests when used to identify the site of care (the clinical target of manipulation). The second category of tests identified in this survey was more condition-specific and AA/O used by roughly one half to two-thirds of respondents in this survey. For example, cervical compression tests (Kemp’s, Jackson’s or Spurling’s test) or nerve tension tests of the lumbar spine (Braggard’s or Bowstring’s test) may be required to be used on some – but not all – patients presenting to a chiropractor’s office depending on the presence of referred or radicular pain.

The third category of tests identified from the current survey are those that are ‘Never’ or ‘Rarely’ used by the majority of respondents. These include Naffzinger’s or L’Hermitte’s tests in the cervical spine, true and apparent leg length testing in the thoracic spine and Schober’s or Ankle-leg index testing in the lumbar spine.

Overall, the level of vertical integration reported by respondents in this study with respect to diagnostic and therapeutic procedures of the spine was lower than the level of vertical integration reported from clinical faculty from CMCC<sup>1,2</sup>, especially of the thoracic spine.

## Study Limitations

The most notable limitation of this study was its very low response rate of only 22.2%. This low response rate and the pseudo-randomized sample reduce confidence in the generalizability of our findings. Furthermore our study included graduates of CMCC and other institutions, so it is possible that those educated at institutions other than CMCC may not have been taught some of the tests and techniques in the CMCC curriculum. Our decision to use a pencil-and-paper survey distributed by mail rather than an electronic survey may have contributed to the poor response rate. Future studies could perhaps garner a higher response rate using an on-line survey.

We chose not to set parameters around what constituted ‘almost always’ versus ‘sometimes used’ or ‘often used’, instead relying on respondents to interpret what

these meant. Future studies could provide definitions of these terms (ie ‘almost always’ implies the test is used on more than 90% of patients) for respondents.

## Conclusions

This study reported on the frequency of use of diagnostic and therapeutic procedures currently taught at CMCC by a group of pseudo-randomized Ontario chiropractors, most but not all of whom were CMCC graduates. The most commonly used diagnostic procedures for the cervical, thoracic, and lumbopelvic spine were joint play, static and motion palpation, neurological testing and ranges of motion. A number of other orthopaedic tests were less commonly used, and a number of tests were either rarely or not used at all, particularly in the assessment of the thoracic spine. With respect to therapeutic procedures of the spine, many mobilization and manipulative procedures are commonly used, with the exception of the ‘muscle’ manipulations of the cervical spine.

## References

1. Vermet S, McGinnis K, Boodham MS et al. Degree of vertical integration between the undergraduate program and clinical internship with respect to lumbopelvic diagnostic and therapeutic procedures taught at the Canadian Memorial Chiropractic College. *J Chiro Ed.* 2010;24(1):46-56.
2. Leppington C, Gleberzon BJ, Fortunato L et al. Degree of vertical intergration between the undergraduate program and clinical internship with respect to cervical and cranial diagnostic and therapeutic procedures taught at the Canadian Memorial Chiropractic College. *J Chiro Ed.* 2011;26(1):51-61.
3. Gleberzon BJ, Stuber K. Frequency of use of diagnostic and manual therapeutic procedures of the spine taught at the Canadian Memorial Chiropractic College: A preliminary survey of Ontario chiropractors. Part 1 – Practice Characteristics and Demographic profiles. *J Can Chiro Assoc.* 2013;57(1):32-41.
4. Gleberzon BJ, Ross K. *Manual of Diversified Diagnostic and Therapeutic Procedures.* Self-Published (Canadian Memorial Chiropractic College). February 2007.
5. Guerrero R. *CMCC: Orthopedic Lab Manual.* Self-published (Canadian Memorial Chiropractic College). January, 2011.
6. Triano JJ et al. Systematic review of methods used by chiropractors to determine the site of care. In submission.

Table 1.  
Cervical spinal diagnostic examination procedure usage

TEST	Number of Respondents	% CATEGORY 1 Never / Rarely (n)	% CATEGORY 2 Sometimes (n)	% CATEGORY 3 Often/ Almost Always (n)	% CATEGORY 4 Haven't had a patient to cause them to use it (n)
Cervical spine Ranges of Motion	108	0 (0)	0 (0)	100 (108)	0 (0)
Joint Play	108	1.9 (2)	1.9 (2)	96.3 (104)	0 (0)
Static Palpation	108	4.6 (5)	0 (0)	95.4 (103)	0 (0)
Motion Palpation	108	2.8 (3)	13 (14)	84.3 (91)	0 (0)
Cervical compression	108	13 (14)	24.1 (26)	63 (68)	0 (0)
Jackson's	108	25 (27)	23.1 (25)	50.9 (55)	0.9 (1)
Spurling's	108	30.6 (33)	22.2 (24)	46.3 (50)	0.9 (1)
Kemp's	108	11.1 (12)	6.5 (7)	82.4 (89)	0 (0)
Distraction	108	22.2 (24)	19.4 (21)	58.3 (63)	0 (0)
Abduction	108	25.9 (28)	26.9 (29)	46.3 (50)	0.9 (1)
Doorbell	108	32.4 (35)	21.3 (23)	45.4 (49)	0.9 (1)
Upper limb tension	108	63 (68)	22.2 (24)	13 (14)	1.9 (2)
Soto-Hall	108	60.2 (65)	21.3 (23)	13 (14)	5.6 (6)
EAST	108	74.1 (80)	16.7 (18)	7.4 (8)	1.9 (2)
Adson's	108	45.4 (49)	30.6 (33)	22.2 (24)	1.9 (2)
Wright's	108	50 (54)	27.8 (30)	20.4 (22)	1.9 (2)
Eden's	108	55.6 (60)	24.1 (26)	18.5 (20)	1.9 (2)
Kernig's	108	54.6 (59)	15.7 (17)	22.2 (24)	7.4 (8)
Brudzinski's	108	50 (54)	19.4 (21)	19.4 (21)	11.1 (12)
L'Hermittes	108	61.1 (66)	20.4 (22)	9.3 (10)	9.3 (10)
Percussion	108	57.4 (62)	24.1 (26)	15.7 (17)	2.8 (3)
Valsalva	108	25.9 (28)	26.9 (29)	47.2 (51)	0 (0)
Rhomberg's	108	38 (41)	25.9 (28)	31.5 (34)	4.6 (5)
Rotary Chair	108	70.4 (76)	18.5 (20)	3.7 (4)	7.4 (8)
Dix-Hallpike	108	70.4 (76)	14.8 (16)	8.3 (9)	6.5 (7)
Cervical flexion-rotation	108	64.8 (70)	12 (13)	19.4 (21)	3.7 (4)
Naffziger's	108	85.2 (92)	4.6 (5)	2.8 (3)	7.4 (8)
Sensory	108	9.3 (10)	15.7 (17)	75 (81)	0 (0)
Motor	108	2.8 (3)	10.2 (11)	85.2 (92)	1.9 (2)
Reflex	108	4.6 (5)	11.1 (12)	83.3 (90)	0.9 (1)
Hoffman's	108	67.6 (73)	16.7 (18)	10.2 (11)	5.6 (6)
Houle's	108	70.4 (76)	10.2 (11)	14.8 (16)	4.6 (5)

Table 2.  
*Thoracic spine examination maneuver usage*

TEST	Number of Respondents	% CATEGORY 1 Never / Rarely (n)	% CATEGORY 2 Sometimes (n)	% CATEGORY 3 Often/ Almost Always (n)	% CATEGORY 4 Haven't had a patient to cause them to use it (n)
Adam's	106	17.9 (19)	17 (18)	65.1 (69)	0 (0)
Thoracic spine Ranges of Motion	106	1.9 (2)	4.7 (5)	93.4 (99)	0 (0)
Joint play	106	4.7 (5)	0 (0)	95.3 (101)	0 (0)
Motion palpation	106	7.5 (8)	12.4 (13)	79.2 (84)	0.9 (1)
Static palpation	106	3.8 (4)	0 (0)	96.2 (102)	0 (0)
Slump	106	67.9 (72)	13.2 (14)	16 (17)	2.8 (3)
Kemp's	106	21.7 (23)	7.5 (8)	69.8 (27)	0.9 (1)
Chest expansion	106	73.6 (78)	12.3 (13)	10.4 (11)	3.8 (4)
Passive scapular approximation	106	66 (70)	7.5 (8)	25.5 (27)	0.9 (1)
Doorbell	106	38.7 (41)	23.6 (25)	37.7 (40)	0 (0)
Valsalva	106	28.3 (30)	27.4 (29)	44.3 (47)	0 (0)
Kernig's	106	61.3 (65)	15.1 (16)	17.9 (19)	5.7 (6)
Brudzinski's	107	51.4 (55)	17.8 (19)	20.6 (22)	10.3 (11)
L'Hermittes	107	64.5 (69)	20.3 (22)	4.7 (5)	10.3 (11)
Upper limb tension	107	68.2 (73)	17.8 (19)	12.1 (13)	1.9 (2)
Straight leg raise	107	11.2 (12)	3.7 (4)	84.1 (90)	0.9 (1)
Soto-Hall	107	62.6 (67)	16.8 (18)	15.9 (17)	4.7 (5)
Sternal Compression	107	57.9 (62)	17.8 (19)	23.4 (25)	0.9 (1)
Rib springing	107	26.2 (28)	22.4 (24)	51.4 (55)	0 (0)
True leg length	107	59.8 (64)	16.8 (18)	23.4 (25)	0 (0)
Apparent leg length	107	62.6 (67)	12.1 (13)	24.3 (26)	0.9 (1)
Percussion	107	56.1 (60)	23.4 (25)	19.6 (21)	0.9 (1)
Skin rolling	107	64.5 (69)	17.8 (19)	14 (15)	3.7 (4)
Beevor's sign	107	72.3 (78)	15.9 (17)	9.3 (10)	1.9 (2)
Beevor's test	107	84.1 (90)	8.4 (9)	4.7 (5)	2.8 (3)
Plantar reflex	107	39.3 (42)	23.4 (25)	36.4 (39)	0.9 (1)

Table 3.  
Lumbopelvic diagnostic examination procedure usage

TEST	Number of Respondents	% CATEGORY 1 Never / Rarely (n)	% CATEGORY 2 Sometimes (n)	% CATEGORY 3 Often/ Almost Always (n)	% CATEGORY 4 Haven't had a patient to cause them to use it (n)
Lumbar static palpation	107	0.9 (1)	0 (0)	99.1 (106)	0 (0)
Motion palpation	107	5.6 (6)	7.5 (8)	86.9 (93)	0 (0)
Joint play	107	3.7 (4)	0 (0)	96.3 (103)	0 (0)
Lumbar spine Ranges of Motion	107	1.9 (2)	2.8 (3)	95.3 (102)	0 (0)
Gait	107	5.6 (6)	9.3 (10)	85 (91)	0 (0)
Heel / Toe walking	107	15.9 (17)	16.8 (18)	66.4 (71)	0.9 (1)
Tandem gait	107	38.3 (41)	17.8 (19)	42.1 (45)	1.9 (2)
Kemp's	107	7.5 (8)	9.3 (10)	82.2 (88)	0.9 (1)
Schober's	107	86 (92)	7.5 (8)	2.8 (3)	3.7 (4)
Trendelenburg	107	37.4 (40)	24.3 (26)	38.3 (41)	0 (0)
Gillet	107	44.9 (48)	9.3 (10)	45.8 (49)	0 (0)
Waddell	107	57.9 (62)	26.2 (28)	15.9 (17)	0 (0)
Valsalva	107	22.4 (24)	24.3 (26)	53.3 (57)	0 (0)
Percussion	107	48.6 (52)	24.3 (26)	25.2 (27)	1.9 (2)
Minor's sign	107	28 (30)	18.7 (20)	51.4 (55)	1.9 (2)
Sensory	106	13.2 (14)	12.3 (13)	74.5 (79)	0 (0)
Motor	106	3.8 (4)	5.7 (6)	90.6 (96)	0 (0)
Reflex	106	7.5 (8)	8.5 (9)	84 (89)	0 (0)
Plantar reflex	106	23.6 (25)	21.7 (23)	53.8 (57)	0.9 (1)
Straight leg raise	106	1.9 (2)	2.8 (3)	95.3 (101)	0 (0)
Crossed straight leg raise	106	12.3 (13)	8.5 (9)	79.2 (84)	0 (0)
Braggard's	106	19.8 (21)	17 (18)	63.2 (67)	0 (0)
Bowstring	106	41.5 (44)	17.9 (19)	40.6 (43)	0 (0)
Gaenslen's	106	55.7 (59)	16 (17)	28.3 (30)	0 (0)
Thomas	106	37.7 (40)	8.5 (9)	53.8 (57)	0 (0)
Muscle girth	106	53.8 (57)	30.2 (32)	16 (17)	0 (0)
Lower limb pulses	106	61.3 (65)	26.4 (28)	12.3 (13)	0 (0)
Ankle-leg index	106	84.9 (90)	4.7 (5)	1.9 (2)	8.5 (9)
FABER	106	12.3 (13)	18.9 (20)	68.9 (73)	0 (0)
Thigh thrust	106	55.7 (59)	14.2 (15)	29.2 (31)	0.9 (1)
Distraction	106	41.5 (44)	22.6 (24)	34.9 (37)	0.9 (1)
Psoas palpation	105	17.1 (18)	18.1 (19)	64.8 (68)	0 (0)
Ober's	105	45.7 (48)	25.7 (27)	28.6 (30)	0 (0)
FAIR	105	56.2 (59)	15.2 (16)	27.6 (29)	1 (1)
Ely's	105	18.1 (19)	14.3 (15)	67.6 (71)	0 (0)
Hibb's	105	26.7 (28)	14.3 (15)	59 (62)	0 (0)
Yeoman's	105	22.9 (24)	15.2 (16)	61.9 (65)	0 (0)
Herron-Pheasant	105	81.9 (86)	10.5 (11)	2.9 (3)	4.8 (5)
Sciatic notch tenderness	105	22.9 (24)	15.2 (15)	61.9 (65)	0 (0)
Spinous percussion	105	49.5 (52)	24.8 (26)	24.8 (26)	1 (1)
Sacral thrust	105	6.7 (7)	14.3 (15)	79 (83)	0 (0)
PSIS challenge	105	4.8 (5)	3.8 (4)	91.4 (96)	0 (0)



Table 4.  
Cervical spinal manual therapy procedure usage

Procedure	Mobilization or manipulation	Number of Respondents	% CATEGORY 1 Never / Rarely (n)	% CATEGORY 2 Sometimes (n)	% CATEGORY 3 Often/ Almost Always (n)	% CATEGORY 4 Haven't had a patient to cause them to use it (n)
Cervical Long Axis Distraction	Mobilization	105	14.3 (15)	9.5 (10)	76.2 (80)	0 (0)
Forward flexion	Mobilization	105	40.4 (42)	20.2 (21)	39.4 (41)	1 (1)
Segmental lateral flexion	Mobilization	105	27.6 (29)	12.4 (13)	60 (63)	0 (0)
Global lateral flexion	Mobilization	105	23.8 (25)	14.3 (15)	61.9 (65)	0 (0)
Segmental rotation	Mobilization	105	19 (20)	15.2 (16)	65.7 (69)	0 (0)
Global rotation	Mobilization	105	33.3 (35)	17.1 (18)	49.5 (52)	0 (0)
Segmental extension	Mobilization	105	32.4 (34)	13.3 (14)	54.2 (57)	0 (0)
Segmental forward flexion	Mobilization	105	61 (64)	11.4 (12)	27.6 (29)	0 (0)
Figure 8	Mobilization	105	66.7 (70)	15.2 (16)	18.1 (19)	0 (0)
Rotary occiput	Manipulation	105	46.7 (49)	17.1 (18)	36.2 (38)	0 (0)
Lateral occiput	Manipulation	105	51.4 (54)	24.8 (26)	23.8 (25)	0 (0)
Occiput flexion	Manipulation	105	76.2 (80)	13.3 (14)	10.5 (11)	0 (0)
Occiput extension	Manipulation	105	72.4 (76)	13.3 (14)	14.3 (15)	0 (0)
Lateral atlas	Manipulation	105	30.5 (32)	24.8 (26)	44.8 (47)	0 (0)
Toggle recoil	Manipulation	105	81.9 (86)	5.7 (6)	12.4 (13)	0 (0)
Supine rotary cervical	Manipulation	105	19 (20)	6.7 (7)	74.3 (78)	0 (0)
Supine rotary with lateral flexion	Manipulation	105	13.3 (14)	5.7 (6)	81 (85)	0 (0)
Lateral cervical	Manipulation	105	27.6 (29)	14.3 (15)	58.1 (61)	0 (0)
Prone cervical	Manipulation	105	48.6 (51)	14.3 (15)	36.2 (38)	1 (1)
Seated cervical	Manipulation	105	49.5 (52)	21 (22)	39 (41)	0 (0)
Bedside cervical	Manipulation	105	68.6 (72)	15.2 (16)	15.2 (16)	1 (1)
Scalene	Manipulation	105	77.1 (81)	15.2 (16)	7.6 (8)	0 (0)
Semispinalis	Manipulation	105	90.5 (95)	5.7 (6)	3.8 (4)	0 (0)
Splenius	Manipulation	105	86.7 (91)	9.5 (10)	3.8 (4)	0 (0)
Sternocleidomastoid	Manipulation	105	82.9 (87)	9.5 (10)	7.6 (8)	0 (0)

Table 5.  
Thoracic spinal manual therapy procedure usage

Thoracic Spinal Procedures	Mobilization or manipulation	Number of Respondents	% CATEGORY 1 Never / Rarely (n)	% CATEGORY 2 Sometimes (n)	% CATEGORY 3 Often/ Almost Always (n)	% CATEGORY 4 Haven't had a patient to cause them to use it (n)
Thoracic Long Axis Distraction	Mobilization	106	41.5 (44)	7.5 (8)	50 (53)	0.9 (1)
Iliotransverse	Mobilization	106	33 (35)	24.5 (26)	42.5 (45)	0 (0)
Iliocostal	Mobilization	106	40.6 (43)	17.4 (18)	41.5 (44)	0.9 (1)
Seated forward flexion, extension, rotation, lateral bending	Mobilization	106	38.7 (41)	17.9 (19)	43.4 (46)	0 (0)
Cross-bilateral	Manipulation	106	9.4 (10)	16 (17)	74.5 (79)	0 (0)
Reinforced unilateral	Manipulation	106	36.8 (39)	20.8 (22)	42.5 (45)	0 (0)
Carver	Manipulation	106	17.9 (19)	10.4 (11)	71.7 (76)	0 (0)
Thumb move	Manipulation	106	29.2 (31)	23.6 (25)	47.2 (50)	0 (0)
Combination	Manipulation	106	20.8 (22)	14.2 (15)	65.1 (69)	0 (0)
First rib	Manipulation	106	36.8 (39)	19.8 (21)	43.4 (46)	0 (0)
Anterior	Manipulation	106	15.1 (16)	4.7 (5)	80.2 (85)	0 (0)
Modified anterior	Manipulation	106	22.6 (24)	16 (17)	61.3 (65)	0 (0)
Lateral recumbent thoracic rib	Manipulation	106	67.9 (72)	12.2 (13)	18.9 (20)	0.9 (1)

Table 6.  
Lumbar spinal manual therapy procedure usage

Lumbar Spinal Procedures	Mobilization or manipulation	Number of Respondents	% CATEGORY 1 Never / Rarely (n)	% CATEGORY 2 Sometimes (n)	% CATEGORY 3 Often/ Almost Always (n)	% CATEGORY 4 Haven't had a patient to cause them to use it (n)
Lumbar Long Axis Distraction	Mobilization	106	26.4 (28)	12.3 (13)	61.3 (65)	0 (0)
Iliomammillary	Mobilization	106	37.7 (40)	13.2 (14)	49.1 (52)	0 (0)
Lumbar roll	Manipulation	106	13.2 (14)	5.7 (6)	81.1 (86)	0 (0)
Lumbar push	Manipulation	106	30.2 (32)	13.2 (14)	56.6 (60)	0 (0)
Lumbar pull	Manipulation	106	16.0 (17)	15.1 (16)	68.9 (73)	0 (0)
Bonyun	Manipulation	106	29.2 (31)	16.0 (17)	54.7 (58)	0 (0)
Seated lumbar	Manipulation	106	75.5 (80)	19.8 (21)	4.7 (5)	0 (0)
Disc opening	Manipulation	106	61.3 (65)	12.3 (13)	26.4 (28)	0 (0)
Reverse roll	Manipulation	106	84.0 (89)	6.6 (7)	9.4 (10)	0 (0)

Table 7.  
*Pelvis manual therapy procedure usage*

<b>Pelvic Procedures</b>	<b>Mobilization or manipulation</b>	<b>Number of Respondents</b>	<b>% CATEGORY 1 Never / Rarely (n)</b>	<b>% CATEGORY 2 Sometimes (n)</b>	<b>% CATEGORY 3 Often/ Almost Always (n)</b>	<b>% CATEGORY 4 Haven't had a patient to cause them to use it (n)</b>
Iliofemoral	Mobilization	106	50 (53)	15.1 (16)	34.9 (37)	0 (0)
Sacral pump	Mobilization	106	25.5 (27)	24.5 (26)	50 (53)	0 (0)
Knee chest	Mobilization	106	37.7 (40)	16 (17)	46.2 (49)	0 (0)
Supine iliac flexion	Mobilization	106	59.4 (63)	17.9 (19)	22.6 (24)	0 (0)
Sitting sacroiliac flexion	Mobilization	106	85.8 (91)	2.8 (3)	11.3 (12)	0 (0)
Lateral pelvis	Mobilization	106	61.3 (65)	5.7 (6)	33 (35)	0 (0)
Posterior superior iliac spine contact upper sacroiliac joint	Manipulation	106	8.5 (9)	5.7 (6)	85.8 (91)	0 (0)
Ischial contact lower sacroiliac joint	Manipulation	106	17.9 (19)	17 (18)	65.1 (69)	0 (0)
Sacral base	Manipulation	106	29.2 (31)	18.9 (20)	51.9 (55)	0 (0)
Sacral apex	Manipulation	106	38.7 (41)	21.7 (23)	39.6 (42)	0 (0)
Prone sacroiliac joint	Manipulation	106	22.6 (24)	15.1 (16)	62.3 (66)	0 (0)

# Comminuted scapular body fractures: A report of three cases managed conservatively in chiropractic settings

Julie Lynn Scarano, DC, CCSP, CCWP\*  
Matthew Richardson, DC, DACBR\*\*  
John A. Taylor, DC, DACBR†

*Fractures of the scapula are relatively uncommon. Fractures specific to the scapular body comprise 35-65% of these fractures. Currently, 99% of all isolated scapular body fractures are being treated non-operatively with an immobilizing sling or brace and some form of manual therapy with an 86% success rate. We present the conservative management of three patients with comminuted fractures involving the scapular body that were managed in chiropractic settings. Residual disabilities in these three patients as measured by a standardized outcome tool were 2%, 5% and 23% after 3 years, 2 years, and 6 years respectively.*

**KEY WORDS:** scapula, fractures, comminuted, chiropractic, case management

*Les fractures de la scapula sont relativement communes. Les fractures spécifiques au corps de la scapula représentent entre 35 et 65 % de ces fractures. Actuellement, 99 % des fractures isolées du corps de la scapula se traitent sans intervention chirurgicale, simplement en immobilisant la partie concernée avec une écharpe ou un appareil orthopédique et à l'aide de thérapies manuelles, avec un taux de réussite de 86 %. Nous présentons la gestion conservatrice de trois patients touchés avec des fractures comminutives touchant le corps de la scapula, qui sont traités par manipulations chiropratiques. Les incapacités résiduelles de ces trois patients mesurées par un instrument standardisé sont de 2 %, 5 % et 23 % après 3 ans, 2 ans et 6 ans respectivement.*

**MOTS CLÉS :** scapula, fractures, comminutives, chiropratique, gestion de cas

\* Corresponding Author, Santiago Chiropractic Associates  
75 North Beverwyck Rd., Lake Hiawatha, NJ 07034  
973-335-5666  
Dr.Scarano@SantiagoChiropractic.com

\*\*Palmer College of Chiropractic Florida Campus  
4705 S Clyde Morris Blvd, Port Orange, FL 32129

† D'Youville College, Department of Chiropractic  
320 Porter Avenue, Buffalo, NY 14121

Sources of support: None

Commercial associations and conflicts of interest: None

Acknowledgement: The authors thank Leslie M. Stoklosa, DC, MS and Karol A. Donaubauer, BA, DC, CCSP for sharing their case material and Christopher J. Herrington, BS for his technical assistance with images and literature acquisition.

©JCCA 2013

## Introduction

Fractures of the scapula are relatively uncommon. Fractures specific to the scapular body comprise 35-65% of these fractures.<sup>1-4</sup> Currently, 99% of all isolated scapular body fractures are being treated non-operatively with an immobilizing sling or brace and some form of manual therapy with an 86% success rate.<sup>5</sup> Scapular fractures have been a subject of investigation since Desault's treatise of 1805.<sup>6</sup> Scapular fractures constitute only 1% of all fractures, 3% of shoulder-girdle injuries, and only 5% of all shoulder fractures.<sup>7</sup> The infrequent occurrence of scapular fractures has been attributed to its protection anteriorly by the rib cage and thoracic cavity, a thick covering of soft tissue including eighteen muscular origins and insertions, and a wide range of mobility that allows for considerable dissipation of traumatic forces.<sup>8,9</sup>

Scapular fractures occur most frequently in the 3<sup>rd</sup> and 4<sup>th</sup> decades of life with 64-90% occurring in men.<sup>3,10,11</sup> While isolated body fractures are most frequently caused by falls from different heights,<sup>12</sup> the most common cause of scapular body fractures in multi-trauma patient groups are road traffic accidents.<sup>2,13</sup>

The Disabilities of the Arm, Shoulder and Hand (DASH) outcome measure used in these case studies is a 30-item, self-report questionnaire designed to measure the physical function and symptoms in patients with any or several musculoskeletal disorders of the upper limb. The questionnaire ([www.dash.iwh.on.ca](http://www.dash.iwh.on.ca)) was jointly developed by the Institute for Work and Health and the American Academy of Orthopaedic Surgeons (AAOS) and was designed to help grade the disability experienced by people with upper-limb disorders and also to monitor changes in symptoms and function over time. Testing has shown that the DASH performs well in both these roles.<sup>14</sup>

The purpose of this paper is to describe both the identification and conservative management of three cases of comminuted scapular body fractures which presented at three different chiropractic centers.

## Case Reports

### Case 1

#### *History*

A 43 year old male manual laborer presented to a chiropractic community outreach clinic with right shoulder

pain eight days after slipping on ice and striking his right shoulder on cement blocks.

#### *Physical Examination*

This patient was able to remove his shirt but expressed mild discomfort with arm movements. Considerable contusion was evident overlying the inferior angle of the scapula and posterolateral thoracic wall. Decreased shoulder ranges of motion were accompanied by pain to palpation of the acromioclavicular (AC) joint evoking clinical suspicion of an AC joint sprain or separation. Crepitus was elicited over the acromion process and at the superior aspect of the shoulder during active abduction and external rotation. Shallow breathing and decreased normal lung sounds on inspiration and expiration in the right apical as well as upper anterior and posterior regions were observed with no significant signs of respiratory distress.

#### *Diagnostic Imaging*

Chest and shoulder radiographs were obtained and revealed comminuted scapular fracture with isolation and antero-medial displacement of the GH joint, separation at the superior aspect of the acromioclavicular joint, displaced fractures of ribs 3, 4 and 6-9 on the right, pneumothorax, and passive/relaxation atelectasis (Figure 1A).

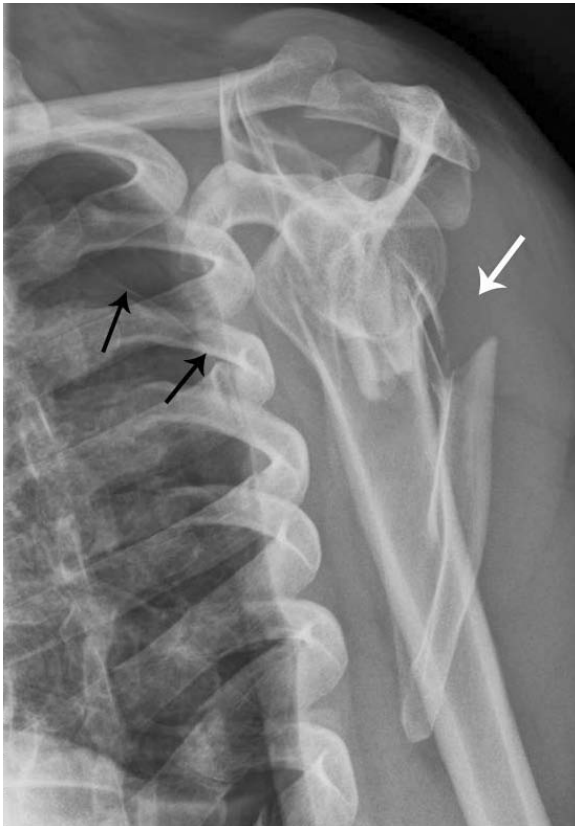
#### *Management*

The patient was transferred to the emergency department of a local hospital, where blood testing and a metabolic panel were interpreted as normal. The patient was then prescribed analgesic medication, a sling, and an orthopedic referral. The orthopedic consultant recommended against surgery, but advised the patient to continue immobilizing the shoulder in the sling for 6 weeks and then follow up. Approximately 3 weeks post injury, he presented back to the chiropractic community outreach clinic for treatment. Management consisted primarily of myofascial release of the trapezius and cervicothoracic paraspinal musculature, as well as diversified chiropractic adjustments to the cervical spine and instrument assisted (activator) adjustments as needed and tolerable in the thoracic spine. Treatments were administered approximately once per week for 16 weeks.

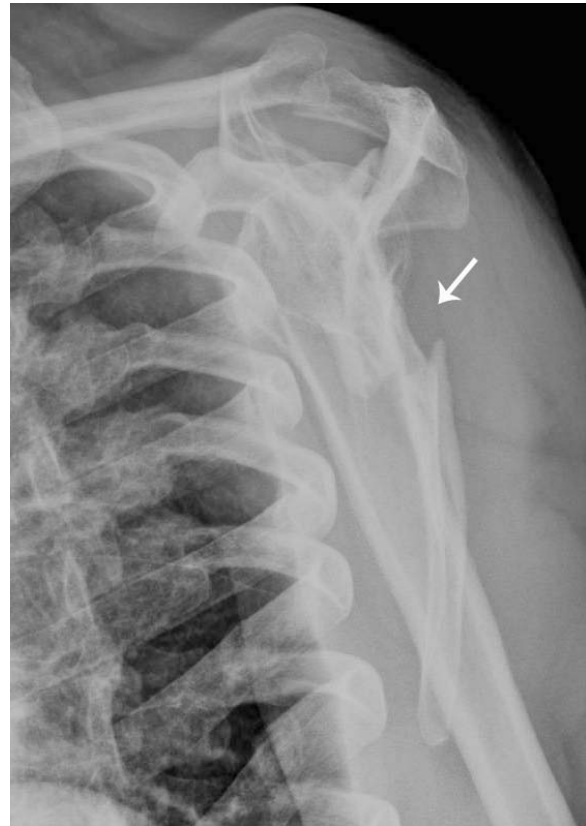#### *Outcome*

Four months after the initial injury, follow up radiographs

Figure 1. Case 1:



**Figure 1A:** Right lateral scapular “Y” view demonstrating antero-medial displacement of the glenohumeral joint and comminuted scapular fracture (white arrow) eight days after injury. The visceral pleural line (black arrows) is retracted and there are no vascular markings beyond the pleural line – evidence of a right-sided pneumothorax.



**Figure 1B:** Serial radiograph four months after the injury showing a reduction in displacement of the fracture fragment (white arrow) composed of the inferior scapular body and angle with rounding of the fracture margins. The pneumothorax has resolved.

were taken and demonstrated a reduction in the displacement of the fracture fragment composed of the inferior scapular body and angle (Figure 1B). Re-examination at this time indicated some improvement in both active and passive right shoulder ranges of motion and normal shoulder orthopedic testing, but reduced muscle strength of the rotator cuff and deltoid musculature (4/5) and continued mild edema, bruising and tenderness overlying the scapula. However, with continued treatment, two months later, this patient was pain free, with near normal ranges of mo-

tion of the shoulder and strength of the rotator cuff musculature. Despite the temporary disability leave he was given by his orthopedist initially, this patient continued with light duty throughout his treatments and was able to return to work fully afterward with only slight soreness at the end of the day. On follow up, three years after the initial injury, this patient completed the Disabilities of the Shoulder, Arm and Hand (DASH) outcome questionnaire which indicated disability of less than 2%.<sup>14</sup>

## Case 2

### History

A 53 year old Caucasian male businessman presented to the emergency room with right posterior shoulder pain sustained when an unexpected acceleration of a boat caused him to lose his balance and fall backward – striking his right scapula directly on the gunwale of the boat. Radiographs (Figure 2A) and CT images (Figure 2B) of the chest and shoulder were performed revealing a comminuted fracture of the right mid and lower scapular body with irregular fracture planes and multiple distracted, angulated and foreshortened fracture fragments as well as additional linear fractures through the base of the acromion and coracoid processes. The acromioclavicular and glenohumeral joints were intact with no dislocation and there was no evidence of pneumothorax or pleural effusion. The patient was fitted for a brace, prescribed analgesic medication to alleviate his symptoms and referred to an orthopedist. During this visit one week later,

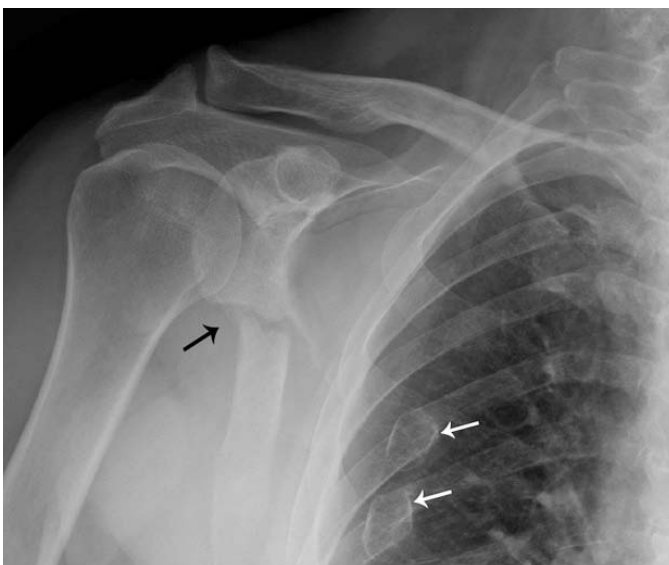in agreement with the ER orthopedist, he was advised against surgical intervention due to the delicate muscular envelope of the scapula and scheduled for re-checks two and six weeks later. Additionally, an MRI was scheduled demonstrating a partial thickness tear of the supraspinatus tendon, fluid in the subacromial/subdeltoid bursa compatible with shoulder impingement and moderate degenerative changes at the acromioclavicular joint encroaching upon the supraspinatus muscle tendon complex.

The patient presented for a chiropractic evaluation three weeks following the incident to begin conservative management of his injuries. At that time, the patient had already resumed working, discontinued his analgesic medication, and was beginning to feel more comfortable with his arm out of the brace.

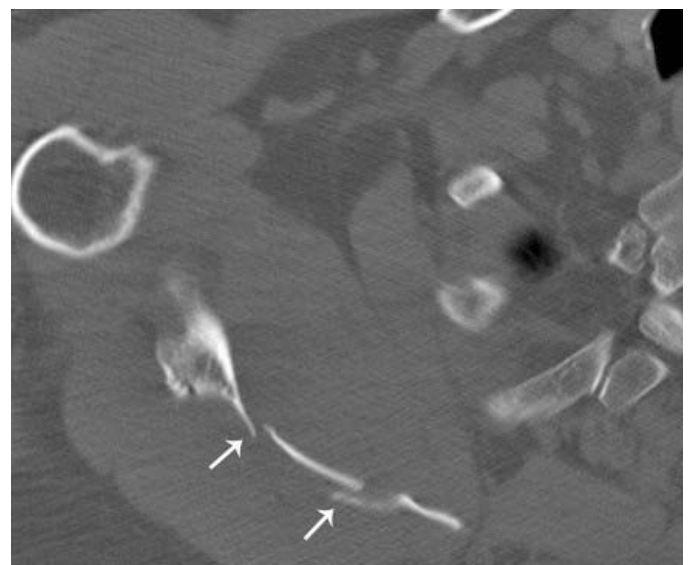
### Physical Examination

Initial examination revealed limitations with active shoulder range of motion in all directions (flexion 100°, extension 15°, abduction 20°, adduction 15°, external rotation

Figure 2. Case 2:



**Figure 2A:** External rotation view of the right shoulder on day of injury. Comminuted scapular fracture (black arrow) and old 6th and 7th posterior rib fractures from a previous injury that have healed with deformity (white arrows).



**Figure 2B:** Axial CT scan through the right mid-scapular region also obtained on the day of injury demonstrating numerous comminuted fracture fragments of the scapular body (arrows).

0°, internal rotation 40°). Passive ranges of motion were limited only in extension, abduction, and external rotation to 40°, 90° and 0° respectively. Neurologic examinations were unremarkable, with normal deep tendon reflexes, and no motor or sensory loss with the exception of an inability to test deltoid or bicep strength on the right due to pain. Peripheral upper extremity pulses were symmetrical and of normal amplitude. At this time the DASH outcome questionnaire score indicated an 81% disability.<sup>14</sup>

### *Management*

This patient was treated eighteen times over an eleven week period. Therapy began with early progressive passive range of motion and Codman exercises and progressed to active movements under supervision as tolerated. Complementary therapies included electric muscle stimulation, therapeutic ultrasound and class IV laser treatment. After 4 weeks of treatment, therapy was focused on rehabilitating the rotator cuff with progressive isometric resistance, therapeutic bands, strengthening parascapular musculature, and preventing soft tissue adhesions using manual release methods and instrument assisted techniques. Diversified chiropractic manipulations of the cervical spine were administered for joint restrictions as indicated and mobilizations of the ribs and thoracic spine were also performed to tolerance.

### *Outcome*

Nineteen weeks after the initial injury, this patient demonstrated pain free active ranges of motion in the shoulder with only slight crepitations at the scapulothoracic interface and a DASH score reduced to 5% disability.<sup>14</sup> In a two year follow-up discussion by telephone the patient reported 100% mobility had been maintained with mild residual pain present at times only with sleeping on the injured side.

## **Case 3**

### *History*

A 23 year old right-handed Caucasian male construction laborer was involved in a high speed motor vehicle collision. He was the driver of a mid-sized sedan that was struck from the passenger side in an intersection by another sedan estimated to be traveling at 75 MPH, causing his car to flip over seven times. At impact, his shoulder

restraint was broken and he was thrown into the back seat of the car where he was wedged between the back seat and the rear windshield. He did not lose consciousness at any time after the collision. The fire department used hydraulic spreaders (Jaws of Life) to extricate him from his wedged-in position. He was transported by helicopter Mercy flight to the emergency department where radiographs and CT scans were performed that revealed a fractured scapula. He remained in the hospital overnight and was released the next day with an arm sling and analgesic medication (Darvocet). He consulted with an orthopedic specialist two weeks after the collision where he obtained more radiographs and an MRI examination (not shown). The patient was advised that there was no nerve or muscle damage and that surgery was not necessary and would not improve his outcome.

### *Diagnostic Imaging*

Radiographs of the right shoulder obtained at the hospital immediately after the injury (Figure 3A) revealed a complete vertical fracture of the neck and axillary border of the scapula with a 2 cm lateral displacement of the entire glenoid process and a triangular fracture fragment that projected inferiorly and laterally into the axilla. The GH joint was intact with no evidence of dislocation. Axial CT (Figure 3B) and reconstructed, surface-rendered 3-D CT images (Figure 3C) revealed that the glenoid fragment was internally rotated approximately 20 degrees, as well as an additional minimally displaced comminuted fracture of the scapular body. No evidence of pneumothorax, hemothorax, rib or spine fracture was present.

### *Medical Management*

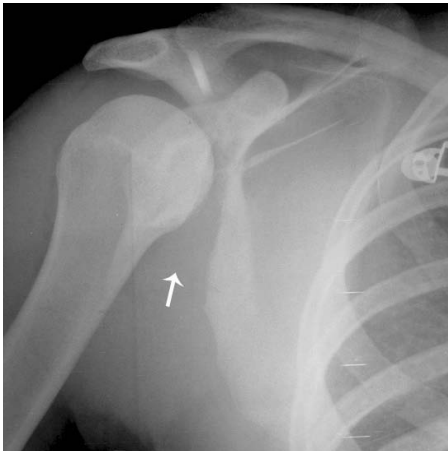
After examination, the orthopedic surgeon prescribed analgesic medication and fitted the patient with a shoulder sling for immobilization and advised against surgery. The patient complied with this advice and the pain gradually decreased over time. After being on disability for one year, this patient was unable to return to work in construction because his job was no longer available. However, he did resume work as a security officer at that time.

### *Chiropractic Management*

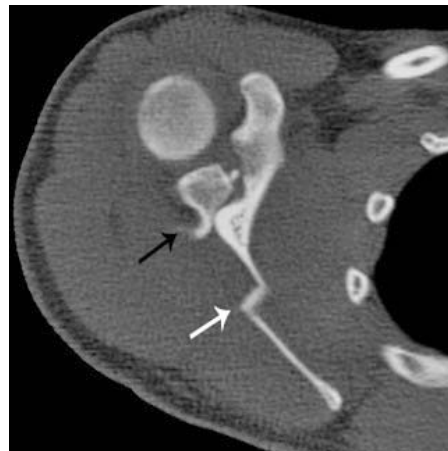Nine months after the initial injury, the patient presented to a chiropractic college health center seeking chiropractic manual treatment and musculoskeletal rehabilitation for



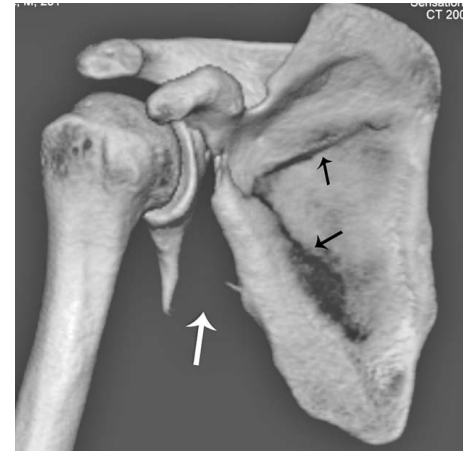
Figure 3. Case 3:



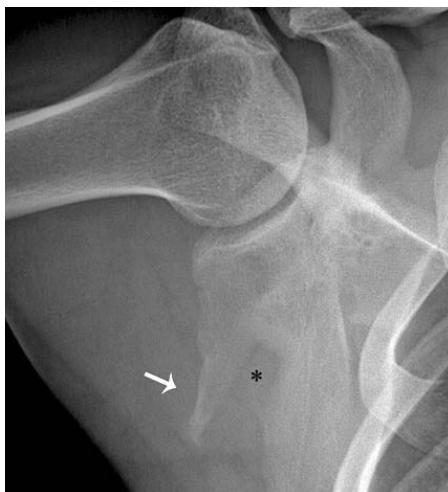**Figure 3A:** An initial radiograph obtained on the day of injury reveals a complete vertical fracture of the neck of the scapula and axillary border of the scapula with a 2 cm lateral displacement of the entire glenoid process and a triangular fracture fragment that project inferiorly and laterally into the axilla (white arrow).



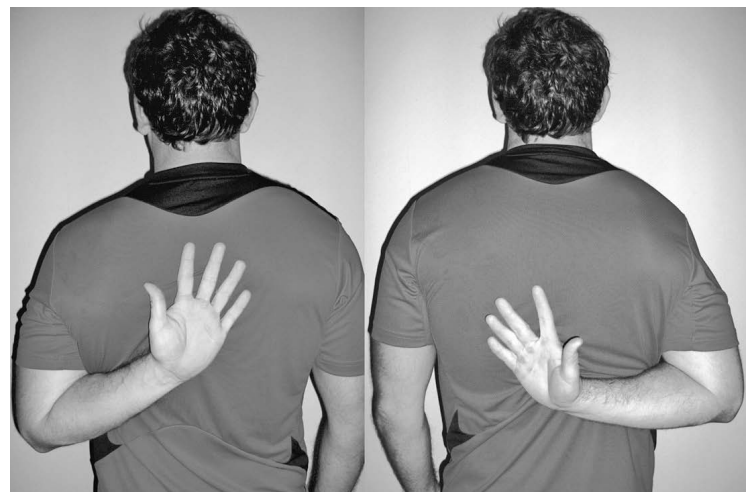**Figure 3B:** Axial CT bone window image at the glenoid level reveals the internally rotated glenoid fragment (black arrow) as well as an additional minimally displaced comminuted fracture of the scapular body (white arrow).



**Figure 3C:** Three-dimensional surface-rendered CT image viewed from the posterior aspect, clearly illustrates the significant displacement of the triangular fragment arising from the glenoid neck and axillary border of the scapula (white arrow), as well as the comminuted fracture of the scapular body (black arrows).



**Figure 3D:** A serial radiograph of the shoulder obtained in abduction and external rotation 6 years after the injury reveals complete healing of the fractures with significant malunion consisting of a 4 cm long triangular subglenoid fragment (white arrow) and a persistent defect in the axillary border of the scapula (\*).



**Figure 3E:** Clinical photographs obtained 6 years after the initial injury reveal restriction of active internal rotation, extension and adduction of the right shoulder resulting in a 7.5 cm discrepancy between the right and left side on the inferior Apley's scratch test. Note that the right hand cannot reach as high as the left.

continued pain in the right scapula and decreased ranges of motion of the right shoulder. The deep muscle pain at presentation ranged from 1 on a scale of 10 while at rest and became sharp rated 5/10 at its worst with internal and external rotation or abduction. Additionally, the pain was aggravated by lifting objects overhead and rotation of the shoulder in a throwing motion. Active stretching and rest provided pain relief. The pain did not radiate into his upper extremity and did not disrupt sleep except when he rolled onto his right side while recumbent.

### *Physical Examination*

The patient was 69" tall, 185 lbs., right handed and appeared physically fit. Vital signs, gait, neurologic examination and ambulation were all normal. Active range of motion of the right shoulder was full and pain free in combined flexion and adduction. Active external rotation was 100% restricted and provoked pain at the posterior axillary fold, and combined internal rotation, extension and adduction (Apley's inferior scratch test) of the right shoulder revealed significant restriction on the right compared with the left with a 20 cm discrepancy from side to side. The active range of abduction of the right shoulder was full but provoked pain over the supraspinatus muscle. The right supraspinatus press test was mildly positive for pain. Myofascial trigger points and adhesions were detected in the right rhomboid, deltoid, infraspinatus, supraspinatus, teres minor, subscapularis, latissimus dorsi, upper trapezius, levator scapulae and cervical spine musculature. These findings were most pronounced in the right infraspinatus muscle which was significantly atrophic compared with the left.

This patient was diagnosed at the chiropractic college health center with post-traumatic myofascial parascapular trigger points, myofasciitis, muscular adhesions and weakness in the right shoulder musculature involving principally the infraspinatus muscle. He was seen seven times over a 2 month period. Treatment consisted of trigger point therapy, progressive isometric resistance using therapeutic bands, manual muscle release methods, instrument assisted techniques aimed at preventing soft tissue adhesions, and passive progressive mobilizations to increase range of motion. The patient was also placed on a muscle strengthening regimen at his gymnasium three times per week to strengthen the parascapular musculature. Diversified chiropractic manipulation and mobiliza-

tion of the cervical spine, thoracic spine and ribs were administered on each visit to address joint restrictions as indicated.

### *Outcome*

The patient reported a significant increase in muscle strength after 2 months. The active range of motion in external rotation improved from 100% restriction to 80% restriction in two months. The inferior Apley's scratch test improved somewhat from the 20 cm pre-treatment discrepancy to a 14 cm post-treatment discrepancy. At the conclusion of the seven visits, he continued to have mild pain which was graded at 2 of 10 with occasional exacerbations as high as 5 after vigorous workouts. He reported that the pain was still occasionally severe enough to awaken him at night as a result of rolling onto his right shoulder. After the two month treatment period, the patient was then lost to follow-up.

Six years after the initial injury, the patient was contacted and he reported for follow-up evaluation and radiographic examination. At this point, he was continuing to exercise and reported that the pain was much less frequent, and was provoked only by activities such as throwing a ball, absorbing body contact in rugby, and lying on his right side. Follow-up radiographs revealed that the fracture of the scapular neck had healed with significant malunion in which a 4 cm long triangular subglenoid fragment remained unattached to the axillary border of the scapular body. While the margins of this projection of bone were rounded and smooth, it projected into the axillary soft tissues (Figure 3D). Examination revealed significant generalized atrophy of the muscles of the right shoulder girdle compared to the left. Ranges of motion were all full and bilaterally symmetric except the inferior Apley's scratch test which exhibited a 7.5 cm discrepancy in ranges of motion from right to left (Figure 3E). He completed a DASH outcome questionnaire that revealed a 23% disability.<sup>14</sup>

### *Discussion*

Scapular fracture diagnoses are commonly missed or delayed owing to the extent of associated injuries overshadowing the scapula, chest trauma CT scans not covering the entirety of the scapula, unusual mechanisms of injury, low levels of consciousness, or because pain is being controlled by corticosteroid injection for other injuries.<sup>15</sup>

Scapular fractures have proven to be particularly significant due to their anatomic proximity to vital structures including the head, lungs, cervical spine and brachial neurovascular structures.<sup>2,3</sup> It has been observed that 81-96% of individuals with scapular fractures have associated injury.<sup>1, 16,17</sup> The most common associated injuries in these patients are rib fractures.<sup>11,18</sup> However, other, more serious injuries can include hemothorax, pneumothorax, pulmonary contusion, skull fractures, permanent cord injuries, brachial plexus injuries, complex regional pain syndrome, Horner's Syndrome and subclavian, axillary or brachial artery injury.<sup>1,3,10</sup> As a result, the mortality rate of individuals with scapular fractures, although not usually direct, has been reported to range from 2% to as high as 14.3%.<sup>10,11,13</sup>

While the vast majority of scapular fractures are managed quite successfully without surgery, most agree that surgical management should be considered for severely displaced injuries – most commonly: (1) significantly displaced fractures of the glenoid cavity (glenoid rim and glenoid fossa), (2) significantly displaced fractures of the glenoid neck, and (3) double disruption of the superior shoulder suspensory complex (SSSC) in which one or more elements of the scapula are significantly displaced.<sup>9</sup>

Currently, 99% of all isolated scapular body fractures are being managed non-operatively with an 86% success rate.<sup>5</sup> Because of its abundant blood supply, with appropriate care, scapular fractures can heal rapidly under conservative management.<sup>8</sup> However, when treating these fractures, there are consequences that can occur even with the current physiotherapy techniques that should be considered. For example, some patients with displaced scapular body fractures may experience a snapping or grating sensation at the scapulothoracic interface with movement through ranges of motion.<sup>1</sup> Persistent soft tissue irritation secondary to bone irregularity, callus formation of displaced fragments (as seen in Case 3), and heterotopic bone formation are also possibilities, which in some cases may require excision of the mass or irregularity for pain relief.<sup>4,19</sup> Other causes of patient dissatisfaction after scapular healing can include prolonged weakness, pain, crepitations or a disfiguring bump, most common in multi-trauma patients.<sup>12</sup> Although nonunion is rare, when a patient complains of persistent shoulder pain after conservative treatment, this possibility must be considered.<sup>20,21</sup>

Following fracture union, in our experience, adjunctive manual muscle procedures such as myofascial release, trigger point therapy, and instrument assisted techniques can be performed to relieve spasms and prevent soft tissue adhesions amongst the rotator cuff muscles, levator scapulae, paraspinals, deltoids, rhomboids, latissimus dorsi and trapezius. Furthermore, mobilization of costovertebral articulations and chiropractic manipulations of the appropriate cervical and thoracic motion segments were useful in facilitating biomechanical adaptation and symptomatic manifestations in each case presented here as well as in a case report by Deltoff et al.<sup>22</sup>

All three patients in this case series received conservative management for their injuries. The first patient who received 16 weeks of treatment completed a DASH questionnaire at 3 years post injury that revealed functional improvement to 2% disability. The second patient who scored 81% disability 3 weeks after his initial injury, received 11 weeks of treatment, and at nineteen weeks had improved to 5% disability. The third patient with a more significantly displaced, comminuted fracture that resulted in healing with malunion scored a 23% disability on the DASH questionnaire completed 6 years after his initial injury.

## Conclusion

Research indicates that the vast majority of patients with comminuted scapular fractures can be treated with an immobilizing sling or brace and some form of manual therapy and will heal completely within 6 weeks.<sup>9</sup> Although uncommon for such cases of scapular fracture to present in chiropractic offices, these three cases suggest that chiropractic management can help these individuals to achieve symptomatic relief, progressive functional improvements and in most cases, little need for long-term follow-up care.

## References

1. Ada JR, Miller ME. Scapular fractures: Analysis of 113 cases. *Clin Orthop Relat Res.* 1991; 269: 174-180. PubMed PMID: 1864036.
2. Armstrong CP, Van der Spuy J. The fractured scapula: Importance and management based on a series of 62 patients. *Injury.* 1984; 15 (5): 324-9. PubMed PMID: 6706394.
3. McGahan JP, Rab GT, Dublin A. Fractures of the scapula. *J Trauma.* 1980; 20 (10): 880-3. PubMed PMID: 6252325.

4. McGinnis M, Denton JR. Fractures of the scapula: A retrospective study of 40 fractured scapulae. *J Trauma*. 1989; 29 (11): 1488-93.
5. Zlowodzki M, Bhandari M, Zelle BA, Kregor PJ, Cole PA. Treatment of scapula fractures: Systematic review of 520 fractures in 22 case series. *J Orthop Trauma*. 2006; 20 (3): 230-3.
6. Desault, P.J. A treatise on fractures, luxations and other affections of the bones. Philadelphia: Fry and Kammerer, 1805: 57-67.
7. Wilson PD. Experience of the management of fractures and dislocations (Based on an analysis of 4390 cases) by Staff of the Fracture Service MGH, Boston. Philadelphia: JB Lippincott, 1938.
8. Cole PA. Scapula fractures. *Orthop Clin North Am*. 2002; 33 (1): 1-18, vii.
9. Goss TP. Scapular fractures and dislocations: Diagnosis and treatment. *J Am Acad Orthop Surg*. 1995; 3 (1): 22-33. PubMed PMID: 10790650.
10. Thompson DA, Flynn TC, Miller PW, Fischer RP. The significance of scapular fractures. *J Trauma*. 1985; 25 (10): 974-7. PubMed PMID: 4046086.
11. Veysi VT, Mittal R, Agarwal S, Dosani A, Giannoudis PV. Multiple trauma and scapula fractures: So what? *J Trauma*. 2003; 55 (6): 1145-7.
12. Gosens T, Speigner B, Minekus J. Fracture of the scapular body: Functional outcome after conservative treatment. *J Shoulder Elbow Surg*. 2009; 18 (3): 443-8. PubMed PMID: 19393934.
13. Salimi J, Khaji A, Karbakhsh M, Saadat S, Eftekhari B. Scapular fracture: Lower severity and mortality. *Sao Paulo Med J*. 2008; 126 (3): 186-9. PubMed PMID: 18711659.
14. Hudak P, Amadio PC, Bombardier C, and the Upper Extremity Collaborative Group. Development of an Upper Extremity Outcome Measure: The DASH (Disabilities of the Arm, Shoulder, and Hand). *Am J Ind Med*. 1996; 29:602-608.
15. Tadros AM, Lunsjo K, Czechowski J, Abu-Zidan FM. Causes of delayed diagnosis of scapular fractures. *Injury*. 2008; 39 (3): 314-8. PubMed PMID: 18243201.
16. Imatani RJ. Fractures of the scapula: A review of 53 fractures. *J Trauma*. 1975; 15 (6): 473-8.
17. Scavenius M, Sloth C. Fractures of the scapula. *Acta Orthop Belg*. 1996; 62 (3): 129-32. PubMed PMID: 8890536.
18. Dimitroulias A, Molinero KG, Krenk DE, Muffly MT, Altman DT, Altman GT. Outcomes of nonoperatively treated displaced scapular body fractures. *Clin Orthop Relat Res*. 2011; 469 (5): 1459-65. PubMed PMID: 21161746.
19. Guttentag IJ, Reichtine GR. Fractures of the Scapula: A Review of the Literature. *Orthop Rev*. 1988; 17 (2): 147-58. PubMed PMID: 3050806.
20. Ferraz IC, Papadimitriou NG, Sotereanos DG. Scapular body nonunion: A case report. *J Shoulder Elbow Surg*. 2002; 11 (1): 98-100. PubMed PMID: 11845159.
21. Gupta R, Sher J, Williams GR Jr, Iannotti JP. Non-Union of the scapular body. A case report. *J Bone Joint Surg Am*. 1998; 80: 428-30.
22. Deltoff MN, Bressler HB. Atypical scapular fracture: A case report. *Am J Sports Med*. 1989; 17 (2): 292-5. PubMed PMID: 2757135.