

# Atypical presentation of cauda equina syndrome

Lisa A Caputo, BSc, DC, FCCS(C)<sup>†</sup>

Michael D Cusimano, MD, MPHE, FRCS(C), DABNS, PhD\*

*Cauda equina syndrome (CES) has been described in the literature as a clinical entity consisting of low back pain, bilateral leg pain with motor and sensory deficits, genitourinary dysfunction with overflow incontinence or retention, and faecal incontinence. CES has been recognised as a rare complication of spinal manipulative therapy, and is an absolute contraindication to this type of therapy. A case of CES that presented in an atypical manner is presented, highlighting the lack of leg symptomatology, but with the presence of painless urinary retention. A definition of CES as a condition presenting with bladder dysfunction and possible motor and/or sensory loss in the region of sacral and/or lumbar dermatomes is discussed. Evaluation of patients with lumbar disc pathology who are suspected of suffering from CES should include questioning regarding urinary difficulty and neurologic examination of the sacral plexus, including sensation; and may include advanced imaging such as contrast computerized tomography (CT) scan or magnetic resonance imaging (MRI). Immediate referral for consideration of decompression surgery is recommended for optimal recovery of neurologic function. Clinicians should be knowledgeable of the various forms CES can present in, and maintain a high index of suspicion for this condition in patients with suspected lumbar disc herniation or urinary dysfunction. (JCCA 2002; 46(1):31–38)*

**KEY WORDS:** low back pain, disc herniation, cauda equina syndrome, cauda equina compression, bladder dysfunction.

*Le syndrome de la queue de cheval a été documenté comme étant une entité clinique qui consiste en des douleurs lombaires, des douleurs bilatérales aux jambes accompagnées de déficiences motrices et sensorielles, de dysfonctionnement génito-urinaire accompagné d'incontinence par regorgement ou de rétention, et d'une incontinence fécale. Le syndrome est reconnu comme une rare complication suivant une manipulation vertébrale et constitue une contre-indication majeure lors de ce genre de thérapie. On a présenté un cas de la présence du syndrome, de manière atypique mettant en évidence le manque de symptomatologie, accompagné de rétention urinaire sans douleur. Nous analysons le syndrome en tant que condition accompagnée de dysfonctionnement de la vessie et d'une perte motrice ou sensorielle dans la région du sacrum ou des lombes. L'évaluation des patients qui souffrent d'une pathologie du disque lombaire et qui sont susceptibles de souffrir du syndrome de la queue de cheval doit comprendre des questions sur les difficultés urinaires et un examen neurologique de plexus sacré, y compris la sensation. Elle peut aussi comprendre une imagerie avancée telle qu'une tomographie de contraste par ordinateur ou une imagerie par résonance magnétique (IRM). L'orientation immédiate du patient vers un spécialiste pour évaluer la possibilité d'effectuer une décompression chirurgicale est recommandée pour une récupération optimale des fonctions neurologiques. Les cliniciens doivent connaître les différentes formes du syndrome et conserver un large index de soupçons pour cette condition, chez les patients susceptibles de présenter une hernie discale au niveau des lombes ou des troubles uninaires. (JACC 2002; 46(1):31–38)*

**MOTS CLÉS :** douleurs lombaires, hernie discale, syndrome de la queue de cheval, compression en queue de cheval, dysfonctionnement de la vessie.

<sup>†</sup> Division of Clinical Education and Research, Canadian Memorial Chiropractic College, Toronto, Canada.

\* Division of Neurosurgery, St. Michael's Hospital, University of Toronto, Toronto, Canada.

Address correspondence to: Dr. Lisa Caputo, 1900 Bayview Avenue, Toronto, Ontario, Canada M4G 3E6.

© JCCA 2002.

## Introduction

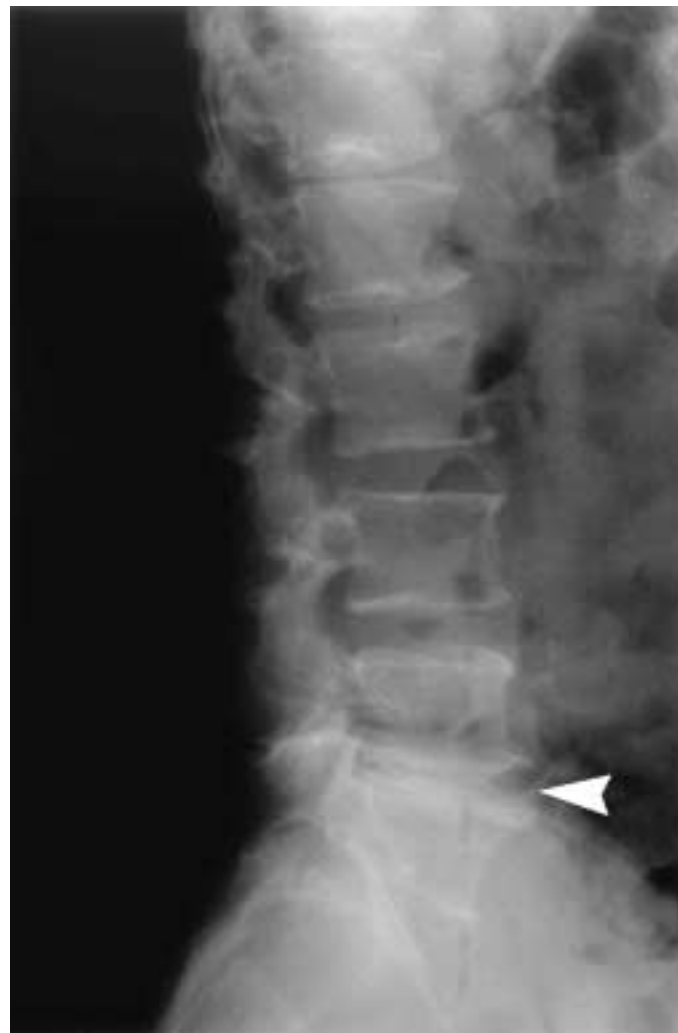According to the Canadian Job Analysis for Chiropractic, patients presenting to a chiropractor typically do so for musculoskeletal complaints such as low back pain (LBP), neck pain or headaches.<sup>1</sup> Patients presenting with LBP are typically diagnosed with spinal joint dysfunction/facet irritation, muscular strain/tear, or intervertebral disc herniation, and are routinely managed with the use of spinal manipulative therapy (SMT).<sup>1</sup>

The annual incidence of intervertebral disc herniation in the population has been estimated at 0.1–0.5%.<sup>2</sup> Chiropractors can then be expected to see a significant number of these cases. One important condition that is associated with disc herniation, and for which SMT is absolutely contraindicated is cauda equina syndrome (CES).<sup>3</sup> CES has been described as a clinical entity consisting of a constellation of low back pain, bilateral leg pain and weakness, saddle anaesthesia, genitourinary dysfunction with overflow incontinence or retention, and loss of rectal sphincter tone, sometimes with faecal incontinence.<sup>2,4</sup> However, presentation of CES can vary dramatically from this typical presentation in the early stages of compression<sup>5,6</sup> and, as such, it is important for the clinician to be able to identify those signs and symptoms suggestive of CES. Patients presenting with CES should be referred immediately for surgical consideration, since delay in treatment may have significant adverse effects for neurological recovery.<sup>7</sup>

The purpose of this paper is to discuss a case report of CES with an atypical presentation, and to review some of the atypical signs and symptoms which may delay diagnosis of this condition.

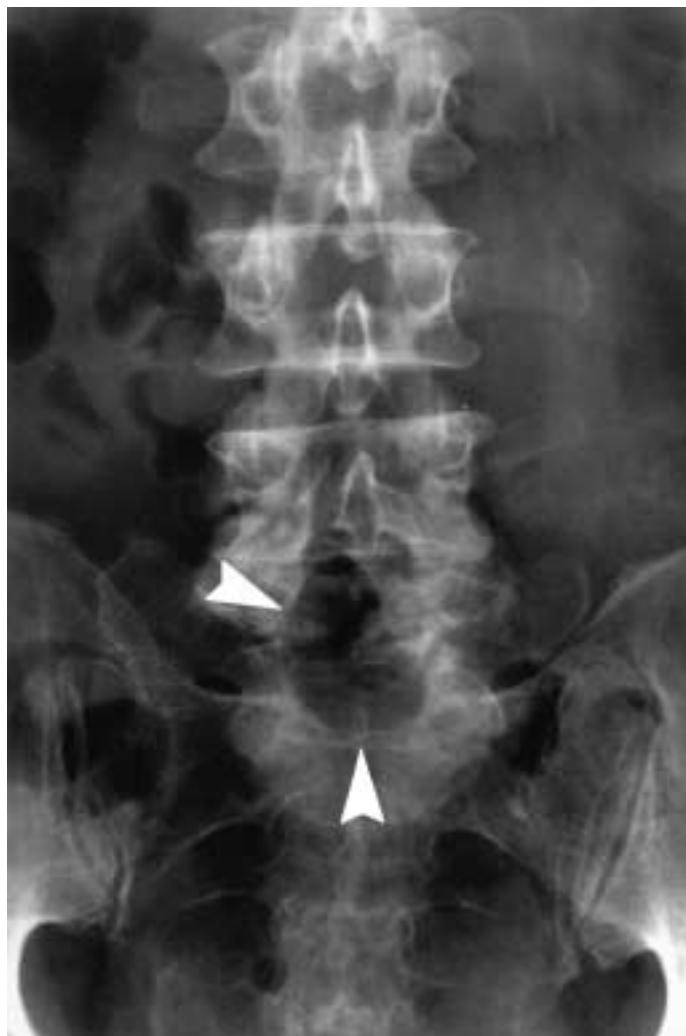## Case report

A 53-year-old male manager presented to an Emergency physician with complaint of low back and leg pain. The pain had begun a week previously, and was brought on after sneezing. Immediately afterwards, the patient experienced back “spasms” in the lower lumbar region, with radiating pain into the left buttock and anterior thigh. He had presented to his family physician three days later and was prescribed analgesics. At the time of the presentation, the patient reported that the leg pain was getting progressively worse, and was aggravated with activity, sitting, standing and coughing, and was relieved by resting prone. Previous medical history was significant for lumbar surgery 20 years ago, to remove a herniated lumbar disc.



**Figure 1A** Plain film radiograph, lateral view of lumbar spine demonstrating 6 lumbar-type vertebrae, and severe degenerative disc disease at L5-6 (arrowhead).

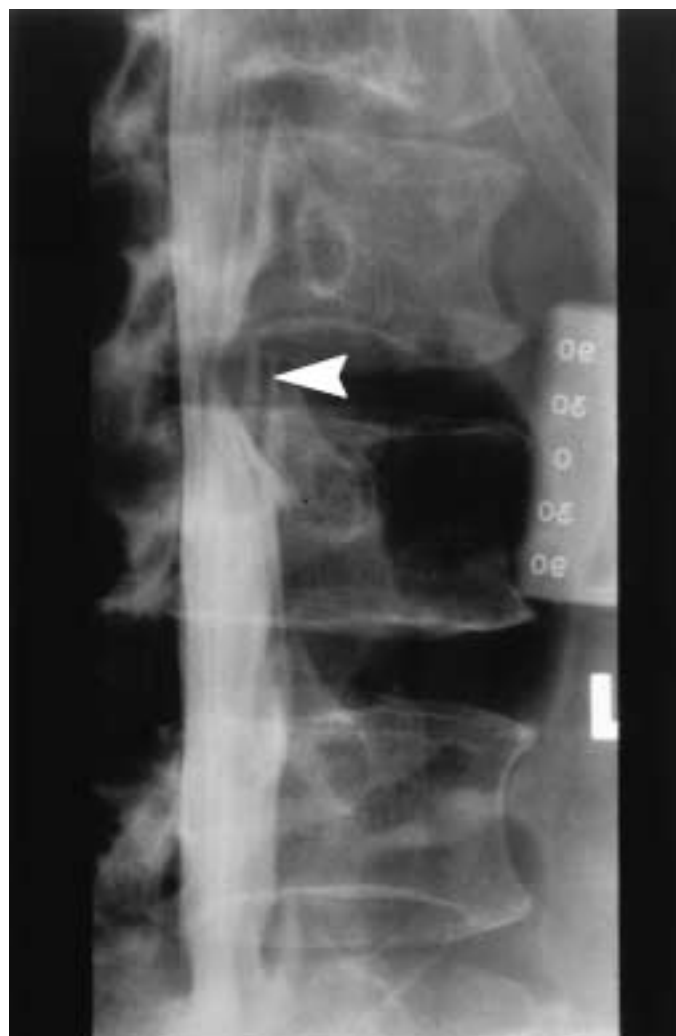Physical examination revealed a decreased lumbar range of motion, with an antalgic gait on the left. Straight leg raise and Bowstring tests were negative bilaterally, however, femoral nerve root stretch was positive on the left. Neurologically, the patient was intact. Rectal tone was normal, as was perineal sensation. Plain film radiographs taken at the time revealed six lumbar type vertebrae (Figure 1A). Severe degenerative disc disease was noted at L5–6, and evidence of a laminectomy procedure at L5–6 was noted (Figures 1A and 1B). There were no deformities or pathological entities noted. The patient was diagnosed



**Figure 1B** Plain film radiograph, anteroposterior view of lumbar spine demonstrating previous laminectomy at L5 and L6 (arrowheads).

with mechanical low back pain, was prescribed analgesics and laxatives, and told to follow up with his medical doctor if needed.

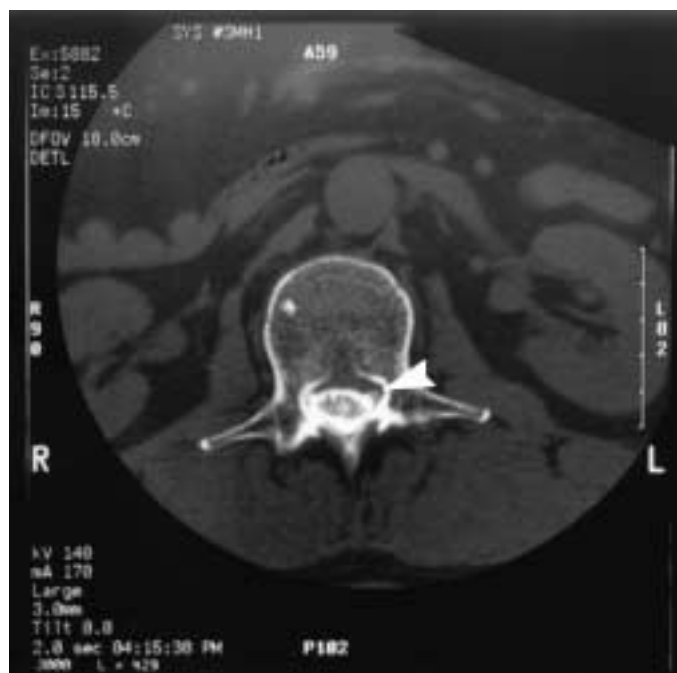Nine days later, the patient represented to the Emergency ward complaining again of low back and leg pain, as well as a 15 hour history of being unable to urinate. As well, he had not had a bowel movement in three days. There were no complaints of numbness or weakness in the left leg. The patient denied any right leg symptoms. In retrospect, the patient reported that over the previous week he had experienced some dribbling of urine on several



**Figure 2** Plain film radiograph with myelography, oblique view of lumbar spine demonstrating indentation of myelographic dye column, indicative of an extrathecal space-occupying lesion.

occasions.

Physical examination again revealed no nerve root tensions signs. Lower limb motor testing was 5/5 bilaterally. Sensory testing revealed an area of decreased sensation over the left anterior thigh. Rectal tone was intact, however the rectum was found to be full of impacted stool. Catheterization removed approximately 1 litre of residual urine, and the patient required an indwelling catheter at time of examination. Advanced imaging with myelography (Figure 2) and computed tomography (CT) with contrast revealed the presence of left-sided L2–3 disc



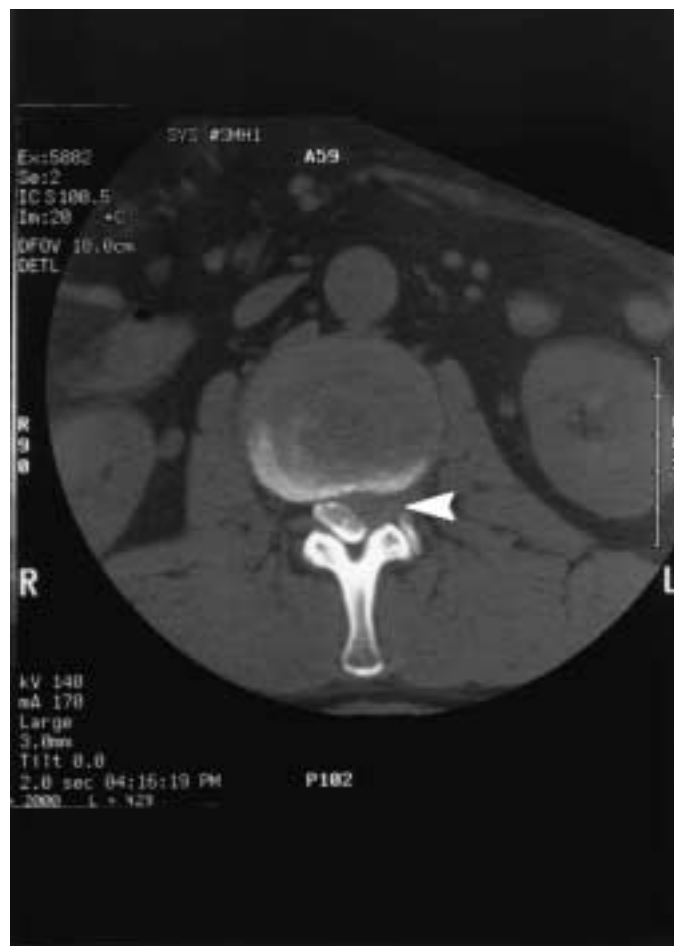**Figure 3A** Axial computerized tomography scan with contrast at L1 level, demonstrating lack of thecal sac indentation and preservation of L2 nerve root within the canal (arrowhead).

herniation involving the L2, L3 nerve roots and cauda equina (Figures 3A and 3B). A diagnosis of a posterolateral disc herniation at L-2 resulting in cauda equina compression was made, and the patient underwent an uncomplicated laminectomy to remove the sequestered fragment at that level.

In follow-up two months later, the patient exhibited full but guarded lumbar range of motion, and no neurological deficits. Bladder function was still impaired, and the patient was on a regimen of self-catheterization and medication (Noroxin) to assist with voiding. Six months after this, he remained on medication (Hytrin) to assist micturition, however urological follow-up reports noted he had a normal voiding and urine flow pattern.

## Discussion

Cauda equina syndrome (CES), first reported in the medical literature in 1929,<sup>8</sup> is thought to be rare. With an estimated occurrence of 1 to 16% of lumbar disc herniation cases that undergo surgery,<sup>9,10</sup> annual incidence of CES has been estimated at 1 in 33,000 to 100,000.<sup>2</sup>



**Figure 3B** Axial computerized tomography scan with contrast at L2 level, demonstrating severe compression of the thecal sac by lumbar disc herniation, and obliteration of the L2 nerve root (arrowheads).

## Etiology and pathophysiology

The signs and symptoms of CES are due to compression of the cauda equina (CE) by a space-occupying lesion.<sup>9</sup> One of the most commonly reported etiologies of CES is a herniated or extruded lumbar disc.<sup>6</sup> Other causes reported in the literature include spinal tumours (both intradural and extradural),<sup>11-13</sup> haematoma,<sup>14</sup> ankylosing spondylitis,<sup>15</sup> fracture,<sup>16</sup> infection such as osteomyelitis or abscess,<sup>17</sup> and spinal manipulative therapy (SMT).<sup>18</sup>

Several anatomic features of the CE are thought to make it more sensitive to the effects of compression. First, the nerve roots of the CE are covered with a sparse layer of connective tissue, as opposed to the thicker epineurium

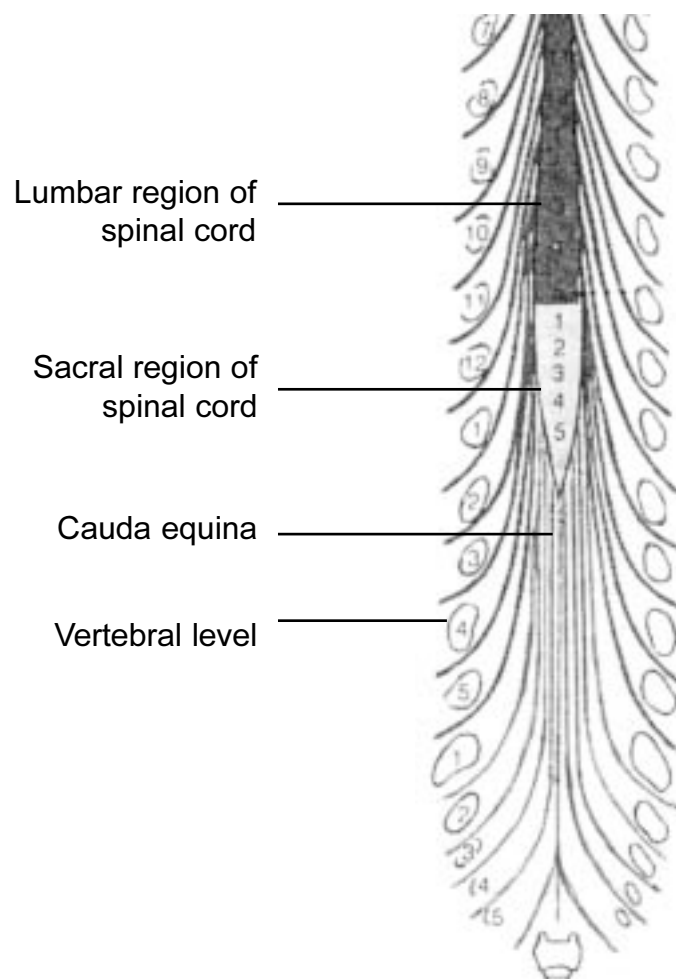
seen with peripheral nerves. This connective tissue layer offers relatively little protection against tensile forces such as a protruding disc deforming the nerve root.<sup>19</sup> Second, unlike the rest of the spinal cord and peripheral nerves, the CE lacks a regionalized segmental blood supply. This feature has lead some authors to postulate the presence of a zone of relative hypovascularity within the central portion of the nerve root, which would make them more susceptible to ischemic effects from compression.<sup>19</sup> Using a live porcine model, Rydevik et al. found that when the nerve roots are compressed past a critical pressure (approximately 50–75 mm Hg), neurological insult and deficits ensue, as measured by decreased electromyographic activity and sensory evoked potentials.<sup>19,20</sup>

### **Clinical presentation**

As discussed earlier, classical presentation of CES includes low back pain with a complex of bilateral lower motor neuron symptoms in the lower limbs (pain, weakness, loss of deep tendon reflexes) and bowel and bladder changes.<sup>6</sup> However, several case series have reported varying symptomatic presentations of CES in conjunction with urinary retention. These include reports of CES with unilateral leg symptomatology,<sup>6,10</sup> unilateral or bilateral saddle anaesthesia with or without leg symptomatology,<sup>6,10</sup> and CES with complete absence of signs and symptoms in the lower limbs.<sup>21,22</sup> For instance, in a series of 470 patients operated on for CES, Young reported that 39% had no neurological signs in the lower limbs.<sup>21</sup> Similarly, O'Laoire reported two of a series of 29 patients diagnosed with CES who presented with acute bladder retention and a lack of sensory deficit.<sup>22</sup> Finally, there are a few case studies reporting patients presenting with urinary retention with no history of low back pain, which were subsequently discovered to be due to an undiagnosed lumbar disc herniation.<sup>23,24</sup> Due to this variability in presentation, Kostuik proposed a new definition of CES as a "condition of urinary dysfunction with motor or sensory loss caused by a known or suspected disc herniation".<sup>6</sup>

The varied clinical presentation of CES can be attributed to the level at which compression takes place within the spinal canal. The CE is arranged with the higher nerve roots travelling more laterally, and the lower sacral nerve roots travelling within the medial aspect of the cauda (see Figure 4).<sup>25</sup> The most common level of disc herniation causing CES is L4–5, with L5–S1 occurring less fre-

quently, and L3–4 fairly rarely.<sup>22,26,27</sup> A large compressive midline lesion at the L4–L5 disc level will only affect the lower lumbar and sacral nerve roots, while lesions which occur at a higher spinal level will have the potential to affect the upper lumbar nerve roots as well. A large postero-laterally located disc herniation, as in the case presented here, can both impinge on the nerve root exiting below it and compress the rest of the CE through a lateral shift within the spinal canal. What is most interesting about this case is its lack of involvement of the other spinal nerve roots, while still compromising bladder innervation. We have no neurological explanation for this finding.



**Figure 4** Drawing depicting a postero-anterior view of the spinal cord, demonstrating the orientation of spinal nerve roots within the cauda equina. Reproduced with permission from Hall-Craggs, ECB. *Anatomy as a basis for clinical medicine*, third edition. London, Williams and Wilkins, 1995. p. 48.

Bladder innervation arises from the sacral plexus and pelvic nerves (parasympathetic, S2–4), and from the hypogastric nerves (sympathetic, L2–4). Parasympathetic innervation of the bladder is considered the more crucial, as it controls detrusor muscle tone (which contracts during micturition to aid in emptying the bladder) and transmits sensation from the bladder to higher micturition centres.<sup>28</sup> Central disc herniations may impinge only the sacral roots, avoiding the lumbar roots and causing neither motor nor reflex changes in the lower limb but causing peripheral denervation of the bladder.<sup>22</sup> This lower motor neuron lesion of the nerve roots presents with the patient being unable to appreciate bladder sensation or void (due to flaccid paralysis of the detrusor), therefore as a painless retention.<sup>5,22</sup> Jones et al.<sup>29</sup> have suggested that with a lesser degree of compression of the lower sacral roots, as in a large posterolateral disc herniation, hyperexcitability of the sensory and motor fibres would occur initially, resulting in “irritative” bladder symptoms. This presentation commonly results in urinary frequency, urgency, and nocturia. Progressive compression would eventually result in loss of bladder sensation, atonicity and difficulty in voiding.<sup>29</sup>

If, however, the disc herniation impinges on the spinal cord, this can lead to the destruction of the connections to higher micturition centres, which normally act as both inhibitory and facilitatory input to the bladder.<sup>28</sup> This results in a reflexive bladder devoid of higher control, emptying at a certain volume without patient awareness or control.

### **Patient examination**

As illustrated in this case, it is prudent in a case of low back pain to screen a patient for bladder dysfunction, even if they do not demonstrate a classic CES presentation. Pertinent screening questions should include enquiring about frequency of voiding, difficulty in initiating a stream of urine, the ability to suppress the urge to void, presence or absence of urinary incontinence, loss of bowel control, loss of ejaculatory ability, and loss of sensation in the perineal or genital region.<sup>30</sup> The patient should be questioned regarding the use of anti-cholinergics and other medications which may affect micturition, previous surgical procedures to the lower urinary tract or lumbar spine, or obstetrical history if applicable.<sup>30</sup>

While the classical presentation of CES will present with evidence of sciatic nerve root irritation, such as a

decreased straight leg raise (SLR) or positive Braggard’s or Bowstring signs, a high lumbar disc lesion will often be missing these features. A femoral nerve root stretch, which tractions L2–4 nerve roots, should be performed to assess for radicular signs from a high disc lesion. Similarly, the lower extremity deep tendon reflexes may be spared in a high disc lesion, as was the situation in this case study. More appropriate tests for a disc lesion at this level include assessment of strength of knee extension or hip flexion (L2–4 nerve roots), wasting of the quadriceps, sensation on the anterior aspect of the thigh, and in males the cremasteric reflex. A space-occupying lesion that does not affect the spinal cord (i.e. from the conus medullaris on down) will not cause an upper-motor neuron lesion, therefore pathologic reflexes should be absent in a disc herniation at this level.

Physical examination should also emphasise the neurological exam of the sacral plexus. Important procedures to include are assessment of perineal sensation for the modalities of pain, touch and temperature;<sup>7</sup> loss of tone, weakness or presence of wasting of the gluteals; and assessment of the anal wink and (in males) the bulbocavernosus reflex.<sup>10,27</sup> Painless urine retention in CES can result in permanent bladder damage from irreversibly stretching the bladder wall,<sup>31,32</sup> therefore the abdomen should be palpated and percussed for an enlarged bladder in suspected cases.<sup>22</sup> Bedside assessment of post-void residual urine volumes is also very helpful in the hospital setting.

Additional studies recommended for the immediate assessment of CES include myelography with computerized tomography (CT) scan or magnetic resonance imaging (MRI).<sup>33</sup> Advanced studies of bladder function include cystometrography, sphincter electromyography, and flowmetry, which may detect the presence of neurogenic bladder symptoms.<sup>29,30</sup> Plain CT has been found to be unreliable in one study.<sup>7</sup>

### **Treatment**

Surgical decompression, usually via laminectomy and discectomy is usually recommended if the offending lesion is a disc herniation.<sup>26</sup> Previous authors have described CES as a “surgical emergency”, since earlier decompression may reverse some neurological deficit, prevent irreversible neurological paresis, and disability, and possibly reduce post-operative complications such as chronic

pain.<sup>22,26,27</sup> Major factors found to influence surgical outcomes are severity of the pre-operative bladder sphincter disturbance, extent of bladder sensory loss, and severity of sensory loss in the perineal area.<sup>22</sup>

In a retrospective case series, Shapiro<sup>26</sup> found 100% resolution of bladder and bowel symptomatology if the cauda equina was decompressed within 48 hours; this percentage dropped to 33% if decompression took place after this time period. In contrast, Kostuik<sup>6</sup> in his case series found no correlation between the length of time of onset of symptoms to surgery and extent of recovery of function. Similarly, in an experimental animal model, Delmarter<sup>34</sup> found that dogs whose cauda equina had been artificially compressed all recovered function within 6 weeks, regardless of duration of compression. Despite these studies, all authors still recommend that surgery occur as soon as possible to maximise functional recovery, especially of micturition.

#### ***Cauda equina syndrome and spinal manipulative therapy***

Cauda equina syndrome in chiropractic practice has typically been discussed in the literature as a complication of SMT to the lumbar spine.<sup>18,35,36</sup> In a 1992 book chapter, Dvorak<sup>36</sup> quotes the results of a case series where one case of CES secondary to SMT was recorded for 2.26 million manipulations. In his 1992 case series, Haldeman<sup>18</sup> states that the incidence of CES secondary to SMT “approaches one in many millions of treatments”, even when taking into account the potential for unreported cases.

Terrett and Kleynhans<sup>37</sup> found that CES was mainly a complication of SMT associated with injury to intervertebral disc, and cite 65 cases reported in the literature. They found CES to be more common with SMT under anaesthesia, and that only 20% of reported cases could be attributed to a chiropractor. The authors felt that in some cases the temporal relationship between the administration of SMT and the onset of CES was questionable, and that the risk of CES with SMT may be exaggerated as a result.

Overall, the biggest risk to the patient in all cases was the failure of the practitioner to recognise the presence of acute CES, thereby postponing appropriate therapy.<sup>35,37</sup> Therefore, it is necessary for all clinicians to be knowledgeable of the various presentations of CES, and to maintain a high index of suspicion for this clinical entity with patients complaining symptoms suggestive of discopathy,

or difficulties with bladder function.

#### **Conclusion**

Cauda equina syndrome can be recognised by a clinical pattern including bladder dysfunction (inability to void or incontinence), with possible motor and/or sensory loss in the region of the sacral and/or lumbar roots, secondary to a mass lesion in the cauda equina. In order to recognise CES, the clinician must perform regular neurological examinations of the lumbar and sacral roots to assess for neurological compromise. If CES is suspected, immediate referral to a hospital emergency ward or neurosurgical colleagues is appropriate for diagnostic imaging and possible surgery.

#### **References**

- 1 National Board of Chiropractic Examiners, International Division. Job analysis of chiropractic in Canada. Colorado: The Board of Chiropractic Examiners, 1993.
- 2 Deyo RA. Non-operative treatment of low back disorders: differentiating useful from useless therapy. In: Frymoyer JW, editor. The adult spine: principles and practice. New York: Raven Press, 1991: 1559–1560.
- 3 Haldeman S, editor. Principles and practice of chiropractic, 2nd. ed. Norwalk: Appleton and Lange, 1993.
- 4 Floman Y, Wiesel SW, Rothman RH. Cauda equina syndrome presenting as a herniated lumbar disc. Clin Orthop 1980; 147:234–237.
- 5 Aho AJ, Auranen A, Pesonen K. Analysis of cauda equina symptoms in patients with lumbar disc prolapse. Acta Chirurgica Scand 1969; 135:413–420.
- 6 Kostuik JP, Harrington I, Alexander D, Rand W, Evans D. Cauda equina syndrome and lumbar disc herniation. J Bone Joint Surg Am 1986; 68(3):386–391.
- 7 Dinning TAR, Schaeffer HR. Discogenic compression of the cauda equina: a surgical emergency. Aust N Z J Surg 1993; 63:927–934.
- 8 Dandy WE. Loose cartilage from intervertebral disc simulating tumour of the spinal cord. Arch Surg 1929; 19:660–672.
- 9 Konturri M, Herviainen S, Larmi TKI. Atonic bladder in lumbar disc herniation. Acta Chirurgica Scandinavica 1966; S357:232–235.
- 10 Scott PJ. Bladder paralysis in cauda equina lesions from disc prolapse. J Bone Joint Surg Br 1965; 47:224–235.
- 11 Caputo LA, Cusimano MD. Schwannoma of the cauda equina. J Manipulative Physiol Therap 1997; 20(2):000–000.
- 12 Helweg-Larsen S, Sorensen PS. Symptoms and signs in metastatic spinal cord compression: a study of progression from first symptom until diagnosis in 153 patients. Eur J Cancer 1994; 30A(3):396–398.

- 13 Schweitzer JS, Batzdorf U. Ependymoma of the cauda equina region: diagnosis, treatment and outcome in 15 patients. *Neurosurgery* 1992; 30(2):202–207.
- 14 Boukobza M, Guichard JP, Boissonet M, George B, Reizine D, Gelbert F, Merland JJ. Spinal epidural hematoma: report of 11 cases and review of the literature. *Neuroradiology*; 36(6):456–459.
- 15 Sant SM, O'Connell. Cauda equina syndrome in ankylosing spondylitis: a case report and review of the literature. *Clin Rheumatol* 1995; 14(2):224–226.
- 16 Hilibrand AS, Urquhart AG, Graziano GP, Hensinger RN. Acute spondylolytic spondylolisthesis: risk of progression and neurological complications. *J Bone Joint Surg Am* 1995; 77(2):190–196.
- 17 Faraj A, Krishna M, Mehdian SM. Cauda equina syndrome secondary to lumbar spondylodiscitis caused by *Streptococcus milleri*. *Eur Spine J* 1996; 5(2):134–136.
- 18 Haldeman S, Rubenstein SM. Cauda equina syndrome in patients undergoing manipulation of the spine. *Spine* 1992; 17(12):1469–1473.
- 19 Rydevik BL. Neurophysiology of cauda equina compression. *Acta Orthop Scand (Supp 251)* 1993; 64:52–55.
- 20 Rydevik BL, Pedowitz RA, Hargens AR, Swenson MR, Myers RR, Garfin SR. Effects of acute, graded compression on spinal nerve root function and structure: an experimental study on the pig cauda equina. *Spine* 1991; 16:487–493.
- 21 Young R. Proceeding of the Royal Society of Medicine 1947; 15:233.
- 22 O'Laoire S, Crockard HA, Thomas DJG. Prognosis for sphincter recovery after operation for cauda equina compression owing to lumbar disc prolapse. *BMJ* 1981; 282:1852–1854.
- 23 Sussett JG, Peters ND, Cohen SI, Ghoniem GM. Early detection of neurogenic bladder dysfunction caused by protruded lumbar disk. *Urology* 1982; 20(4):461–463.
- 24 Emmett JL, Love JG. Urinary retention in women caused by asymptomatic protruded lumbar disc: a report of 5 cases. *J Urol* 1968; 99:597–606.
- 25 Hall-Craggs ECB. *Anatomy as a basis for clinical medicine*. London: Williams and Wilkins, 1995:48.
- 26 Shapiro S. Cauda equina syndrome secondary to lumbar disc herniation. *Neurosurgery* 1993; 32(5):743–747.
- 27 Shepherd RH. Diagnosis and prognosis of cauda equina syndrome produced by protrusion of lumbar disc. *BMJ* 1959; 1434–1439.
- 28 Adams RD, Victor M. *Principles of neurology*. 5th ed. New York: McGraw-Hill Inc., 1993.
- 29 Jones DL, Moore T. The types of neuropathic bladder dysfunction associated with prolapsed lumbar intervertebral discs. *Br J Urol* 1973; 45:39–43.
- 30 Bradley WE. The diagnosis and treatment of patients with neurologic dysfunction of the urinary bladder. In: Low PA, editor. *Clinical autonomic disorders*. Boston: Little, Brown; 1993: 573–588.
- 31 Ross JC, Jameson RM. Vesical dysfunction due to prolapsed disc. *BMJ* 1971; 25:752–754.
- 32 Hellstrom P, Kortelainen P, Konturri M. Late urodynamic findings after surgery for cauda equina syndrome caused by a prolapsed lumbar intervertebral disk. *J Urology* 1986; 135:308–312.
- 33 Coscia M, Leipzig T, Cooper D. Acute cauda equina syndrome: diagnostic advantage of MRI. *Spine* 1994; 19(4):475–478.
- 34 Delamarter RB, Sherman JE, Carr JB. Cauda equina syndrome: neurologic recovery following immediate, early or late decompression. *Spine* 1991; 16(9):1022–1029.
- 35 Laderman JP. Accidents of spinal manipulations. *Ann Swiss Chiro Assoc* 1981; 7:161–208.
- 36 Dvorak J, Kranzlin P, Muhlemann D, Walchi B. Musculoskeletal complications. In: Haldeman S, editor. *Principles and practice of chiropractic*. 2nd ed. Norwalk: Appleton and Lange, 1992:549–577.
- 37 Terrett AG, Kleynhans AM. Complications from manipulation of the low back. *Chiro J Austr* 1992; 22(4):129–139.

## Help Support Chiropractic Research

*Become a member of the Canadian Chiropractic Research Foundation*