

# Pronator quadratus – a forgotten muscle: a case report

Robert S Annis, BSc, DC\*

---

*The pronator quadratus (PQ) is a muscle that has been virtually forgotten since it was first documented four centuries ago. Little, if any, functional syndromes have been attributed to the PQ since that time nor have any thorough investigations been conducted with respect to it's anatomy. In this case report, an instance of PQ myofascial pain syndrome is described as well as the examination that lead to the diagnosis.*

(JCCA 2003; 47(1):17–20)

KEY WORDS : pronator quadratus, compartment, syndrome, myofascial pain.

---

## Introduction

The pronator quadratus (PQ) muscle has been described in anatomy texts for a few centuries, nevertheless, very little interest has been expressed in this muscle or it's function. From an anatomical and functional perspective, this muscle has been relatively neglected. A recent article by Stuart<sup>1</sup> has resurrected earlier studies of the anatomy of pronator quadratus indicating the dual-headed nature of this muscle (Figure 1). There was found to be a superficial head (PQs) and a deep head (PQd). Apart from the two papers cited by Stuart and his own investigation of PQ, there is no mention of this muscle's two headed anatomy in anatomical texts or literature.<sup>1</sup> From the investigations of Basmajian and DeLuca<sup>2</sup> using electromyographic examination of PQ, it has been shown that PQ is the prime mover of forearm pronation in all positions of elbow flexion and extension.

As mentioned above, there is little literature on the

---

*Le pronator quadratus (PQ) est un muscle qui a été quasiment oublié depuis sa découverte il y a quatre siècles. Peu, voire aucun, syndrome fonctionnel n'a été attribué au PQ depuis cette époque et aucune recherche n'a été menée sur son anatomie. Ce rapport de cas décrit l'occurrence du syndrome myofascial douloureux du PQ, ainsi que l'examen qui a conduit au diagnostic.*

(JACC 2003; 47(1):17–20)

MOTS CLÉS : pronator quadratus, compartiment, syndrome, douleur myofasciale.

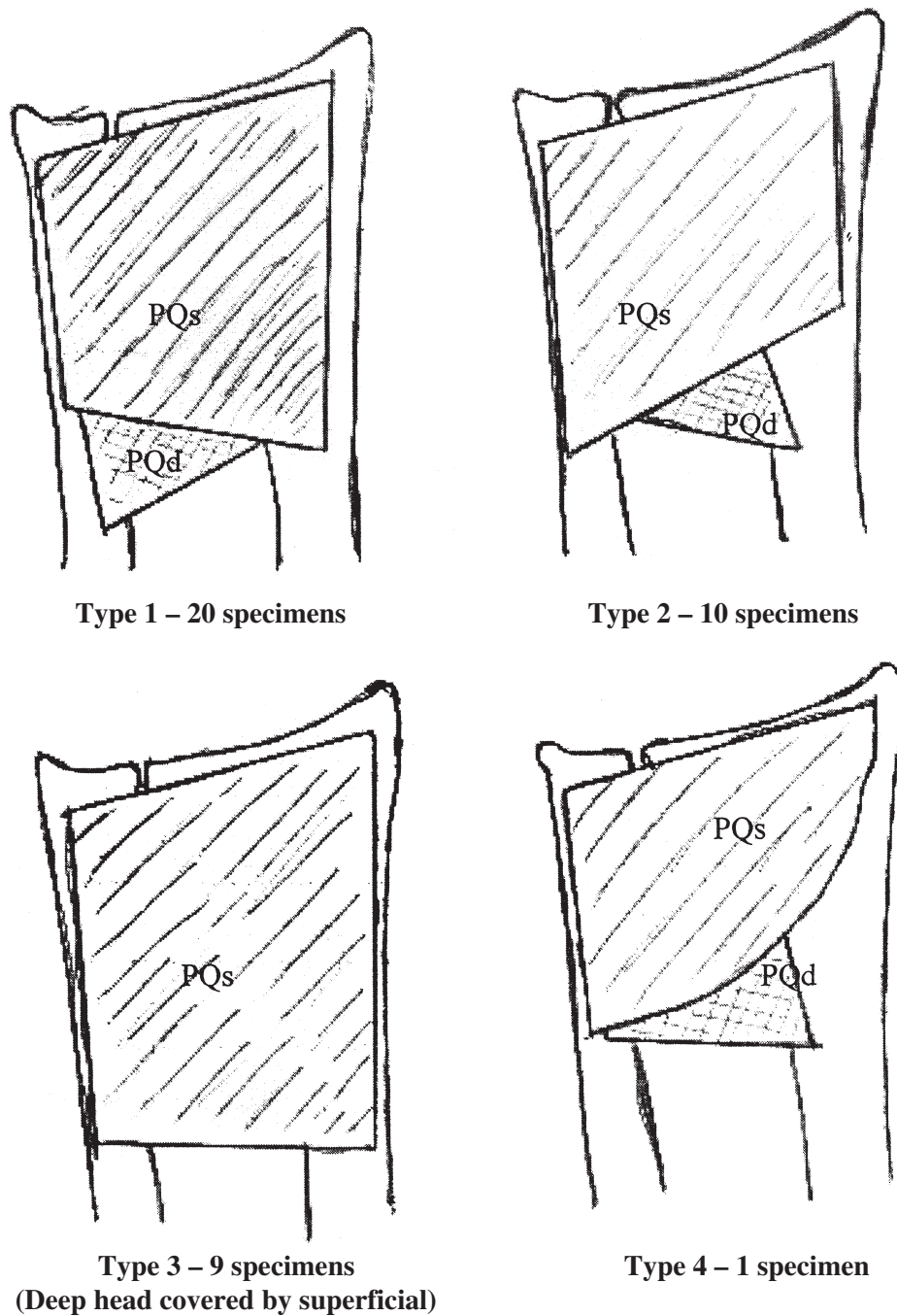
---

anatomy and function of this muscle and even less on any pain syndromes related to the PQ. Only one case report associated with a separate PQ compartment syndrome was located in the literature. Summerfield et al.<sup>3</sup> relate a case of a worker sustaining an oblique distal radius fracture with 15 degrees of volar angulation as well as multiple fractures of the metacarpals and phalanges. Upon exposure of the distal radius, the PQ was noted to be tense and firm to palpation. With a compartment pressure of 35–40 mmHg observed, using a Stryker manometer, a fascial release was performed. In this particular instance, the authors feel that the PQ syndrome would not have been preoperatively diagnosed due to the underlying fracture and the associated pain.

This is a case that the author has documented about a PQ myofascial pain syndrome of insidious onset and alleviated with trigger point therapy.

---

\* Research Associate, Canadian Memorial Chiropractic College, 1900 Bayview Avenue, Toronto, Ontario, Canada M4G 3E6. 416-482-2340.  
Request for reprints: Robert S Annis, 80 Normandy Court, Sudbury, Ontario P3A 2E8.  
© JCCA 2003.



**Figure 1 Anatomical Variations of pronator quadratus**

\* PQs – pronator quadratus superficial division; PQd – pronator quadratus deep division

\* Reprinted with permission of the WB Saunders Co., copyright; JHS Vol 21(6) 714–22 1996 (Figure 5)

### Case report

A 15-year-old right-handed healthy male student presented to a multi disciplinary clinic for an assessment of a painful left wrist of sixteen months duration. The patient described the pain as sharp during wrist movement and dull at other times and centred about the ulnar styloid process. There was radiation to approximately two-thirds proximal to the wrist along the medial left forearm. The patient denied any initial trauma. The pain began mildly and progressively worsened. All movements increased the pain as well as direct pressure on the area. Rest seemed to give some relief.

Treatment had consisted of a wrist splint for one month with negative results. Physiotherapy in the form of stretches, ultrasound, ice, laser, T.E.N.S had been on going for the past eight months. This had not been helpful. Radiological examination as well as an arthrogram and MR imaging of the left wrist were negative.

On examination, range of motion of the wrist was normal and painless except with ulnar deviation. This action caused sharp pain in an area of about ten centimetres proximal to the wrist. Palpation along the length of the flexor carpi ulnaris tendon produced pain. Palpation of the pronator quadratus muscle with added digital pressure reproduced the patient's symptoms with radiation along the ulna. The PQ exhibited hypertonia. Upper limb reflexes were 2+, bilaterally. Finkelstein's, Phalen's, reverse Phalen's, and carpal compression tests were negative. Dynamar (tm) grip strength was 36 right and 30 left. Resisted pronation of the forearm in full flexion produced pain over the PQ with approximately a grade IV strength index.

A preliminary working diagnosis of PQ myofascial pain syndrome was made.

Consent from his legal guardian was obtained and the treatment plan was explained. Treatment consisted of myofascial trigger point therapy<sup>4</sup> (sustained digital pressure on an irritated trigger area) of the PQ muscle belly and IFC (tetanizing/analgesic setting) for 15 minutes on three separate visits for the first week. This procedure was repeated twice each week for the following two weeks and then followed up at a two and a three-week interval. The patient was discharged asymptomatic after the last treatment (nine in total).

### Discussion

This diagnosis was based on the work of Travell and

Simons.<sup>4</sup> Although they do not specifically identify the PQ muscle as having a myofascial pain syndrome (MPS), based on their determination of other such syndromes, the characteristics of this particular presentation mimic others that they have described (Table 1). Finding a site of local tenderness is essential for this diagnosis but is nonspecific. If a local twitch response and pain reproduction with a characteristic referral is found, then this is specific and diagnostic of a myofascial trigger point. The more of the diagnostic criteria present (Table 1), the greater certainty is the diagnosis.<sup>4</sup>

**Table 1**  
**Criteria for diagnosing active myofascial TPs<sup>4</sup>**

- history sudden onset during or shortly following acute overload stress
- gradual onset with chronic overload stress
- specific characteristic pattern of pain referred from myofascial trigger points (TPs)
- weakness and restriction in the stretch range of motion of the effected muscle
- a taut, palpable band in the effected muscle
- exquisite, local tenderness to digital pressure (the TP), in the band of taut muscle fibers
- a local twitch response elicited through snapping palpation or needling of the TP
- reproduction of the patient's complaint by pressure on, or needling of the TP
- elimination of symptoms by therapy directed specifically to the effected muscle

In this case, there was a history of a gradual onset, a pain referral (not characteristic since none had previously been described by Travell and Simons), weakness in the muscle, a taut palpable band in the affected muscle, the location of the trigger point and, reproduction of the patient's pain complaint by digital pressure on the trigger point. More importantly, the symptoms were eliminated by therapy directed at the specific muscle.

Without a specific classic model to compare to, this diagnosis was not apparent. Upper extremity compression syndromes such as anterior interosseous nerve (AIN) entrapment syndrome, carpal tunnel and pronator teres syndrome must be ruled out. These three will be briefly discussed to aid in the differential diagnosis.

The pain of AIN may also occur spontaneously and cause an aching pain along the medial border of the forearm from the elbow and cross over to the anterior surface of the thumb. Paralysis usually follows shortly after the pain subsides.<sup>5,6</sup> In this case, the patient exhibited no signs of a nerve entrapment in the carpal tunnel (CTS). There was no indication of thenar muscle wasting, sensory loss of the lateral three digits and lateral part of the ring finger, and characteristic nocturnal awakening as seen in CTS.<sup>7</sup> The clinical presentation of pronator teres syndrome has, as its most frequent symptom, an aching pain along the volar forearm, aggravated by repetitive use. The pronator teres (PT) muscle may exhibit tenderness and have a positive Tinel's sign over it. There may also be paresthesia along the distribution of the median nerve when the forearm is pronated forcibly against resistance.<sup>8</sup>

The ulnar nerve may also be compressed at the elbow (cubital tunnel syndrome) and at the wrist (tunnel of Guyon).<sup>9</sup> The presenting complaint for cubital tunnel syndrome is medial forearm pain and paresthesia into the ring and little finger. This may be caused by a stretch on the nerve at the elbow or compression from the two heads of the flexor carpi ulnaris or cubital tunnel osteophytes. The symptoms are produced by passive or resisted elbow flexion with the elbow in a maximally flexed position.<sup>9</sup>

A complaint of numbness/tingling or pain in the fourth and fifth digits is the classic presentation of compression at the tunnel of Guyon.<sup>9</sup> Usually the ulnar nerve is compressed in the tunnel of Guyon. This compression may be caused by constant compression on handle bars (e.g., bicycles). Tests include Tinel's at the tunnel or pressure at the pisiform hamate area. With Froment's sign, weakness of the adductor pollicis may be evident. Wartenberg's sign (unable to fully adduct fingers) is positive.

Compression pathologies of the radial nerve may occur at the radial tunnel (radial tunnel syndrome) or at the superficial branch of the radial nerve as it passes between the tendons of the extensor carpi radialis longus and the brachioradialis (Wartenberg's syndrome).

The presenting complaint with the radial tunnel syndrome is a dull aching pain over the lateral forearm.<sup>9</sup> The radial nerve may be compressed at several locations, involving the radial head, medial edge of the extensor carpi radialis brevis, the arcade of Frohse (thickened edge of the superficial head of the supinator), and the two heads of the

supinator muscle. There is tenderness distal to the lateral epicondyle.

Wartenberg's syndrome usually presents as a complaint of numbness or tingling over the dorsolateral aspect of the wrist and hand.<sup>9</sup> A positive Tinel's sign is elicited at the dorsolateral wrist. Passive ulnar deviation and flexion of the wrist may cause pain.

### Conclusion

Careful questioning of the patient and consideration of the signs and presenting symptoms is necessary with patients presenting with forearm and wrist pain. The ability to differentiate between the various compression syndromes and myofascial TPs is critical if the correct treatment protocol is to be implemented expeditiously and effectively. As is evident in this case, not all conditions fall neatly into a prescribed format. Practitioners must always be alert for new causes of pain and for new ways to treat it.

Although this may be a unique case presentation, it is worth investigating whether or not the PQ has an irritable TP in any wrist/forearm pain presentation. It may save a person with this condition considerable aggravation.

### References

- 1 Stuart PR. Pronator quadratus revisited. *J Hand Surg [Br]* 1996 Dec; 21(6):714-722.
- 2 Basmajian JV, DeLuca CJ. *Muscles alive: their functions revealed by electromyography*, 5th edn. Baltimore, Williams and Wilkins, 1985.
- 3 Summerfeild SL, Folberg CR, Weiss AP. Compartment syndrome of the pronator quadratus: a case report. *J Hand Surg [Am]* 1997 Mar; 22(2):266-268.
- 4 Travell JG, Simons DG. *Myofascial pain and dysfunction: the trigger point manual*. Baltimore, Williams and Wilkins, 1984.
- 5 Crawford JP, Noble WMJ. Anterior interosseous nerve paralysis: cubital tunnel (Kiloh-Nevin) syndrome. *J Manipulative Physiol Ther* 1988; 11(3):218-220.
- 6 Spinner M. *Injuries to the major branches of the peripheral nerves of the forearm*. 2nd ed. Philadelphia, WB Saunders Co. 1978.
- 7 Ross MA, Kimura J. AAEM case report No. 2: the carpal tunnel syndrome. *Muscle and Nerve* 1995; 18(6):567-573.
- 8 Stewart JD. *Focal peripheral neuropathies*. New York, Elsevier, 1987.
- 9 Sousa TA. *Differential diagnosis for the chiropractor*. Maryland Aspen Publishers Inc., chapter 9, 1998.