

# Virchow's Triad and spinal manipulative therapy of the cervical spine

Bruce P Symons, MSc DC\*†

Michael Westaway, BSc, PT, FCAMT\*\*

*The objective of this review paper is to borrow Virchow's Triad as a conceptual framework to examine the state of the art in research on thrombosis, specifically in the vertebrobasilar system as a consequence of high velocity, low amplitude spinal manipulation of the cervical spine. A revised Virchow's Triad is presented which emphasizes the interactions between various risk factors, as a tool for clinicians and researchers to use in their analyses of vertebrobasilar stroke. Endothelial injury, abnormal blood flow and hypercoagulability are discussed.*

(JCCA 2001; 45(4):225-231)

KEY WORDS: Virchow, thrombosis, manipulation

*L'objectif de cet article de synthèse est d'avoir recours à la triade de Virchow à titre de cadre conceptuel afin d'examiner le nec plus ultra en matière de recherche sur la thrombose, notamment sur le système vertébro-basilaire, pour ce qui est de l'effet de la manipulation vertébrale à grande vitesse et à faible amplitude de la colonne cervicale. Une triade de Virchow revue et soulignant les interactions entre différents facteurs de risque est présentée à titre d'outil destiné aux cliniciens et aux chercheurs qui l'utiliseront dans leurs analyses des accidents vertébro-basilaires. Les lésions endothéliales, les anomalies de débit sanguin et l'hypercoagulabilité sont discutées.*

(JACC 2001; 45(4):225-231)

MOTS CLÉS : triade de Virchow, thrombose, manipulation.

## Introduction

Rudolf Virchow was a genuine eighteenth century Renaissance man. Born in 1821 to a family of Pomeranian butchers, he obtained his medical degree in 1843 and began studies on a number of scientific disciplines, but focusing on pathology and anthropology; he published significant works on typhus, leprosy and cretinism. A staunch proponent of a democratic Germany, he was elected to the Prussian parliament in 1862, where he remained until his death in 1902. As leader of the opposition against Bismarck's

road of "blood and iron" to unite Germany, Virchow so infuriated Bismarck that he once challenged the good doctor to a duel.<sup>1</sup> Virchow's insights into human anatomy and physiology enabled him to coin the term "ischemia", and in 1862 he proposed three causes of thrombosis. These three factors were subsequently termed "Virchow's Triad" (see Figure 1). Although the details have evolved over the past 140 years, the conceptual principles underlying Virchow's Triad have remained sound and defensible.

The use of spinal manipulative therapy (SMT) in the

\* Human Performance Laboratory, Faculty of Kinesiology, University of Calgary.

† Division of Postgraduate Research, Canadian Memorial Chiropractic College.

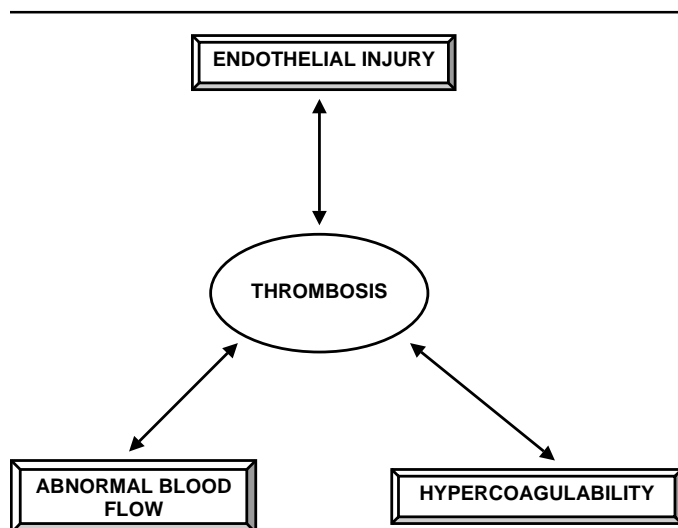
\*\* Sports Medicine Center, Faculty of Kinesiology, University of Calgary.

Address correspondence and reprint request to: Bruce Symons, DC, Faculty of Kinesiology, University of Calgary, 2500 University Drive N.W., Calgary, Alberta, Canada T2N 14N.

Tel: 403-220-4736. Fax: 403-284-3553. E-mail: bruce@kin.ucalgary.ca

© JCCA 2001.

**Figure 1**  
**Virchow's Triad.**



chiropractic, medical and paramedical community is common. The vertebrobasilar system has been inculcated with respect to insults leading to dissection and potential emboli or thrombosis following cervical SMT.<sup>2</sup> The region of the cervical spine predominately involved with vertebral artery (VA) compromise is the atlantoaxial segment,<sup>3</sup> specifically where the VA exits the foramen transversarium of C1 and loops posteriorly to ascend into the foramen magnum. This is due largely to the unique anatomy and kinematics of the atlantoaxial segment, whose function is to ensure adequate rotation of the head while preserving the patency of the vertebral arteries.

The objective of this review is to borrow Virchow's Triad as a conceptual framework to examine the state of the art in research on thrombosis, specifically in the vertebrobasilar system, as a consequence of high-velocity, low-amplitude spinal manipulation of the cervical spine. An exhaustive review of the literature in this area, especially with respect to the hemodynamic changes in the VA during SMT, is beyond the scope of this manuscript. Instead, the interested reader is directed to the recent book by Terrett,<sup>4</sup> which reviews the literature very comprehensively.

We will also present a "revised" Virchow's Triad, which emphasizes the interactions between various risk factors, as a tool for clinicians and researchers to use in their analyses of vertebrobasilar stroke.

### Virchow's Triad

As seen in Figure 1, the three branches of Virchow's Triad are endothelial injury, abnormal blood flow and hypercoagulability.<sup>5</sup> Virchow proposed that each of these three factors could predilect or lead directly to thrombosis, and thus by our extrapolation, to a vertebrobasilar stroke. These factors will be discussed separately below, but with a clinical rather than purely academic emphasis. It is also important to note that these three "legs" of the triad do not stand alone; there is significant cross-talk between them. For example, blood coagulability affects blood flow, and abnormal blood flow can initiate endothelial injury. Endothelial injury in turn affects coagulability and blood flow, and so forth. Thus, Virchow's Triad describes a set of dynamic processes rather than a static cause-and-effect model.

### Endothelial injury

Under normal circumstances, the vascular endothelium maintains equilibrium between prothrombotic versus anti-thrombotic factors, such as the release of procoagulants versus anticoagulants, cell-to-cell adhesion molecules, vasoconstriction versus vasodilation, and long-term effects such as gene expression and apoptosis. An exhaustive list of these factors is stupefying in magnitude, and once again the interested reader is directed to two excellent reviews on this subject.<sup>6,7</sup> However, physical or biochemical injury to the vascular endothelium can activate both Extrinsic and Intrinsic coagulation cascades, resulting in the formation of a thrombus.

The most common causes of endothelial injury are atherosclerosis, hypertension,<sup>8</sup> and toxic substances such as homocysteine.<sup>9</sup> However, direct physical damage is certainly another distinct possibility. With respect to manipulation of the cervical spine, the pertinent question is: can SMT damage the vascular structures, specifically the VA?

Cervical SMT (cSMT) is a mechanically-controlled, but fast and furious event; approximately 100-150N of force are delivered to the neck in under 200ms<sup>10-12</sup> (for a biomechanical review of these events, see Herzog<sup>13</sup>). Given these characteristics of cSMT, it might be hypothesized that there is considerable force delivered to the internal structures of the neck. From basic mechanics, we know that an external force delivered to the neck during cSMT must be somehow transferred to the internal

anatomic structures of the cervical spine. However, to our knowledge, there has been no research into how this force might be transmitted into the cervical spine, which structures absorb the majority of the force, and if any of the force generated actually affects the VA.

Symons et al.<sup>14</sup> investigated the strains sustained by the VA during cSMT in fresh cadaveric specimens using sonomicrometry. They reported an average strain of 6.1% in the superior, distal loop of the VA as it exits the foramen transversarium of C1 and enters the foramen magnum during a combined lateral break/rotatory cSMT maneuver. In other words, this distal loop of the VA stretched by approximately 6% of its resting length during cSMT. This strain value was well within the range of strains (1–12%) produced during the passive motion of the neck through its physiologic range. Furthermore, mechanical testing demonstrated the first signs of failure of the distal VA loop at 53% strain. A similar value (59%) for the longitudinal failure strain of the VA has been reported in the forensic literature.<sup>15</sup> Thus, there is an intrinsic 9-fold safety margin for VA damage during cSMT. The authors concluded that a single, high-velocity, low-amplitude cSMT thrust is very unlikely to mechanically disrupt the VA. However, the above conclusion does not preclude the possibility that repeated cSMT thrusts at 6% strain may have a cumulative effect, and may damage the VA over a longer period of time. Furthermore, the authors only investigated the effects of longitudinal strain; it is well known that at the C1/C2 level, the VA undergoes radial, shear, torsional and compressive strains in addition to simple longitudinal strain. Nevertheless, a corollary of this conclusion is that if the VA were damaged by a single, one-time cervical manipulation, then the same damage would have almost certainly occurred during the normal, physiologic motions of the neck.

### Abnormal blood flow

When Virchow proposed abnormal blood flow as a thrombogenic factor in 1862, he was already aware of the fact that turbulent blood flow can lead to activation of the clotting process. The question we must answer is: can cSMT disrupt VA blood flow, either by a mechanical occlusion of the vessel or by inducing turbulent blood flow, and thus lead to vertebrobasilar ischemia (VBI)?

Vertebral artery blood flow velocity studies originated historically on the premise that cervical spine rotation had

a direct mechanical occlusive effect on the VA, and therefore vertebrobasilar symptomatology was due to a “pinching” of the artery. Based on anatomic and cadaveric studies,<sup>16,17</sup> early researchers postulated that instantaneous blood flow compromise in the VA, via extension/rotation of the cervical spine, could elicit vertebrobasilar symptoms. Tatlow and Bammer, in their postmortem angiographic study at the atlantoaxial joint, noted that the VA could be occluded upon rotation. Toole and Tucker<sup>18</sup> concurred with this single premise of contralateral VA occlusion, as did Brown<sup>16</sup> in his classic cadaveric study. In their *in vivo* investigation of functional hemodynamic impairment associated with neck motion, Weintraub and Koury<sup>19</sup> utilized dynamic magnetic resonance angiography. They demonstrated that head rotation consistently produced compression and occlusion of the contralateral VA at the atlantoaxial segment. They concluded that such compression and inherent occlusion was a cause of arterial damage, and that the majority of VA impingement was caused by a downward shift of the contralateral atlas while the vertebral artery segment was fixed. In a study using MRI, Dumas<sup>3</sup> also agreed with this anatomic premise of a stretching effect on the artery. However, the important question is whether this stretching and kinking of the VA is sufficient to provoke an ischemic effect?

Blood flow is normally laminar, with the blood components stratified so that the plasma is adjacent to the smooth and slippery endothelium, while the erythrocytes and platelets travel through the central axis of the bloodstream. Overall, this arrangement minimizes friction. However, under certain conditions, the blood flow can become turbulent; this can be defined as blood which moves obliquely as well as lengthwise through the blood vessel in a manner similar to eddy currents. Turbulent flow in turn triggers intravascular biochemical responses that lead to plaque formation, thrombogenesis, and so forth. Besides simple mechanical occlusion that causes an instantaneous shut-off of VA blood flow and hence a stroke, there is the possibility that cSMT causes a stretch-induced vasospasm<sup>20</sup> of the VA in its atlantoaxial course, and/or the possibility that cSMT may induce turbulent blood flow. This can also be classified under the previous heading of “Endothelial Injury” in Virchow’s Triad – can repeated cSMT create microtears in the blood vessel and/or turbulence, which then lead to activation of the clotting sequelae, thrombogenesis or physical dissection, and a

consequent embolic stroke if the clot is dislodged? This question is currently under investigation in our laboratory using a pig vertebral artery model.

Due to its unusual development, the VA is prone to many congenital malformations. Unlike most blood vessels, the left and right VAs arise from six small segmental artery pairs located within the foramina transversarii embryologically, which then anastomose to form a continuous blood vessel prior to birth.<sup>21</sup> Although a congenitally incomplete Circle of Willis is not uncommon, especially where the normal anastomoses exist, obstruction of any one of the four major arteries supplying the brain should not cause VBI. Cervical spine rotation has been reported to provoke transient VBI symptoms in patients with hypoplasia of a VA. Rivett et al.<sup>22</sup> noted in his case study that a patient identified with frank unilateral VA hypoplasia did not manifest any vertebrobasilar symptomology on cervical rotation/extension testing. Frisoni<sup>20</sup> stated that such conditions are not relevant in ischemia after neck rotation, and that a transient rotational obstruction of normal VAs cannot possibly cause ischemic symptomology.

Licht<sup>23,24</sup> postulated that the change in blood flow velocity during neck rotation was due to a positional change in arterial diameter. This *in vivo* investigation found no significant change in the volume blood flow in the VA before or after cSMT. Along these lines, but using a systemic hemodynamic approach, Knutson<sup>25</sup> concluded that upper cervical SMT decreased the systolic blood pressure as compared to resting pre-impulse controls. He proposed that this effect was due to a cervicosympathetic reflex, and a reduction in the 'pressor reflex' of the arterial smooth muscle. However, it is difficult to test this hypothesis experimentally. Furthermore, these reflex responses tended to be short-lasting and transient, and probably did not persist for long after the cSMT.

Autoregulation alters the diameter of cerebral vessels, and thereby maintains relatively constant blood flow over a wide range of mean arterial pressures.<sup>26</sup> This is probably achieved by a combination of metabolic, myogenic and neurogenic mechanisms.<sup>27</sup> Budgell<sup>26</sup> suggested that autoregulation and compensatory flow through the collateral branches make it unlikely that occlusion of a VA would compromise blood flow to the brain. Ueda et al.,<sup>28</sup> in their investigation of unilateral vertebrobasilar occlusion on the inner ear blood flow in the rat, found no significant blood

flow changes or perfusion patterns in the cochlea. In contrast, from a mechanical standpoint, Matsuyama et al.<sup>2</sup> reported three cases in which VBI was caused by mechanical occlusion or external stenosis of the Zone III VA. They reported that the VA was stretched and completely occluded at the atlantoaxial level with the cervical spine rotated 45° with a concomitant decrease in blood flow.

In summary, the current literature favors the viewpoint that mechanical occlusion of the VA can disrupt local blood flow, but that this disruption will probably not result in any VBI symptomology. However, the possibility still exists that any turbulent blood flow that may be induced by cSMT might result in deleterious sequelae other than simply reducing brain perfusion.

### Hypercoagulability

The final leg of Virchow's Triad is hypercoagulability or, quite simply, the tendency of the patient's blood to clot. Rather than discuss this third aspect of Virchow's Triad in terms of hypercoagulability, we will adopt the more clinical perspective of categorizing all of those factors that predispose a patient towards VBI. This will include pathologic factors unrelated to blood coagulation, such as congenital malformations in the VA. There are two basic reasons for redefining this leg of Virchow's Triad. First, it allows us to comment on those factors that do not easily fit into any of the other categories. Second, it is highly unlikely that SMT or any other mechanical intervention has a direct effect on coagulability. In contrast, the patient will likely have an underlying predilection towards strokes based on their genetics, risk factors, pathology, pharmaceuticals and other phenomena that would increase their overall risk of VBI regardless of the nature of the precipitating event.

Table 1 presents a list of these factors in the form of a checklist. These factors are listed in no particular order, and do not represent a list of absolute contraindications for cSMT. Instead, we suggest that clinicians may use this list as a set of potential red flags during history-taking. If several of the items are positive in a single patient, we would suggest that the clinician exercise caution in manipulating the cervical spine. For example, cardiomyopathy is listed in Table 1, but someone who has experienced a single heart-attack in the past and is otherwise healthy should not be refused cSMT. However, a hypertensive, obese, forty-

**Table 1**  
**Factors leading to an increased risk of hypercoagulability**  
**and/or vertebrobasilar stroke.**

<b>GENETIC/LIFESTYLE</b>	
◆ Female Gender	spine, e.g. Type 1 Neurofibromatosis, Klippel-Feil Syndrome
◆ Advancing age	◆ Cystic Medial Degeneration
◆ Obesity	◆ Vasculitides, e.g. Takayasu, Kawasaki, Wegener
◆ Sedentary lifestyle and/or prolonged bed rest	◆ Migraine headaches
◆ Cigarette Smoking	◆ Any cerebrovascular disease, e.g. Transient Ischemic Attacks, previous stroke
◆ Factor V Leiden Mutation	◆ Atherosclerosis
◆ Protein S mutation	◆ Hypertension
◆ Protein C mutation	◆ any type of cardiomyopathy, including Rheumatic Heart Disease
◆ Antithrombin III mutation	◆ Disseminated Intravascular Coagulation
◆ any mutation in fibrinolysis pathway	◆ Cancer
	◆ Syphilis
<b>PATHOLOGICAL</b>	◆ Any hyperestrogenic state
◆ Diabetes	◆ Any significant tissue trauma, e.g. burns, fractures, surgery
◆ Lupus “anticoagulant” in Lupus Erythromatosus	
◆ Sickle Cell Disease	<b>PHARMACEUTICALS</b>
◆ Antiphospholipid Antibody Syndrome	◆ Oral Contraceptives
◆ Paroxysmal Nocturnal Hemoglobinuria	◆ Type II Heparin-induced Thrombocytopenia
◆ Fibromuscular Hyperplasia	
◆ Marfan’s Syndrome	
◆ Ehlers-Danlos syndrome	
◆ any congenital malformation of the VA and/or	

ish female who is a smoker, is on oral contraceptives and presents with migraine headaches and syncope should be approached with great suspicion.

### Conclusions

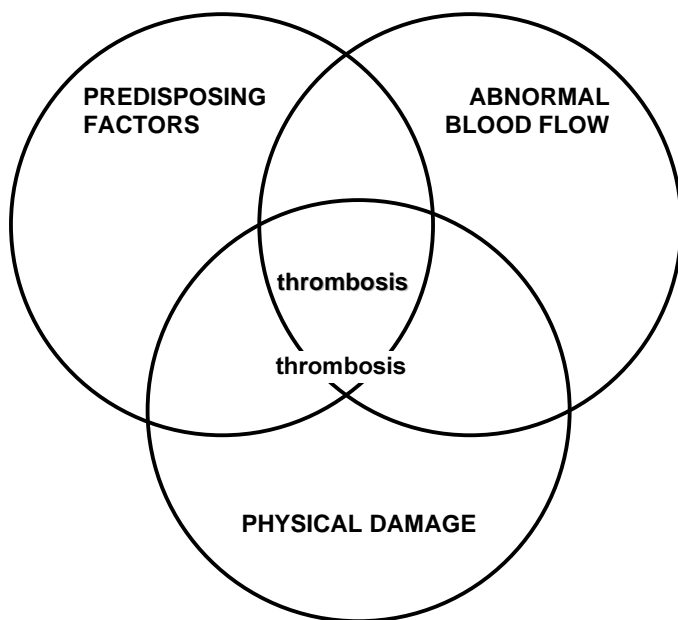
It is now generally accepted that incidents of VBI are caused by thrombosis or physical dissection of the VA. A disruption in VA blood flow caused by cSMT and the consequent decrease in brain perfusion to below the ischemic threshold is not likely because of the following two arguments.

First, in most cases, the Circle of Willis is supplied by four major arteries. Any decrease in brain perfusion will be reflexively compensated for by the remaining collaterals. For example, Refshauge<sup>29</sup> demonstrated that rotation of the cervical spine by as little as 45° caused changes in VA blood flow velocity. She concluded that rotation did diminish blood flow to the brain, but that normally this is not

important or is adequately compensated for by collateral circulation. Furthermore, Rivett et al.<sup>22</sup> reported no appreciable symptoms of VBI even when the VA was fully occluded. Common sense also suggests this to be a valid conclusion – otherwise, simply moving one’s neck during normal daily activities could be fatal. Thus, even 100% occlusion of a given VA should not result in VBI.

Second, as previously noted above, the cSMT thrust takes only about 200 ms. In our experience, most chiropractors deliver their cervical manipulations within 5–10 seconds (Symons and Herzog, unpublished observations), including the premanipulative set-up. Since most transient ischemic attacks (TIAs) last between 2–15 minutes<sup>30</sup> and do not produce any substantial sequelae, it can be argued that the complete occlusion of the VA for even a full minute will not result in any appreciable brain damage. Furthermore, some neurologists have actually reported that brief ischemic periods (< 10 min), such as TIAs, actu-

**Figure 2**  
**The Revised Virchow's Triad.**



ally have a neuroprotective effect – they condition the brain against ischemia when the “big one” hits.<sup>30</sup>

Given the above arguments, it is perhaps more likely that if a cSMT induces VBI, it does so in the presence of other factors, in which case, we would like to propose a revised Virchow's Triad in Figure 2. In this figure, circular zones representing the interactions between the patient's Predisposing Factors, the presence of Abnormal Blood Flow and Physical Damage have replaced the legs of the triad. The Predisposing Factors zone is self-explanatory, and can be derived from Table 1 plus the clinician's own judgement. The Abnormal Blood Flow zone is related to Predisposing Factors such as atherosclerosis, but is kept separate to remind the clinician of the utility of basic diagnostic testing such as checking the blood pressure and auscultating for bruits. The usefulness of VBI testing by extension/rotation of the cervical spine has been a subject of interest in the literature, but it is not the objective of this review to comment on these studies. The Physical Damage zone represents the characteristics of the actual manipulation itself. Since there is more strain experienced by the VA during cervical rotation than lateral bending,<sup>14</sup> we would suggest the clinician manipulate the neck accordingly, using minimum force required to achieve their

therapeutic objective. We would also speculate that a given number of cSMT procedures performed over a short period of time (eg. daily for 2 weeks) probably has a greater potential to cause VA damage than the same number of cSMTs performed over a longer period of time (eg. twice per week for 7 weeks). Furthermore, the overlapping areas serve to arouse heightened clinical suspicion whenever patients present with multiple risk factors for VBI that place them in these areas. It is our hope that this may serve as a visual reminder of the Hippocratic phrase: first of all, do no harm.

### Acknowledgements

The authors wish to thank Profs. Walter Herzog and Murray Maitland for their helpful discussions. This work was supported in part by grants from LifeMARK Health, Canadian Memorial Chiropractic College, Canadian Chiropractic Association and the Canadian Chiropractic Research Foundation.

### References

- 1 Ackernecht EH. Rudolf Virchow: Doctor, Statesman, Anthropologist. Madison: University of Wisconsin Press, 1953.
- 2 Mastsuyama T, Morimoto T, Sakaki T. Bow Hunter's stroke caused by a nondominant vertebral artery occlusion: case report. *Neurosurgery* 1997; 41:1393–1395.
- 3 Dumas J, Salama J, Dreyfuss P, Thoreux P, Goldlust D, Chevrel J-P. Magnetic resonance angiographic analysis of atlanto-axial rotation: anatomic bases of compression of the vertebral arteries. *Surgical Radiological Anatomy* 1996; 18:303–313.
- 4 Terret Allan GJ. Current concepts in vertebrobasilar complications following spinal manipulation. West Des Moines, Iowa: NCMIC Pub., 2001
- 5 Moser K. Pulmonary thromboembolism. In: Fauci A, Braunwald E et al., eds. *Harrison's Principles of Internal Medicine*. New York: McGraw-Hill, 1994.
- 6 Breddin H. Thrombosis and Virchow's Triad: What is established? *Seminars in Thrombosis and Hemostasis* 1989; 15:237–239.
- 7 Gross PL, Aird WC. The endothelium and thrombosis. *Seminars in Thrombosis and Hemostasis* 2000; 26:463–478.
- 8 Lip G, Blann A. Does hypertension confer a prothrombotic state? Virchow's triad revisited. *Circulation* 2000; 101:264–269.
- 9 Al-Obaidi M, Philippou H, Stubbs P, et al. Relationships between homocysteine, factor VIIa, and thrombin generation in acute coronary syndromes. *Circulation* 2000; 101:372–377.

- 10 Kawchuk G, Herzog W, Hasler E. Forces generated during spinal manipulative therapy of the cervical spine: a pilot study. *J Manip Physiol Therapeutics* 1992; 15:275–278.
- 11 Herzog W, Conway P, Kawchuk G, Zhang Y, Hasler E. Forces exerted during spinal manipulative therapy. *Spine* 1993; 18:1206–1212.
- 12 Kawchuk G, Herzog W. Biomechanical characterization (fingerprinting) of five novel methods of cervical manipulation. *J Manip Physiol Therapeutics* 1993; 16.
- 13 Herzog W. Mechanical, physiologic and neuromuscular considerations of chiropractic treatments. *Advances in Chiropractic*. Vol. 3. New York: Mosby-Year Book, 1996:269–285.
- 14 Symons B, Leonard T, Herzog W. Internal forces sustained by the vertebral artery during spinal manipulative therapy. *JMPT* (in press).
- 15 Johnson C, How T, Scraggs M, West C, Burns J. A biomechanical study of the human vertebral artery with implications for fatal arterial injury. *Forensic Science International* 2000; 109:169–182.
- 16 Brown B, Tatlow T. Radiographic studies of the vertebral arteries in cadavers. *Radiology* 1963; 81:80–88.
- 17 Tatlow T, Bammer H. Syndrome of vertebral artery compression. *Neurology* 1957; 7:331–340.
- 18 Toole J, Tucker S. Influence of head position upon cerebral circulation: studies on blood flow in cadavers. *Archives of Neurology* 1960; 2:616–623.
- 19 Weintraub M, Khoury A. Critical Neck position as an independent risk factor for posterior circulation stroke: a magnetic resonance angiographic analysis. *J Neuroimaging* 1995; 5:16–22.
- 20 Frisoni G, Anzola G. Vertebrobasilar ischemia after neck motion. *Stroke* 1991; 22:1452–1460.
- 21 Giuffre R, Sherkat S. The vertebral artery: developmental pathology. *J Neurosurgical Sciences* 1999; 43:175–189.
- 22 Rivett D, Milburn P, Chapple C. Negative pre-manipulative vertebral artery testing despite complete occlusion: a case of false negativity? *J Manip Physiol Therapeutics* 1998; 3:102–107.
- 23 Licht P, Christensen H, Hojgaard P, Hoilund-Carlsen P. Triplex ultrasound of vertebral artery flow during cervical rotation. *J Manip Physiol Therapeutics* 1998; 21:27–31.
- 24 Licht PB, Christensen HW, Hoilund-Carlsen PF. Vertebral artery volume flow in human beings. *J Manipulative and Physiologic Therapeutics* 1999; 22:363–367.
- 25 Knutson G. Significant changes in systolic blood pressure post vectoral upper cervical adjustments vs resting control groups: a possible effect of the cervicosympathetic and/or pressor reflex. *J Manip Physiol Therapeutics* 2001; 24:101–109.
- 26 Budgett B, Sato A. The cervical subluxation and regional blood flow. *J Manipulative and Physiologic Therapeutics* 1997; 20:107–107.
- 27 Haynes M. Doppler studies comparing the effects of cervical rotation and lateral flexion on the vertebral artery blood flow. *J Manip Physiol Therapeutics* 1996; 19:378–384.
- 28 Ueda I, Murai T. Inner ear blood flow in the rat after unilateral arterial occlusion in the vertebrobasilar arterial system. *Acta Otolaryngologica* 1998; 522:36–39.
- 29 Refshauge K. Rotation: a valid premanipulative dizziness test? Does it predict safe manipulation? *J Manip Physiol Therapeutics* 1994; 17:15–19.
- 30 Kimura K, Minematsu K, Yasaka M, Wada K, Yamaguchi T. The duration of symptoms in transient ischemic attack. *Neurology* 1999; 52:976–980.
- 31 Moncayo J, de Freitas G, Bougousslavsky J, Altieri M, van Melle G. Do transient ischemic attacks have a neuroprotective effect? *Neurology* 2000; 54:2089–2094.

### CCA joins The Canadian Cochrane Network and Center (CCN/C)

The Canadian Chiropractic Association was recently invited to become an affiliate organization of the prestigious Canadian Cochrane Network and Center.

The Cochrane Collaboration established in the UK in 1992 is an international organization and now has 14 national centers globally. It's mission is to prepare, maintain and promote the accessibility of systematic reviews of the effects of health care interventions. The Canadian Center is located at McMaster University in Hamilton and Dr. Arne Ohlsson is the Director. There are 16 Cochrane Network sites located in health sciences centers throughout Canada which assist the national office in producing reviews, conducting work-

shops, identifying priority areas and promoting the dissemination of findings.

Completed reviews are placed on the Cochrane Database of Systematic Reviews and are available from the Cochrane Library. There are approximately 1700 reviews completed or in progress and they are regularly amended.

The Cochrane Back Review Group based in Canada, is obviously directly related to the interests of our profession. The CCN/C expressed their eagerness to work collaboratively with the CCA. The CCA will provide advice to the CCN/C on its strategic directions.