0008-3194/2009/334–338/$2.00/©JCCA 2009

Ganglion cyst on the posterior cruciate ligament: a case report

Jaclyn A. Durante, BSc, DC*

Objective: *To present the diagnostic and clinical features of a ganglion cyst located on the posterior cruciate ligament and create awareness amongst clinicians of this uncommon diagnosis.*

Clinical Features: *A 24-year old woman complaining of intermittent left knee pain brought on by an increase in mileage during her training for a half-marathon. A diagnosis of mild chondromalacia patella and a ganglion cyst on the posterior cruciate ligament was made via diagnostic imaging.*

Intervention and outcome: *Patient was followed up with imaging. The patient chose to withdraw a surgical consult due to patient preference. No conservative treatment was provided.*

Conclusion: *Although chondromalacia patella is the more probable, a secondary diagnostic consideration in this patient could be a ganglion cyst. A ganglion cyst on the posterior cruciate ligament is an uncommon diagnosis and the clinical manifestations are variable and non-specific. It is important to be aware of its clinical features and to obtain appropriate methods of imaging to generate the diagnosis promptly.*
(JCCA 2009; 53(4):334–338)

KEY WORDS: intra-articular cysts, knee, ganglia, posterior ganglion cyst

Objectif : *Présenter les caractéristiques cliniques et diagnostiques d'un kyste ganglionnaire situé dans le ligament croisé postérieur et sensibiliser les cliniciens à propos de ce diagnostic rare.*

Caractéristiques cliniques : *Une femme de 24 ans se plaignant de douleur intermittente au genou gauche provoquée par une hausse du kilométrage lors de son entraînement pour un demi-marathon. Un diagnostic de légère chondromalacie de la rotule et un kyste ganglionnaire sur le ligament croisé postérieur a été posé au moyen de l'imagerie diagnostique.*

Intervention et résultats : *On a suivi la patiente avec l'imagerie. La patiente a choisi d'obtenir l'avis d'un chirurgien à la suite d'une orientation. Aucun traitement conservateur n'a été prodigué.*

Conclusion : *Bien que la chondromalacie de la rotule soit la plus probable, un kyste ganglionnaire pourrait être une autre considération de diagnostic avec cette patiente. Un kyste ganglionnaire sur le ligament croisé postérieur constitue un diagnostic rare et les manifestations cliniques sont variables et non spécifiques. Il est important d'en connaître les caractéristiques cliniques et d'avoir les méthodes d'imagerie appropriées pour parvenir rapidement au diagnostic.*
(JACC 2009; 53(4):334–338)

MOTS CLÉS : kystes intraarticulaires, genou, ganglion, kyste ganglionnaire postérieur

* Graduate Student, Sport Sciences, Canadian Memorial Chiropractic College, 6100 Leslie Street, Toronto, Ontario M2H 3J1.
Phone: (416) 482-2340 ext. 242. E-mail: jdurante@cmcc.ca
© JCCA 2009.

Introduction

Intra-articular ganglion cysts of the knee are uncommon. During an autopsy in 1924, Caan first reported a ganglion cyst on the anterior cruciate ligament (ACL).[1] Intra-articular cysts are predominantly incidental findings on MRI and arthroscopy with the reported prevalence of 0.2% to 1.3% and 0.6% respectively.[2,3] Ganglion cysts are found to be more often associated with the ACL rather than the posterior cruciate ligament (PCL). Krudwig et al reported 85 intra-articular ganglions of the knee in 8,000 arthroscopically examined knees over a 15 year period.[4] Of that amount, 49 ganglions were associated with the ACL and 16 associated with the PCL, while the remaining were associated with the menisci, infrapatellar fat pad, and medial plica.[4] In this case report a ganglion cyst on the PCL is presented and its etiology, clinical presentation and means of diagnosis are discussed.

Case

A 24-year-old female training for a half marathon presented with left knee pain. She reported no history of trauma. The pain began as mileage increased in the training program. She reported that she could hardly walk after a 16 km run. Running 5 km and less was well tolerated. Pain lasted for 2–3 days at a time and mainly occurred with running and lunges. She described pinpoint sharp pain with light touch located on the most superomedial aspect of the patella. There was pain with kneeling, and at full extension. She also reported an intra-articular transient clicking sensation while moving the knee from flexion to extension. The patient began pain free activities of swimming and cycling to maintain fitness until competing in the half marathon, which she did not run pain free.

Physical examination did not reveal any swelling or bruising. Upon palpation of the superomedial corner of the patella (which measured a diameter of 1cm by 1 cm) the patient experienced extreme tenderness. Pain occurred during active range of motion from 90 degrees of flexion to full extension. Joint line tenderness, McMurray's, Lachman's, anterior drawer, posterior drawer, slocums, Clarke's test, patellar compression test, and patellar lateral apprehension sign were all found to be negative.

Plain film radiographs of the knee were performed and displayed mild joint effusion with blurring of the posterior border of the Hoffa's fat pad and no bone abnormality or loose body (figure 1 and 2). Diagnostic ultrasound examination was performed on both knees and found to be a normal study. A multisequence MRI examination of the left knee was performed revealing mild chondromalacia patella with early delamination of the medial facet, mild infrapatellar fat pad inflammation, and a very small Baker's cyst with no effusion. Lastly, the MRI revealed a multiloculated ganglion cyst adjacent to the PCL posteriorly; extending medially measuring 2 cm (figure 3). The entire process to determine the diagnosis was 3 months.

Figure 1 *Plain film Radiograph AP left knee shows no abnormalities*

The patient did not have a surgical consult, but rather modified activity as stated above with swimming and cycling prior to the half marathon. The patient preferred to avoid surgery due to potential complications that can arise.

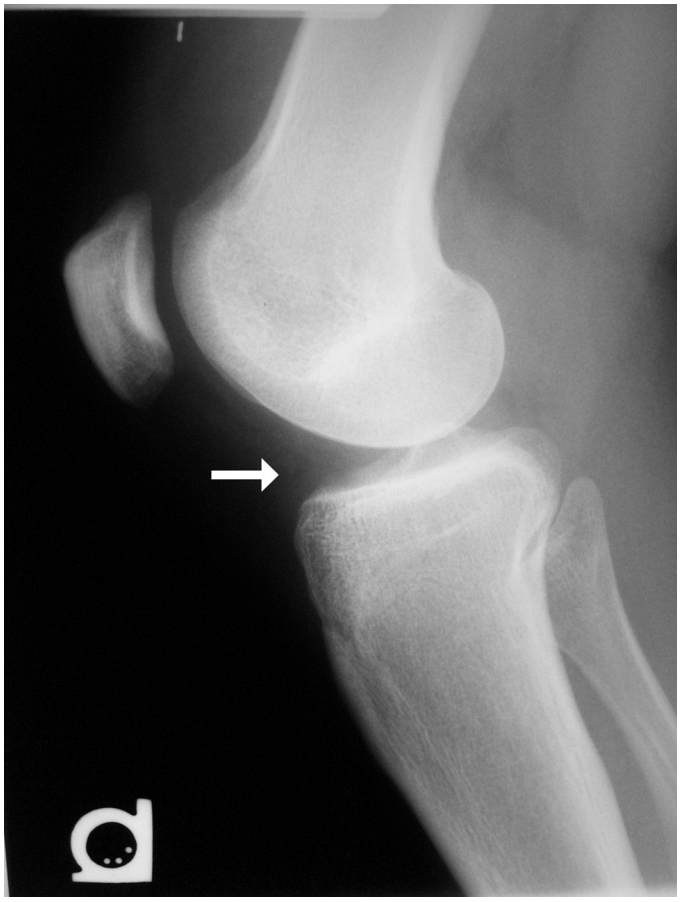

Figure 2 *Plain film Radiograph Lateral left knee shows mild effusion blurring Hoffa's Fat pad*

Figure 3 *MRI Sagittal T2 FES S shows Cystic mass posterior to the PCL*

Discussion

Ganglions can arise as cystic lesions that contain a glassy, clear and jelly-like fluid and can occur within muscle, menisci and tendons.[5,6] Ganglia are usually located in areas under continuous mechanical stress.[7] Peri-articular cysts of the knee occur frequently, with Baker's cyst being the most common followed by antefemoral and synovial cysts.[8] However, intra-articular ganglion cysts of the knee are uncommon and mainly arise from the alar folds of the cruciate ligaments.[9] The reported incidence on MRI is 0.2% to 1.3% and 0.6% in arthroscopic studies.[2,3] Although it can occur at any age, the peak incidence of intra-articular ganglion is approximately 20–40 years of age and occurs most commonly in males.[7,10] PCL ganglia are less common than ganglia associated with the ACL. Clinical presentation of PCL ganglia often mimics internal derangement of the knee.[5] They are difficult to diagnose due to the lack of specific clinical signs and symptoms making diagnosis a slow process.

The aetiology of ganglion cysts is unknown. The most widely held physiological explanation attributes cyst formation to mucoid degeneration of collagen and connective tissues.[3,5] A more recent theory postulates that a cyst is formed due to trauma or tissue irritation.[3,5] Additional theories explaining the possible etiology of ganglion cysts include: herniation of the synovium, displacement of synovial tissue during embryogenesis and proliferating pluripotential mesenchymal cells.[3] The suspected aetiology of ganglion cysts of the PCL may be due to mechanical stress experienced on the posterior aspect of the cruciate ligament during knee motion, however this remains a theory.[11]

Ganglia associated with the PCL are usually well defined lobulated and multiloculated along the surface of the ligament.[11] The ganglion is smooth-walled, translu-

cent and white containing clear, highly viscous mucin that consists of hyaluronic acid, albumin, globulin and glucosamine.[11] The site of origin of the main cystic component is posterior to the PCL in 87.5% of cases and anterior to the PCL in 12.5% of cases.[9]

The clinical manifestations of ganglion cysts associated with the PCL are variable and non-specific.[11] The most consistent symptom is knee pain, which is usually intermittent.[3,10,11] The patient may also experience a sensation of fullness during knee motion, limitation in knee range of motion, and flexion or extension block.[10,11,12] In some rare occasions there may be swelling, effusion, joint line tenderness, pain with McMurray's, and a clicking sensation.[11] Orthopaedic examination of the knee will reveal a stable knee.[6] Functional activities, such as running, stair climbing or squatting may exacerbate the symptoms, which were the main findings reported by the patient in this case.[11] Chondromalacia patella most commonly affects the lateral facet of the patella,[13] but was shown to affect the medial facet in the case presented. The most common clinical criteria used to diagnose chondromalacia patella are anterior knee pain with crepitus when flexing and extending the knee, buckling, locking, stiffness and pain with prolonged sitting (Movie Sign), swelling and tenderness.[14] The following orthopaedic tests are found to be the most consistently positive in eliciting the symptoms of chondromalacia patella, patellofemoral compression test and Clarke's test.[14,15] Often times there is aberrant biomechanics of the patellofemoral joint noted as a predisposing factor to developing chondromalacia patella.[13] Symptomatic features of chondromalacia patella and ganglion cysts are somewhat similar leading to a delayed or missed diagnosis. The MRI findings in this case revealed mild chondromalacia patella, and is the most probable explanation of the patient's pain. However, a ganglion cyst should also be considered as a source of pain in this case along with chondromalacia patella. It is suggested that symptoms arising from a ganglion cyst may be associated with the location, size and dimension of the ganglion, which may change over time.[5] The clinical features of a ganglion cyst on the PCL may mimic internal derangement of the knee and should be differentiated from meniscal tears, meniscal cyst, synovial proliferation disorders, synovial chondromatosis, synovial hemangioma and synovial sarcoma.[12]

PCL ganglion cysts are typically diagnosed incidentally while ruling out serious pathology with diagnostic ultrasound and MRI. Plain film radiography is used to rule out intra-articular loose bodies.[6] If this is negative an MRI evaluation should take place to determine if pathology exists.[6] MRI is the modality of choice as it is the most sensitive, specific, accurate and non-invasive method for depicting cystic masses including size and location.[4] MRI evaluation is also used to exclude neoplastic lesions and to detect additional intra-articular pathologies.[4] MRI is a superior tool used to identify anatomic and morphologic relationships of synovial tissue to surrounding structures, such as bone, vessels, and other soft tissues.[6] Ganglia demonstrate fluid characteristic with intermediate signal intensity on T1 and increased signal intensity on T2 spin-echo or gradient-recalled-echo.[16] Signal from a cyst is usually homogenous but also may be inhomogeneous reflecting a degree of fibrous/myxoid change.[16] CT scan and diagnostic ultrasound may also be used to evaluate the knee. Intra-articular cysts appear as well-defined lesion of water density on CT evaluation and as hypoechoic cystic focus on diagnostic ultrasound.[12,16] Special imaging is very useful to determine the diagnosis of a ganglion cyst associated with the PCL promptly.

The main approaches for treatment of PCL ganglion cysts are surgical procedures. The most common and preferred approach to treatment is arthroscopic resection.[1,2,4,7,9] This is due to the fact that it allows a search for associated injuries, enables complete excision, has a decreased recurrence rate and usually results in rapid recovery.[3,4,9] However, arthroscopic resection is expensive, requires hospitalization, and can lead to potential complications, such as ligamentous and popliteal artery injury and infection.[9] CT and ultrasound-guided needle aspiration have also been utilized to treat cystic lesions.[3,7] Ultrasound guided aspiration is quick, readily available, cost effective, and does not emit radiation as compared to CT guided aspiration.[7] However, there are instances in which recurrence of cysts is possible using CT or ultrasound guided aspiration techniques.[4]

Conclusion

Ganglion cysts associated with the PCL are uncommon but can lead to considerable pain. Patients may experience a sensation of fullness during knee motion, limitation in knee range of motion, and occasional swelling, effusion and joint line tenderness. Although orthopaedic

evaluation of the knee will reveal a stable knee, functional activities, such as running, stair climbing or squatting may exacerbate the symptoms. Cystic lesions are mainly diagnosed incidentally using diagnostic ultrasound or MRI. However, MRI is the modality of choice. Painful PCL ganglion cysts can be treated using CT or ultrasound-guided needle aspiration. However, arthroscopic resection is the preferred technique due to better outcomes achieved. It is important to be aware of the clinical manifestations of PCL ganglia to help obtain appropriate methods of imaging, which will generate the diagnosis promptly and guide practitioners in educating their patients regarding treatment options.

References

1 Noda M, Kurosaka M, Maeno K et al. Ganglion cysts of the bilateral cruciate ligament. Arthroscopy. 1999; 15(8):867–870.
2 Kim MG, Kim BH, Choi J et al. Intra-articular ganglion cysts of the knee: clinical and MRI features. Euro Radio. 2001; 11:834–840.
3 Kim R, Kim K, Lee J et al. Ganglion cysts of the posterior cruciate ligament. Arthroscopy. 2003; 19 (6):e41–e45.
4 Krudwig WK, Schulte KK, Heinemann C. Intra-articular ganglion cysts of the knee joint: a report of 85 cases and review of the literature. Knee Surg Sports Traumatol Arthrosc. 2004; 12:123–129.
5 Zantop T, Rusch A, Hassenflug et al. Intra-articular ganglion cysts of the cruciate ligaments: case report and review of the literature. Arch Orthop Trauma Surg. 2003; 123:195–198.
6 Deutsch A et al. Symptomatic intra-articular ganglion cysts of the cruciate ligaments. Arthroscopy. 1994; 10(1):110–112.
7 Garcia-Alvarez F, Garcia-Pequerul JM, Avil JL et al. Ganglion cysts associated with the cruciate ligaments of the knee: a possible cause of recurrent knee pain. Acta Orthopaedica Belgica. 2000; 66(5):490–494.
8 Garcia A, Hodler J, Vaughn L et al. Case report 677. Skeletal Radiology. 1991; 20:373–375.
9 DeFriend DE, Schranz PJ, Silver DT. Ultrasound guided aspiration of the posterior cruciate ligament ganglion cysts. Skeletal radiology. 2001; 30:411–414.
10 Shetty GM, Nha KW, Patil SP et al. Ganglion cysts of the posterior cruciate ligament. The Knee. 2008; 43:419–424.
11 Seki K, Mine T, Tanaka H et al. Locked knee caused by intra-articular ganglion. Knee Surg Sports Traumatol Arthrosc. 2006; 12:859–861.
12 Tyrrell PM, Pullicino VN, McCall IW. Intra-articular ganglion cysts of the cruciate ligament. Euro Radio. 2000; 10:1233–1238.
13 Zachazewski JE, Magee DJ, Quillen WS. Athletic injuries and rehabilitation. Philadelphia: W.B Saunders Company; 1996.
14 Yochum TR & Rowe LJ. Essentials of skeletal radiology. 3rd ed. New York: Lippincott Williams and Wilkins; 2005.
15 Souza TA. Differential diagnosis and management for the chiropractor. 3rd ed. Toronto: Jones and Bartlett Publishers; 2005.
16 Friedman L, Finlay K, Jurriaans E. Ultrasound of the knee. Skeletal Radiology. 2001; 30:361–377.