

# Nutrient canals of the ilium: a case report

John R Pikula, BSc, DC, DACBR, FCCR(C), MSc\*

*The nutrient canals of bone are a frequent finding on skeletal radiographs. These canals may be misinterpreted as fracture lines especially in patients who present to a chiropractic office with a history of trauma. The case of a 22-year-old female with a nutrient canal in the ilium is briefly reviewed.*

(JCCA 1996; 40(2):79-81)

**KEY WORDS:** nutrient canal, ilium; plain film radiography; normal variant, chiropractic, manipulation.

## Introduction

Patients who experience an injury will present themselves to a health care professional for assessment and management when concern arises. Chiropractors are being called upon more so today to attend to these patient's needs. Occasionally the injury could be to the pelvis from a direct blow or a fall. It is presumed that an adequate case history and examination is completed. Radiographs are commonly utilized to assess for fractures, dislocations, and avulsion injuries. On occasion, a common finding such as a nutrient canal, when prominent, may simulate a fracture line.<sup>1,2</sup>

The purpose of this case is to illustrate a nutrient canal of the ilium, which is a normal variant, and how it can simulate a fracture line on plain film radiography.

## Case report

A 22-year-old female presented to a chiropractic office with an approximate one year history of lower back pain. The pain began when a heavy steel door struck her from

*On observe fréquemment les canaux nourriciers de l'os lors d'une radiographie osseuse. Ces canaux peuvent être confondus avec des traits de fracture, particulièrement chez les patients qui se présentent au cabinet d'un chiropraticien avec un antécédent de traumatisme. Cet article relate le cas d'une femme de 22 ans présentant un canal nourricier dans l'os iliaque.*

(JCCA 1996; 40(2):79-81)

**MOTS CLÉS :** canal nourricier, os iliaque, radiographie simple, variante normale, chiropractie, manipulation.

behind on the right buttock and since that time the pain has become progressively worse. The patient described the pain as "achy" in nature with referral into the right posterior thigh. She reported to be otherwise in good health.

Examination revealed a painful and restricted range of motion of the lumbar spine. Kemp's test produced pain bilaterally. Neurological examination of the lower extremities was normal. No other positive orthopedic tests were found. Lumbo-pelvic radiographs revealed an oblique linear lucency with thin sclerotic borders extending caudally from approximately the lower 1/3 of the right sacroiliac joint angled laterally to within 3 cm of the acetabulum (Figure 1). The width of this lucency measured approximately 3 mm. The remaining skeletal structures and soft tissues were otherwise unremarkable.

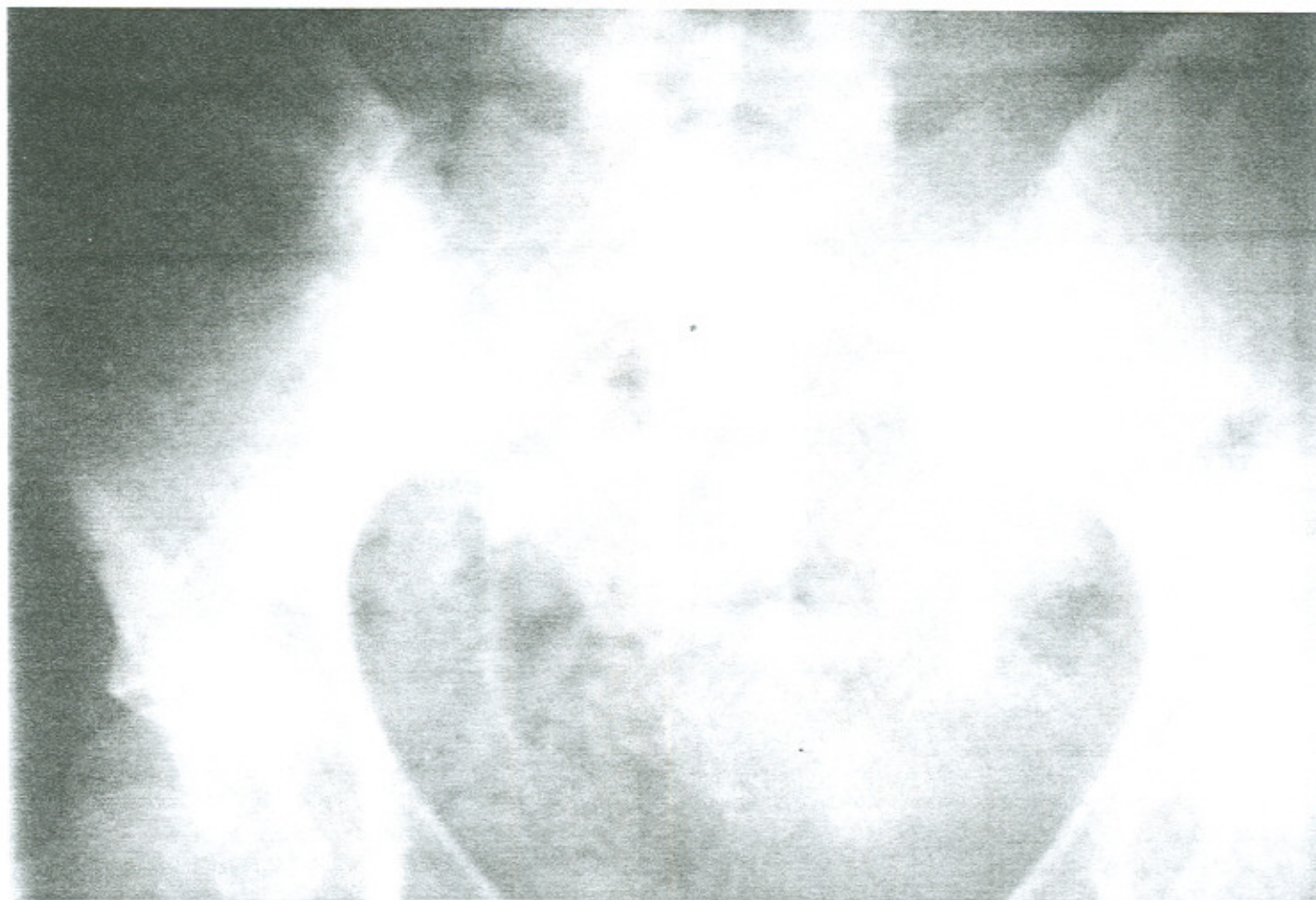The clinical impression was that this patient suffered from a chronic lumbosacral facet syndrome. The radiographic impression was a nutrient canal of the ilium.

## Discussion

The vascular system of a bone consists of the nutrient vessels, periosteal vessels, metaphyseal vessels and epiphyseal vessels. The nutrient vessels enter through the nutrient canal branching both upward and downward sup-

\* Private practice, 189 Brant Avenue, Brantford, Ontario N3T 3J1.  
In partial fulfillment for requirements for the College of  
Chiropractic Sciences Field-practitioner program.  
© JCCA 1996.





**Figure 1** (a) Radiograph of pelvis demonstrating large nutrient foramen in right ilium.

plying the medullary cavity. They then divide into radial branches that enter the cortex and anastomose with branches from the periosteal plexus in the haversian canals. This demonstrates the double blood supply to the cortex.<sup>3</sup>

Nutrient canals of bone appear as oblique grooves with sclerotic margins in the cortex. In the iliac bone they can create linear or branching radiolucent areas on radiography giving the shape of "Y", a "V", or an "X".<sup>4</sup> They are normal anatomic structures and are present in most patients. They are obscured in most patients due to overlying bowel gas.

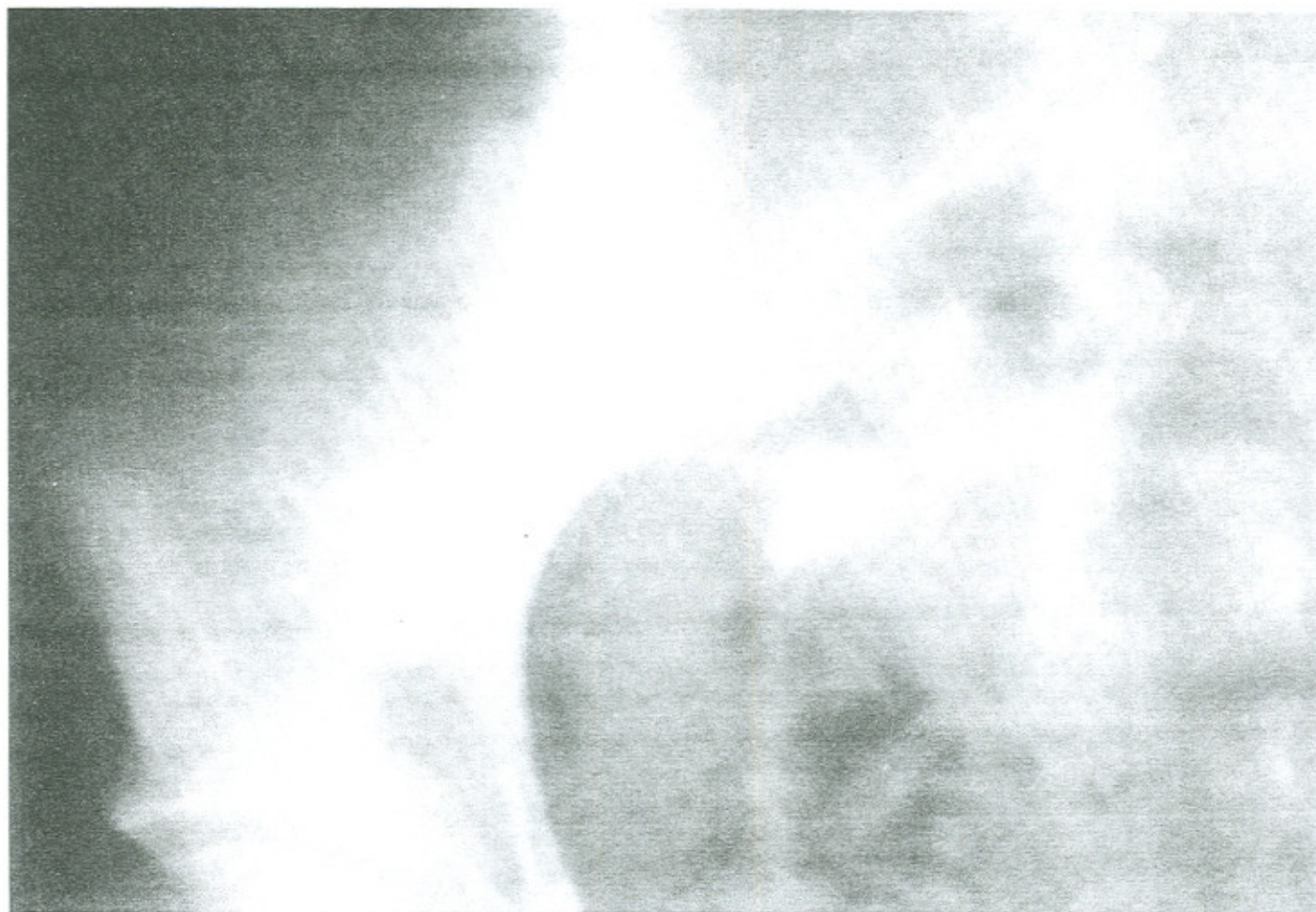
Sirang found that these linear lucencies with sharp sclerotic margins measured in width from 1 to 5 mm. He found no difference in incidence between the sexes and found a slight right:left-sided predominance (4:3) in males only. The canals always contained a vein, and approximately 43% also contained an artery. These vessels anastomosed

predominantly with the superior gluteal vessels and deep circumflex-iliac systems. Little clinical significance is attached to the nutrient vessels and are ignored by orthopedic surgeons when they harvest bone graft material from the iliac wings.<sup>5</sup>

Not all lucencies in the pelvis are nutrient canals. There are many other causes including innocuous ones such as intraosseous ganglia<sup>6</sup> or pneumatocysts.<sup>7</sup> Some may be interpreted as metastatic lesions. The linearity of these canals, their location and the occasional presence of a similar area on the contralateral side should allow the correct diagnostic impression to be made.

### Summary

Nutrient canals of bone are occasionally seen on plain radiography of the skeleton. This case illustrated a nutrient



(b) Close-up view.

canal of the ilium which may have been misinterpreted as a fracture line or a metastatic lesion. The linear pattern of these canals, the sclerotic border, and their location allow the correct impression.

#### Acknowledgments

I would like to thank Dr. Darrell Dailey, D.C. of Brantford, Ontario for providing me this case as shown above.

#### References

- 1 Keats TE. An atlas of normal roentgen variants that may simulate disease. Chicago: Year Book Medical Publishers, 1984:265.
- 2 Zimmer EA. Borderlands of the normal and early pathologic in skeletal radiology. New York: Grune and Stratton, 1956:446.
- 3 Greenfield GB. Radiology of Bone Diseases. 2nd ed. Philadelphia: J.B. Lippincott Company, 1975:3.
- 4 Richardson ML, Montana MA. Nutrient canals of the ilium. Skeletal Radiology 1985; 14:117-120.
- 5 Sirang H. Ein Canalis alae ossis ilii and seine Bedeutung. Anat Anz 1973; 133:225.
- 6 Weinberg S, Schneider H. Case Report 211. Skeletal Radiology 1982; 9:61.
- 7 Ramierz H, Blatt ES, Cable HF, McComb BL, Xornoza J, Hibri NS. Intraosseous pneumatocysts of the ilium. Findings on radiographs and CT scans. Radiology 1984; 150:503.