Back pain and spinal metastases: a case study

LJ LaFrance, DC*
JD Cassidy, DC, MSc (Orth), FCCS**
JW Nykoliation, DC, BSc, FCCS**
DR Mierau, BSPE, DC**

Chiropractors see many cases of acute low back pain in daily practice. Since the majority of these cases are suffering from mechanical back pain, it is easy to overlook more sinister, albeit rare, causes of this problem. One such problem is metastatic disease of the spine. Studies have shown that the spine is the most common site of bony metastasis. This report presents two such cases followed by a discussion of how to avoid costly misdiagnoses.

KEY WORDS: back, metastasis, chiropractic, manipulation.

Les chiropracticiens voient de nombreux cas de douleurs aigues au bas du dos dans leur pratique quotidienne. Puisque la majorité de ces patients souffrent de maux de dos d'origine mécanique, il est facile de négliger des causes plus sinistres, quoique rares, pour ces problèmes. L'un de ces problèmes est la maladie métastatique de la colonne vertébrale. Les études ont démontré que la colonne vertébrale est le site le plus courant de la métastase osseuse. Le présent rapport illustre deux de ces cas, suivis d'une discussion sur la manière d'éviter de coûteuses erreurs de diagnostique.

MOTS CLÉS: douleur dorsale, métastase, chiropractie, manipulation.

Introduction

Tumors of the spine are rare when compared to the many non-neoplastic diseases that produce back pain. But when tumors are the cause of the pain, the spine is the most common site of metastasis. In fact, it is not infrequent to find spinal metastases in adults over fifty years of age.[1] In an autopsy study of 1000 subjects with cancer, 17.6 percent of them had metastases to the spine.[2] For this reason spinal tumors must be included in the diffential diagnosis of back pain.

Metastatic tumors to bone are more common than primary tumors and make up 70 percent of spinal tumors.[2] Metastatic disease of bone will present in either osteoblastic (bone forming) or osteolytic (bone destruction) forms. Osteoblastic metastases account for approximately 20 percent of secondary bone malignancy. Prostatic carcinoma and breast carcinoma (in females) account for most of the osteoblastic disease. Prostatic carcinoma is the third most common cause of cancer death in men over 55 years of age.[3] Most osteolytic disease is caused by lung and breast carcinoma.

However, diagnosis of metastatic disease is difficult and elusive, since the lesions are often silent or produce only vague symptoms. It is the prupose of this paper to review the clinical and radiographic diagnosis of spinal metastasis as demonstrated in the following case studies and discussion.

Case one

Mr. G.W., a pleasant 55-year-old maintenance man, presented to our clinic with a two-month history of low-back pain located over both sacroiliac joints. The pain was aggravated by lifting, and had become quite acute one week earlier after a heavy lift. His pain was sharp with movement and relieved by rest. He had seen his family doctor who had prescribed a course of motrin that partially relieved his pain. He had not been sent for an x-ray examination. There was no past history of back trouble and his general health was quite good with the exception of high blood pressure. Mr. G.W. had no bowel or bladder symptoms and had been off work for one week.

On examination, the patient stood with a very straight lumbar spine. There was no obvious muscle spasm and his lumbar spine range of motion was good except forward flexion which was limited by 50 percent. Straight leg raise was 90 degrees bilaterally, and there was no neurological deficit in the lower extremities. Palpation revealed tenderness over the sacrum and both sacroiliac joints.

Anteroposterior and lateral radiographs of the lumbar spine show a number of well-defined osteoblastic lesions in the right sacrum and on either side of the left sacroiliac joint. There are poorly defined osteoblastic lesions in the bodies of T12 and L2 as well as the right pedicle of L2. These radiographic findings are highly suggestive of osteoblastic metastases from prostatic cancer (Figures 1A and B).

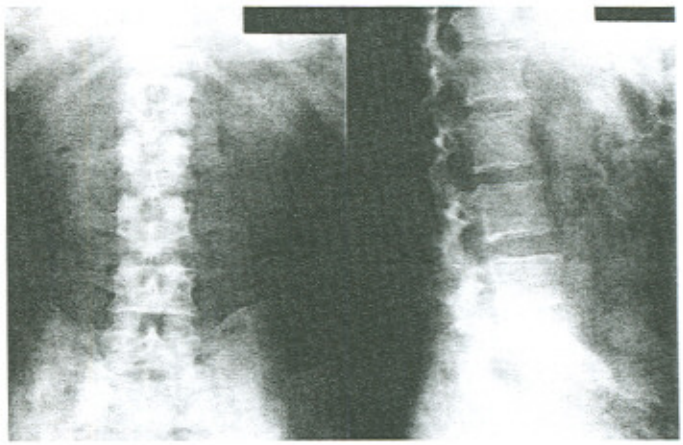

Figure 1 Case 1, note the well-defined osteoblastic lesions in the right sacrum and on either side of the left sacroiliac joint. There is an osteoblastic lesion in the right L2 pedicle.

* Clinical resident IV, CMCC, Toronto
** Fourth Avenue Chiropractic Clinic, Saskatoon
Address reprints to: Dr. JD Cassidy, Fourth Avenue Chiropractic Clinic, 208 – 119 – 4th Avenue South, Saskatoon, Saskatchewan S7K 5X2

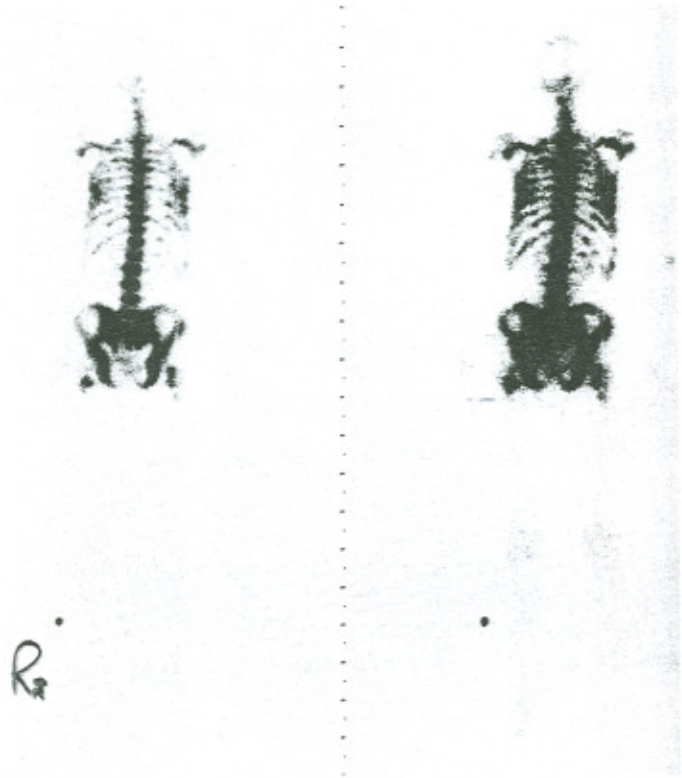

Figure 2 Case 1, note the multiple sites of increased radionuclide uptake (density) in pelvis, spine, ribs, and humeri.

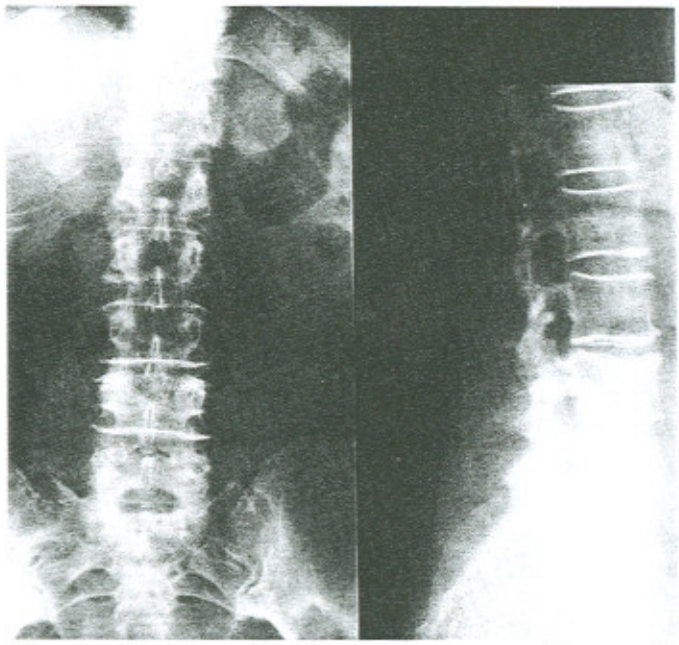

Figure 3 Case 2, generalized lumbar spine osteoporosis is seen with minimal degenerative disc disease being most prominent at L3-4. The AP view shows a well-circumscribed destructive lesion in the left ilium.

Mr. G.W.'s general practitioner was informed of the radiographic findings and arrangements were made for further investigations into the nature and extent of the disease. The patient was referred to an oncologist and the diagnosis of prostatic metastasis was confirmed. A bone scan showed wide spread metastases to the pelvis, spine, ribs, and humeri (Figure 3), while a chest x-ray failed to show any spread to the lungs.

Case two

Mrs. A.A., a 70-year-old woman, was referred to our clinic by her family physician with a complaint of left buttock, anterior thigh, and groin pain. This began insidiously, three weeks earlier, and was improving recently. Walking aggravated the pain while bed rest, 222's, and exdol (acetaminophen) relieved it. She described a past history of right lung cancer which was surgically removed. Her sleep was uninterrupted, and she had no systemic signs of disease.

On examination this pleasant lady looked well. She stood with a straight spine on a level pelvis and exhibited a full range of lumbar spine motion. On palpation no tenderness could be elicited with the exception of a diffuse tenderness in the left buttock musculature. There were no trigger points present. Sensation, motor power, and reflexes were normal. Straight leg raising was full and without discomfort. Hip joint range of

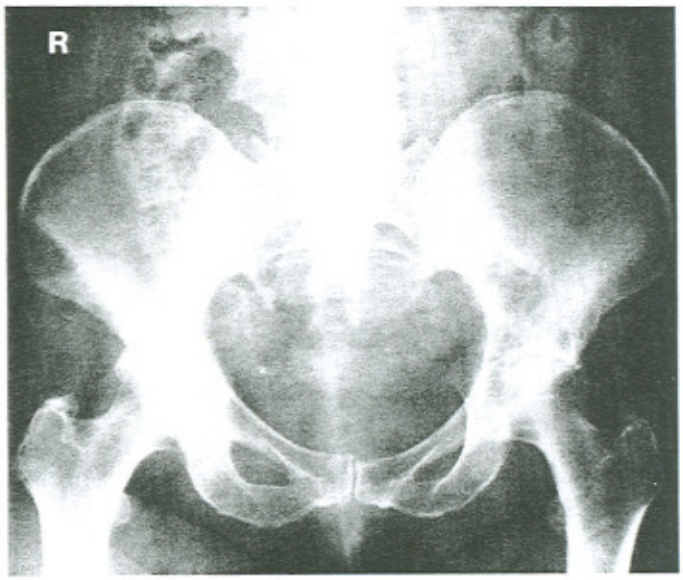

Figure 4 The AP pelvis in case 2 shows a well-circumscribed lytic lesion in the left iliac bone extending into the ischium in the region of the left acetabular roof. There is a second lesion in the right anterior superior iliac spine.

motion was full and pain-free bilaterally. Patrick's test was mildly uncomfortable, moreso on the left.

X rays of the lumbar spine and pelvis were ordered because of the lack of physical findings and a history of cancer. The lumbar views show generalized osteoporosis and minimal degenerative disc disease which is most prominent at L3-4 level. A destructive lesion is present in the left ilium extending into the ischium in the region of the left acetabular roof (Figure 3, Figure 4). Another similar lytic lesion is seen in the right ilium near the anterior superior iliac spine.

The patient was referred back to her family doctor for further evaluation and a diagnosis of bone metastasis from lung carcinoma was eventually proven.

Discussion

Prostatic and lung carcinoma, most commonly metastasize hematogenously to the vertebrae, femora, pelvis, skull, ribs, and sternum.[4,6] Prostatic metastasis accounts for 20.1 percent of spinal metastases, while lung metastasis accounts for 21.8 percent. In one study of spinal prostatic metastases, 61 percent of lumbosacral, 38 percent of thoracic and 3 percent of cervical spines were affected. In the same study, lung metastases affected 56 percent of lumbosacral, 44 percent of thoracic and no cervical spines. Only 64 percent of patients with spinal metastases experienced back pain.[5] Back pain was described in 93 percent of cervical spine, 43 percent of thoracic spine, and 76 percent of lumbosacral spine metastases.[5]

Most often the patient presents with a vague pain that is variable, worse at night, gradually increasing in severity, and not relieved by rest or recumbency. In fact, recumbency can aggravate the pain by applying direct pressure on the lesion. Sometimes the pain is decreased by standing or walking. An insidious onset of pain is common, but occasionally sudden onset can occur related to a fall, strenuous physical activity, or trauma. Metastases can be clinically silent or produce symptoms similar to primary tumors, including pain, signs of inflammation, deformity of bone, and pathological fractures. Back pain, with changes in urinary function such as decreased flow and/or urgency, can be clues of ominous back disease. Later in the disease the patient may display progressive emaciation, anemia, and excruciating bone pain. A history of previous malignant disease in a patient with insidious low-back pain is very important.

Physical findings are highly variable, and physical exam might not be initially rewarding. Local tenderness and paraspinal muscle spasm with limited spinal mobility may be the only findings. Lumbar spine metastases most commonly present with pain that is increased by motion and traction. A gibbus deformity might be present and can be associated with considerable tenderness over the area. Neurological deficit occurs in almost one third of prostatic vertebral metastases. Since prostatic metastases can affect any part of the vertebrae, some cases present with signs of cord compression. The thoracic and lumbar spine are equally affected with neurological deficit.[5] When neurological signs and symptoms are present, herniated lumbar discs and stenotic spinal canal syndromes are suspected rather than early metastatic disease.[2] A rectal exam is paramount in the diagnosis of prostatic metastases and many diagnoses are missed when the procedure is overlooked.[2]

On x-ray examination, prostatic metastases most commonly present with ill-defined areas of increased bone density. Areas of mottling, suggestive of destruction of bone, can also occur. Then there is usually a progression to complete loss of architectural landmarks. Lesions occur as discrete foci of variable sizes with ill-defined margins or as diffuse sclerosis. Rarely all bones are involved with a dense uniform sclerosis. There can be a uniform increase in density of the vertebral body described as an ivory vertebrae. If this disorder is combined with a periosteal reaction, causing an increase in vertebral body size, it is difficult to differentiate it from Paget's disease of bone. Any part of a vertebra can be involved.

Radiologically, lung metastases to bone are usually ill-defined and poorly marginated, but as shown in Figures 3 and 4 they can present as a sharply circumscribed destructive lesion. A purely osteolytic metastasis does not evoke reactive bone proliferation and, therefore, a periosteal reaction is rare. In the spine the bodies and pedicles are usually involved. Progression of the disease into the vertebral bodies often leads to wedge or wafer-like compression fractures. Cartilage is resistant to tumors, therefore, joint spaces are left intact.

The radionuclide bone scan is a very sensitive test for increased metabolic activity in bone, and is positive well before the lesions can be seen on plain spine radiographs. It is, therefore, a very important tool used for both diagnosis and disease follow-up.

Laboratory evaluation may disclose an increased serum alkaline phosphatase and hypercalcemia when bone metastases are present. Increased acid phosphatase is considered very specific for prostatic carcinoma. However, in one study of patients with proven prostatic metastases, 43 percent had no bone pain, 39 percent had normal acid phosphatase levels, 23 percent had normal alkaline phosphatase levels, 19 percent showed normal blood enzymes, and 62 percent had normal plain film radiographs.[6] In the same group, 24 percent with normal blood enzymes had a positive bone scan.

The percentage of patients with low-back pain due to metastases is small and it is, therefore, not always included in the differential diagnosis. The potential disaster of spinal metastasis should force the practitioner to think of this possibility. Diagnosis, however, is difficult to make in many instances. As in these cases, the history can appear as if the pain is from a mechanical lesion. At our clinic, we always x-ray patients with a history of trauma and disabling pain. This is especially true for patients over 50 years of age. Our general guideline of when to x-ray a patient appears in Table 1. It is not wise to accept another practitioner's diagnosis for back pain without a careful evaluation, or to treat a patient without reviewing x-rays that have been done elsewhere.

Table 1 GROUNDS FOR RADIOGRAPHIC EXAMINATION

Historical	Clinical
Severe pain	Neurological deficit
Night pain	Postural deformity
Chronic or recurrent pain	Lost R.O.M. (severe spasm)
Distal radiation of pain	Lasting sharp pain to percussion
Significant trauma	Others ...
Past operative treatment	
Past history of significant disease (Ca, R.A., etc)	
Over 50 years of age	
Non-physiological pain distribution	
Widespread bone tenderness	
Worker's compensation case	
Medicolegal case	
Insurance claims	
Others ...	

Conclusions

Gradual increasing pain of insidious onset that is not relieved by rest should raise suspicion of pathological backache. In many cases, however, the patient presentation is similar to mechanical backache. Plain film radiographs are a very important aid in diagnosis. It must be remembered, however, that at least 30 percent bone loss is needed before a change in plain film radiographs is seen. The absence of radiographic findings should not put your suspicions completely to rest. Blood tests including a serum alkaline phosphatase, serum acid phosphatase, serum calcium, and a bone scan are essential.

References

1 Rothman RH, Simeone FA: Spine. Philadelphia: Saunders, 1975: 820-826.
2 Finneson BE: Low Back Pain. Second Edition. Philadelphia: Lippincott, 1980: 519-527.
3 Harrison's Principles of Internal Medicine. Ninth Edition. New York: McGraw-Hill, 1980: 1771-1772.
4 Turek SL: Orthopaedics. Principles and their Application. Fourth Edition. Philadelphia: Lippincott, 1984: 671.
5 Schaberg J, Gainor BJ: A profile of metastatic carcinoma of the spine. Spine 1985; 10(1): 19-20.
6 Greenfield GB: Radiology of Bone Diseases. 3rd ed. Philadelphia: Lippincott, 1980: 380-391.