

## Paget's disease: a case study

LJ LaFrance, DC\*

JD Cassidy, DC, MSc (Orth), FCCS\*\*\*

JW Nykoliation, BSc, DC, FCCS\*\*

DR Mierau, BSPE, DC\*\*\*

*Patients with generalized musculoskeletal pain present a diagnostic dilemma for the chiropractor. All too often, the practitioner assumes mechanical causes for these symptoms. On rare occasions, Paget's disease accounts for chronic diffuse lumbosacral backache in older individuals, and practitioners must include this disease in their differential diagnosis. In this report, we present two such cases with a discussion of the pathogenesis, diagnosis, and treatment of Paget's disease.*

**KEY WORDS:** back pain, diagnosis, Paget's disease, chiropractic, manipulation

### Introduction

Paget's disease is a bone disorder of unknown etiology. Possible etiologies include an inflammatory disease, an endocrine disorder or a paromyxovirus. Characteristic features of the disease include an increase in bone resorption (osteoclastic activity) followed by an increase in bone formation (osteoblastic activity). The disease process passes through a three-stage continuum. The three stages are, lytic (caused by increased osteoclastic activity), mixed (having both accelerated osteoclastic and osteoblastic activity), and sclerotic (being dominated by osteoblastic activity).

Paget's disease affects 1-3% of people over 40 and 10% of people over 80 years of age.<sup>1,2,3,4</sup> It is often asymptomatic in the early stages. As the disease progresses, a variety of symptoms can occur including non-descript dull, boring pain and exhaustion. Exhaustion is thought to be related to increased bone vascularity stressing the cardiovascular system. Signs include deformity and neurological deficit. The typical radiographic findings are important in diagnosis and monitoring progression of the disease. Radiological findings include cortical thickening, decreased radiodensity, coarsened trabeculae and deformity.

Many serious complications including sarcomatous degeneration, high output cardiac failure and pathologic fracture are associated with Paget's disease. The seriousness of the complications, however, demands medical followup.

Treatment is mainly symptomatic, and chiropractors can play an important role in the diagnosis, treatment, and monitoring of these patients. As Paget's disease is most commonly asymptomatic,

*Les patients souffrant de douleurs squelette-musculaires généralisées présentent un dilemme pour le chiropraticien au niveau du diagnostique. Trop souvent, le praticien assume que ces symptômes ont des causes mécaniques. À de rares occasions, la maladie de Paget est responsable de douleurs dorsales sacro-lombaires diffuses chez les personnes âgées et les praticiens doivent inclure cette maladie dans leur diagnostic différentiel. Dans le présent rapport, nous présentons deux cas de ce type, avec une discussion de la pathogenèse, du diagnostic et du traitement de la maladie de Paget.*

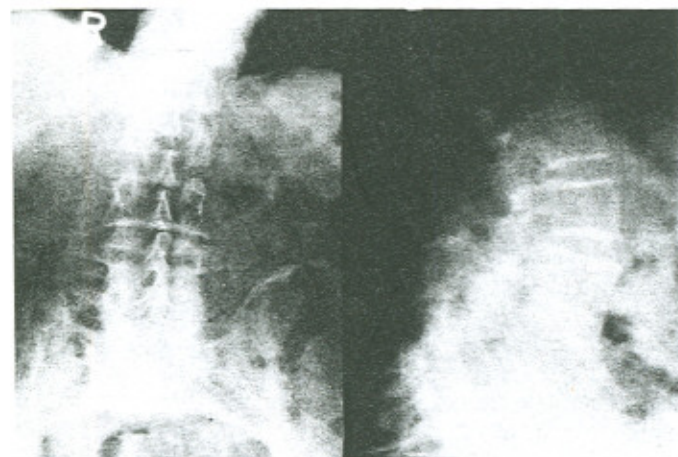
**MOTS CLÉS:** douleur dorsale, diagnostique, maladie de Paget, chiropractie, manipulation.

it is usually discovered when laboratory tests or radiographs are ordered for other reasons.

### Case one

Mr. C.K., an 84-year-old gentleman, presented to our clinic on March 6, 1985, complaining of low-back pain of one week in duration. This began after snow-shovelling and was accompanied by mild posterior right leg pain to the knee level. His pain was aggravated by movement and relieved by heat. There was no associated night pain or bowel or bladder difficulties. He was otherwise in good health.

On examination, he stood with an accentuated lumbar lordosis and a palpable step defect. Range of motion of the lumbar spine was normal for his age with severe pain on extension. Sensation, motor power, and deep tendon reflexes in his lower extremities were normal. The plantar responses were downgoing. Straight leg raising was 80 degrees bilaterally.



**Figure 1** Case 1, an 84-year-old male. Note generalized osteoporosis with coarsening of the trabecular pattern of the sacrum and the L3, 4, and 5 vertebral bodies.

\* Clinical resident IV, CMCC, Toronto

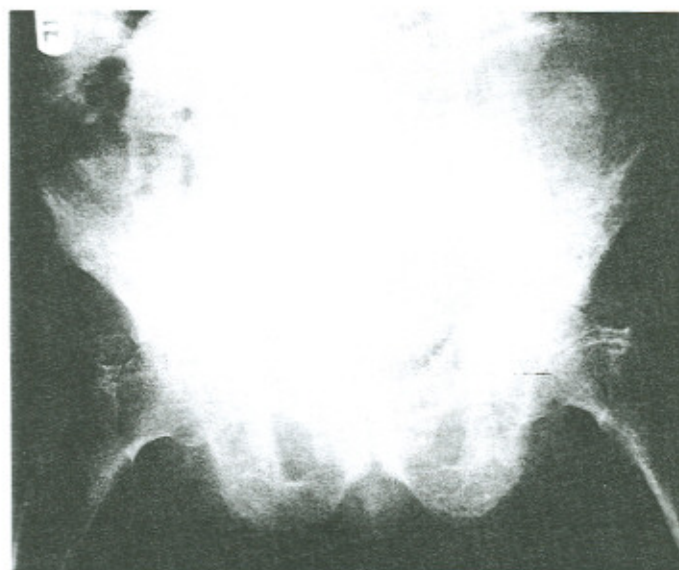
\*\* Fourth Avenue Chiropractic Clinic, Saskatoon

\*\*\* Department of Orthopaedics, University of Saskatchewan

Reprint requests to: Dr. J.D. Cassidy, Department of Orthopaedics, University Hospital, Saskatoon, Saskatchewan S7N 0W0

© LJ LaFrance, JD Cassidy, JW Nykoliation, DR Mierau 1987





**Figure 2** Case 1, note the generalized osteoporosis and coarsening of the trabecular pattern in the pelvis and femora. Some cortical thickening is seen in both femora and at the pelvic brim.

There was marked tenderness over his lumbosacral joints with marked paraspinal muscle hypertonicity.

X-rays of the lumbar spine and pelvis showed generalized osteoporosis with coarsening and distortion of the trabecular pattern of the L3, L4 and L5 vertebral bodies, the pelvis, sacrum, ilia and both femora (Figures 1 and 2). Cortical thickening was also seen in the pelvis and femora (Figure 2). Joint space thinning was evident in both hips and at the L4-5 and L5-S1 levels. Both sacroiliac joints were partially fused. These findings are consistent with a diagnosis of Paget's disease.

Mr. C.K. was treated with daily gentle mobilizations of his lumbar spine for acute strain. One week passed and he had considerable relief from pain. Mr. C.K. was referred to his medical doctor for further management of his Paget's disease.

### Case two

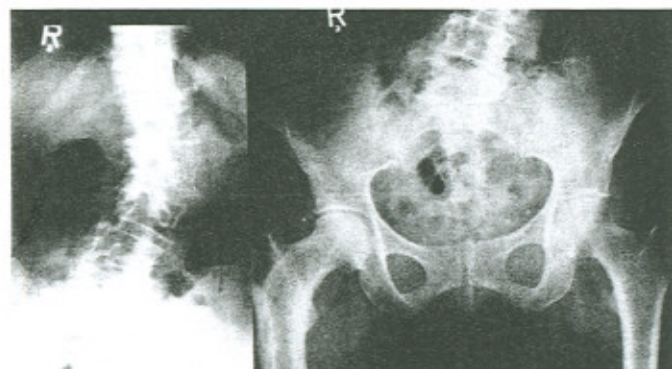Mrs. A.H., a 68-year-old woman presented at University Hospital on January 3, 1986, with a complaint of chronic intermittent low-back pain and spinal curvature. Approximately 8-10 years previously she had a severe episode of back pain and spasm which confined her to bed for at least two weeks. At that time an orthopaedic surgeon was consulted and she was given exercises and a brace. Presently, she uses an elastic support rather than the brace. Since that episode she has had hypoesthesia and paresthesia in the left buttock. Approximately six months ago her low-back pain radiated into her right buttock and then down her right anterior thigh to the knee. This pain was dull and aggravated by bending and lifting. She also experienced back pain and right shin pain while in bed at night. She could not stand on her right leg due to pain in the upper leg and knee, but

did not complain of any numbness, paresthesia, or weakness in the legs. She had retired eight years previously due to her back problems.

On examination, she walked with a slight right Trendelenburg gait. There was a positive Trendelenburg's sign on the right. Range of motion of the lumbar spine was full in all planes. The patient had a convex left lumbar scoliosis with a prominent left flank and a mild convex right thoracolumbar compensatory curve. She was moderately tender over the L5-S1 posterior joints, both sacroiliac joints, and over the gluteus medius muscles bilaterally. Her straight leg raise was 90 degrees bilaterally without pain. Sensations and reflexes were normal and the plantar responses were downgoing. Muscle strength was normal with the exception of the right hip abductors which were graded at 4/5. The range of motion of the right hip was globally decreased when compared to the left. The patient had mild tenderness over the lateral aspect of the proximal right femur, and anterior tibia. Patrick's test was positive on the right and the right leg was short by 1.5 cm. No swelling was noted in the lower limbs.

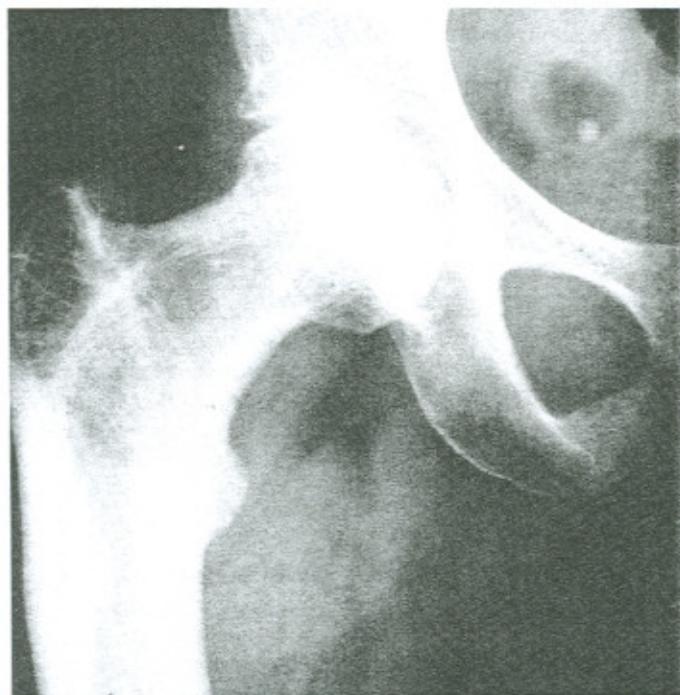
Radiographs of July 1985 showed increased bone density and cortical thickening of the proximal right femur with a coarse trabecular pattern and a lytic area at the greater trochanter. Films taken on January 3, 1986, showed some cortical infarctions at the lateral cortex of the right proximal femur (Figures 3 and 4). The femoral neck was in a slight degree of varus compared to the left side. Dynamic views of the lumbosacral spine showed a marked lumbar scoliosis with a minimal compensatory curve at the thoracolumbar junction. Marked degenerative changes were noted at L4-5 and L5-S1 with some wedging of the L5 vertebra. The left L5 pedicle was indistinct and a hemivertebra was suspected at that level.

Mrs. A.H. was treated daily for two weeks with muscle stimulation (TNS) to the left paraspinal and gluteus medius muscles, gentle mobilization of the sacroiliac joints and at the



**Figure 3** Case 2, note the marked lumbar scoliosis with the L5 hemivertebrae. The AP view of the pelvis looks normal with the exception of the right femur which shows a slight varus deformity, cortical thickening, coarsened trabeculae, and cortical infarctions or pseudofractures (also see Figure 4).





**Figure 4** Case 2, note cortical thickening, coarsened trabeculation, incomplete infractions or pseudofractures, and slight varus deformity of the right femur.

same time she began medication for her Paget's disease. She was given a cane to use on the left side. At the end of two weeks she was markedly improved and returned home.

### Discussion

Paget's disease may present in a monostotic (solitary bone) or polyostotic (multiple bone) form in approximately 1-3% of individuals over 40 years of age and approaches 10% for the 80 plus age group. The incidence is high in the United Kingdom, Australia, and New Zealand while it is rare in Norway and Holland, and virtually unknown in Asia, Africa and Sweden.<sup>4,5</sup> Males are affected more commonly than females.<sup>2,6,7</sup> When polyostotic, the axial skeleton (spine, pelvis, skull, and proximal femora) is predominantly involved.

Patients with Paget's disease usually present with a complaint of non-descript, dull, boring pain that occasionally is shooting. Often the disease is an incidental finding (case 1). The pain is usually located at the site of disease, may be worse at night, exacerbated by weight bearing, and can be severe. The patient may become aware of gradual swelling or deformity. Bone softening and thickening may lead to deformity, especially bowing of weight bearing long bones. The tibia bows anteriorly and the femur anterolaterally; both often cause gait disturbances. Neurological complications include nerve root or cord compression symptoms which are most common in the thoracic

spine. Headaches, auditory disturbances, and internal hydrocephalus are symptoms of cranial involvement. Pagetic bone is highly vascular and skin temperature over the involved bone is warm to touch.

Laboratory tests are normal with the exception of alkaline phosphatase which may be normal with solitary bone involvement, but is always elevated with multiple bone involvement. Urinary hydroxyproline is usually elevated. Calciuria is often present and can lead to increased stone formation.<sup>6,8,9</sup>

Radiographic findings vary depending on the stage of the disease. The first or active osteolytic stage gives well-defined areas of radiolucency, known as osteoporosis circumscripta in the skull and the pathognomic "blade of grass" sign of V-shaped subarticular lucency in long bones. During the mixed stage there is both osteolytic and osteosclerotic activity. Some cortical thickening begins and the long bones may show epiphyseal and metaphyseal sclerosis with diaphyseal lucency. Osteoporosis circumscripta of the skull is accompanied by focal areas of sclerosis. In the third stage, osteosclerosis is the dominant finding giving the skull a thickened vault with "cotton wool" areas of sclerosis. The lumbar spine will show enlarged vertebrae, coarsened trabeculae, and cortical thickening which may produce a "picture frame" vertebra. An ivory vertebrae may also occur with marked sclerosis. Coarsened trabeculae and cortical thickening with encroachment on the medullary canal are the classical findings in the long bones. The pelvis classically has a thickened "pelvic brim" caused by cortical thickening, and is often affected asymmetrically with both resorptive and active new bone formation occurring.

In general, bones showing enlargement with irregularly widened cortex in a coarse striated pattern, coarsened trabeculae, increased density, and bone deformity usually indicates Paget's disease. Basilar invagination, protrusio acetabuli, and perpendicular lines of radiolucency on the convex side of bowed long bones (cortical infractions or pseudofractures) are also important signs found in Paget's disease.

There is quite an extensive differential diagnosis for the radiographic findings of Paget's disease. Of primary concern with polyostotic disease are osteoblastic metastases to the pelvis from prostatic carcinoma or lymphoma. Hodgkin's disease, lymphosarcoma, and hemangioma can be present in a single vertebra, but do not show an increase in the size or cortical thickening of the vertebrae.

### Four major complications

The four major complications are cardiac failure, pathological fractures, bed rest induced hypercalcemia and malignant degeneration. Malignant degeneration in polyostotic disease can occur in 0.9% to 20%.<sup>4,8</sup> Populations with more polyostotic and symptomatic disease have a higher rate of sarcomatous degeneration and account for the high end of this percentage. The average Pagetoid population has a 0.9%-2% incidence of malignant degeneration with men being affected twice as often as women.<sup>4</sup> The most common sarcomas are osteosarcoma



(50%), fibrosarcoma (25%), and chondrosarcoma (10%).<sup>8</sup> Sarcomas are usually recognized with an increase in pain and swelling, or a marked increase in the serum alkaline phosphatase above the already elevated level found in Paget's disease. The prognosis is extremely poor and ablative surgery is rarely successful. Two studies done showed an 8% and 0% five year survival rate with a median survival rate of 17 months.<sup>4</sup>

Blood flow is markedly increased with proliferation of blood vessels in pagetic bone. If 1/3 or more of the skeleton is involved, the increased blood flow, especially in the elderly, may be associated with high output cardiac failure.<sup>9</sup> The cardiovascular system is also affected by arterial and intracardiac (mitral and aortic valve) calcifications.

Pathological fractures occur in approximately 8% of Paget disease cases.<sup>7</sup> Most commonly they are multiple incomplete fissure fractures (Figure 4) or infarctions (pseudofractures) occurring on the convex side of weight bearing bones. These can often be precursors to more serious fractures that are transverse and complete, resembling bone that was snapped like a piece of chalk. Ten percent of chalk stick fractures lead to non-union. The presence of fractures, either complete or incomplete, can cause further complications if bedrest is instituted. Bedrest in a Pagetic patient causes reduced skeletal stress and, therefore, greatly diminishes new bone formation even though osteoclastic resorption continues. This leads to severe and at times fatal hypercalcaemia.

### Treatment

Paget's disease is usually localized in its distribution and does not cause symptoms, therefore, many patients do not require treatment. Treatment is symptomatic and supportive since there is no cure for Paget's disease. Indications for treatment are severe bone pain, cardiac failure, fracture, hypercalcaemia, disabling deformity, neural compression, and hypercalciuria with or without renal stones.

Pain is usually controlled by analgesics or indomethacin. Glucocorticoids, although not well tolerated, do aid in disease suppression and help control pain and high cardiac output. Orthotics and surgery may be needed to deal with deformity and fracture, but can be a problem since ambulation is so important in Pagetic patients. Porcine, salmon, and human forms of calcitonin are used as the present form of therapy. It causes a reduction in osteoclastic bone resorption and an associated return of urinary hydroxyproline and serum alkaline phosphatase values to normal as well as symptomatic and histological improvement. Human calcitonin is by far the best due to a lesser risk of neutralizing antibody formation, however, this complication may still develop. Cytotoxic drugs such as mithramycin have been used and have proven effective, but their long-term use has potential risks even though these risks have not yet materialized. Diphosphonates have proven to be more effective than calcitonin in normalizing indexes of bone resorption. Serum alkaline phosphatase and urinary hydroxyproline excretion remain decreased for several months after the withdrawal of

diphosphonates and only gradually return to the pre-treatment levels.

Patients can suffer from mechanical back pain and muscle syndromes aside from the bone pain of Paget's disease. Chiropractors can play an important role in the treatment of these problems as well as contribute to symptomatic relief of the bone disease. Care must be taken when manipulating patients suffering from this bone softening disease. In fact, gentle non-thrust mobilization is probably the treatment of choice when the spine is involved. Bed rest should be avoided in the treatment program as it decreases osteoblastic activity through decreased bone stress. The patient's neurological and cardiovascular status should be continually monitored and medical assessment is recommended. Sudden increases in symptoms may represent sarcomatous degeneration. Any changes indicating serious complications demand immediate medical assessment.

### Conclusion

Paget's disease is a disease of unknown etiology that affects between 1-10% of today's elderly. When it is symptomatic it can be helped with medication. As illustrated in the two case reports, patients can suffer from many musculoskeletal problems in association with or caused by the disease process. These patients may be aided through soft tissue therapy, therapeutic modalities, or gentle mobilization and manipulation. It is, however, very important to remember that only symptomatic treatment is being provided and this disease can have some serious complications.

### References

- 1 Chapman S, Nakiely R. Aids to radiological differential diagnosis. London: Bailliere Tindall, 1984: 320-321.
- 2 Harris NH. Postgraduate textbook of clinical orthopaedics. Boston: Wright, 1983: 316-319.
- 3 Rosse C, Clawson DK. The Musculoskeletal system in health and disease. Hagerstown: Harper and Row, 1980: 343-345.
- 4 Yochum TR. Paget's sarcoma of bone. Radiology, 1984; 24: 428-433.
- 5 Meal CM. Paget's disease. European J Chiropractic, 1983; 31: 107-110.
- 6 Gartland JJ. Fundamentals of orthopaedics. Third Edition. Toronto: WB Saunders Company, 1979: 129-132.
- 7 Greenfield GB. Radiology of bone diseases. Third Edition. Philadelphia: JB Lippincott Company, 1980: 108-123.
- 8 Cotta H. Orthopaedics. Chicago: Year Book Medical Publishers, 1980: 147-150.
- 9 Isselbacher KJ, et al. Harrison's Principles of Internal Medicine. Ninth Edition. New York: McGraw-Hill Book Company, 1980: 1860-1863.
- 10 Eisman JA, Martin J. Osteolytic Paget's disease: recognition and risks of biopsy. J Bone Joint Surg, 1986; 68-A: 112-117.