0008-3194/89/71–75/$2.00/©JCCA 1989

Ossification of the posterior longitudinal ligament: a case report

PD Aker, BSc, DC*
SM O'Connor, DC**
SA Mior, DC, FCCS(C)***
D Beauchemin****

Ossification of the posterior longitudinal ligament (OPLL) has recently been recognized as a clinical entity. It is a rare condition, having a higher incidence in the Japanese population. It is characterized by hyperplasia of cartilage cells with eventual endochondral ossification of the posterior longitudinal ligament. The radiographic signs are characteristic and consist of a linear band of ossified tissue along the posterior margin of the vertebral body. OPLL can be associated with mild to serious neurological complications due to spinal cord or nerve root compression, or it may be asymptomatic. This paper reviews the radiological, clinical and therapeutic aspects of this rare condition. (JCCA 1989; 33(2): 71–75)

KEY WORDS: ossification of the posterior longitudinal ligament (OPLL), cervical spine, chiropractic, stenosis, manipulation.

L'ossification du ligament longitudinal postérieur (OLLP) a été reconnue dernièrement comme une pathologie clinique distincte. C'est une affection rare, ayant une fréquence plus élevée dans la population d'origine japonaise. Elle se caractérise par l'hyperplasie des cellules cartilagineuses et s'accompagne à long terme d'ossification endochondrale du ligament longitudinal postérieur. Les signes radiologiques caractéristiques consistent en un bandeau linéaire de tissu ossifié le long de la face postérieure du corps vertébral. L'affection peut s'accompagner de complications neurologiques légères ou graves en raison de la compression de la moëlle épinière ou de la racine du nerf, ou peut être asymptomatique. La présente communication permet de faire le point sur les aspects radiologiques, cliniques et thérapeutiques de cette maladie fort rare. (JCCA 1989; 33(2): 71–75)

MOTS CLEFS: ossification du ligament longitudinal postérieur (OLLP), épine dorsale cervicale, chiropratique, sténose, manipulation.

Introduction

Ossification of the posterior longitudinal ligament (OPLL) of the cervical spine has only recently been recognized as a clinical entity. Although it was reported as early as 1839 by Key[1], it was not until 1960 that it became associated with chronic cervical myelopathy.[2] It was later termed OPLL by Terayama et al., in 1964.[3] Since then, numerous cases have appeared in the literature, largely, though not exclusively, occurring in the Japanese population. Thus, it is the intention of this case report to introduce the reader to the etiology, pathology, diagnosis, and treatment of ossification of the posterior longitudinal ligament.

* Clinical Resident, CMCC
** Clinical Radiologist, CMCC
*** Coordinator, Clinical Residency Programme, CMCC
**** Senior Intern, CMCC
Reprint requests to: PD Aker, Canadian Memorial Chiropractic College, 1900 Bayview Avenue, Toronto, Ontario M4G 3E6.

The etiology of OPLL remains obscure. The proposed mechanisms include infection, previous trauma, fluoride intoxication, diabetes mellitus, genetic transfer, and an immunogenic disorder related to HLA antigens.[4,5,6,7] Although no single cause has been accepted to date, the predominance of OPLL amongst the Japanese suggests that it may be the result of hereditary or geographic factors.[11]

This higher incidence of OPLL in the Japanese population is reported to be in the order of two to three percent.[7] This incidence increases significantly to approximately 30% among family members of second order kinship to the patient.[3] OPLL has also been seen in up to 50% of patients with diffuse idiopathic skeletal hyperostosis (DISH),[5,8,9,10,11] raising the question of a generalized hyperostotic tendency in these individuals. Of those presenting with OPLL of the cervical spine, the majority tend to be between 50 and 60 years of age, with a male to female ratio of about three to one.[5,12]

Pathology

The pathologic characteristics of OPLL have not been well described. Some authors suggest there is a metaplasia and

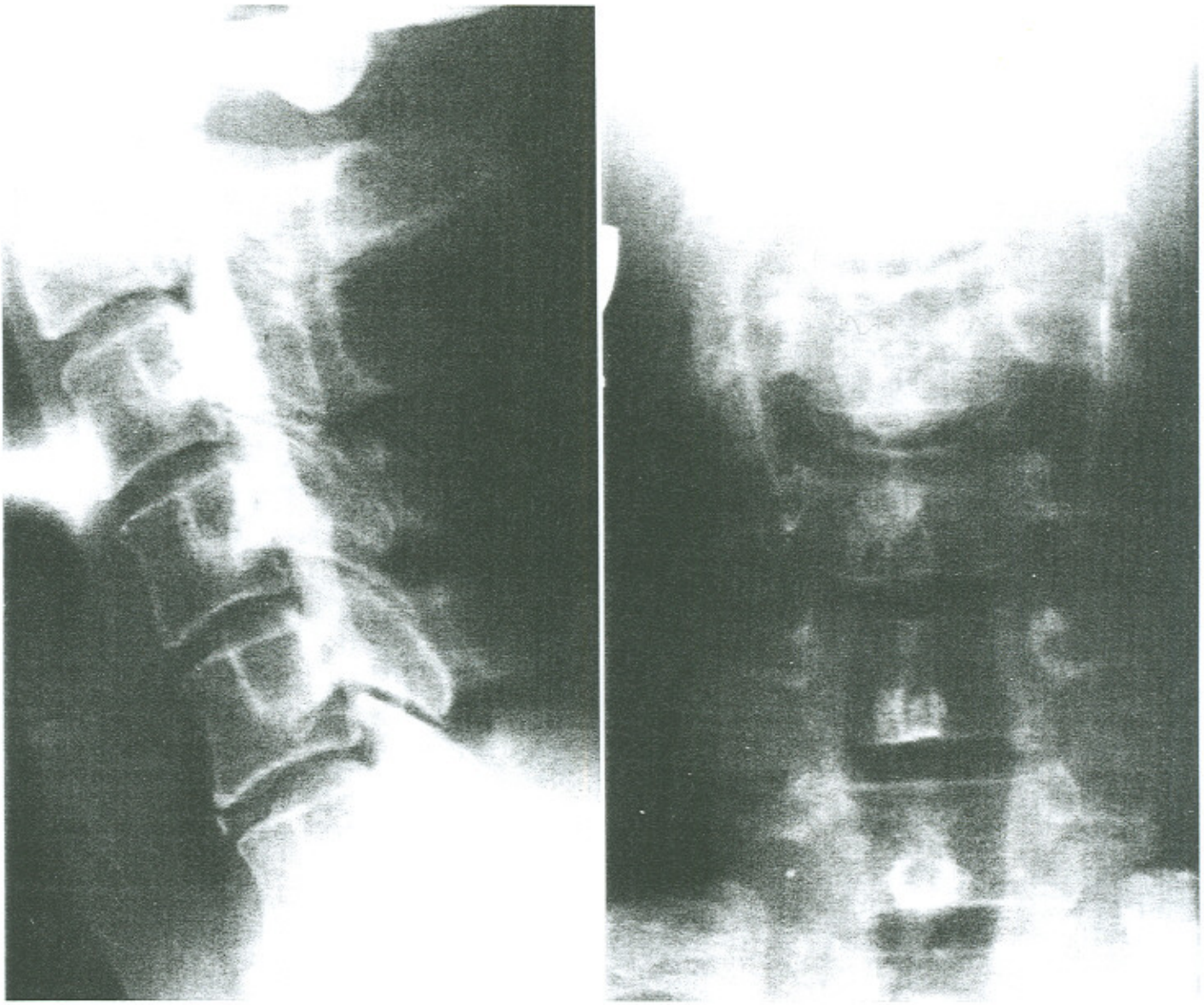

Figures 1 and 2 Neutral lateral and anteroposterior lower cervical radiographs. Note the faint density overlying the tracheal air space on the AP projection. The lateral projection demonstrates a dense osseous bar extending from the posterior margins of C2 through C7. Annular calcification with associated degenerative changes are noted at C6-7.

proliferation of cartilage cells within the posterior longitudinal ligament, which eventually undergo endochondral ossification.[5,11] The newly ossified ligament may attach directly to the posterior vertebral body margin or be separated from it by intervening dense connective tissue.[5] As a result of this osseous transformation and eventual increase in the thickness of the ligament, flattening and compression of the adjacent spinal cord and surrounding blood vessels may result.[5] This resultant spinal cord and vascular compression may lead to areas of infarction within the grey matter, as well as demyelinization of the long tracts within the white matter.[7] This may explain the neurological deficits commonly seen in patients with OPLL. Ono et al. suggest a correlation may exist between the thickness of the osseous bar visualized on the lateral cervical spine roentgenogram and the presence of neurological manifestations.[5]

Case report

A 56-year-old Japanese man presented with a complaint of

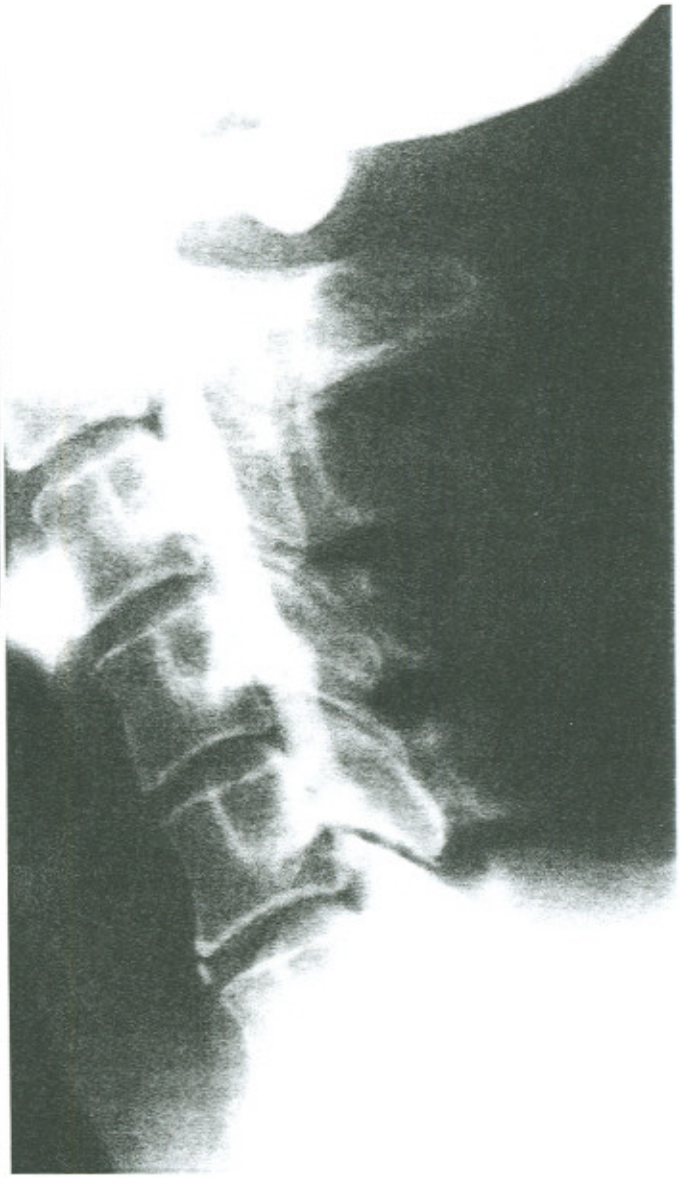

Figures 3 and 4 Lateral cervical views in flexion and extension, demonstrating overall decreased mobility of the cervical spine.

neck, right shoulder, and upper arm pain of two weeks duration. The pain began as a stiffness at night which became worse by morning. It was described as dull and aching, with radiation down the posterolateral aspect of the upper right arm. The pain was exacerbated by forward flexion and right lateral flexion of the cervical spine. There was a history of a minor motor vehicle accident approximately two years prior to presentation, but otherwise he reported no previous neck complaints.

On examination, the active ranges of movement of the cervical spine were painfully decreased by approximately 10 percent of normal, except left lateral bending and left and right rotation which were decreased by 50 percent. Resisted testing in forward flexion and right lateral flexion reproduced the upper arm pain. There was palpatory tenderness and segmental restriction of the mid-cervical facet joints on the right. Hypertonicity was noted bilaterally in the posterior cervical, infraspinatus, supraspinatus and trapezius muscles, but moreso on the right. Neurological examination including sensory, motor, and reflex

testing, and a screen for upper motor neuron lesions, was unremarkable.

Radiographs of the cervical spine were taken, including anteroposterior, lateral, flexion and extension views. An osseous bar extending from the posterior margins of the C2-C7 vertebral bodies was visualized (figure 1). There was loss of the cervical lordosis. Moderate degenerative changes with annular fiber calcification were noted at the C6-7 discal level (figures 1 and 2). Flexion and extension views were taken which revealed a generalized decrease in mobility in both flexion and extension (figures 3 and 4). A diagnosis of ossification of the posterior longitudinal ligament was made on the basis of the roentgenologic findings. A clinical impression of cervical facet irritation in the mid-cervical region on the right with concomitant muscular hypertonicity was made.

Treatment was directed towards increasing functional mobility of the cervical spine. Trigger point therapy, gentle stretching, and interferential current were used to reduce muscle tightness. Low-amplitude, low-velocity manipulations were directed towards the restricted mid-cervical segments.

The patient reported significant (80%) relief from symptoms after four treatments over a course of two weeks. Follow-up visits at one, two, and three months revealed 100% relief with recovery of pre-injury ranges of motion.

Considering the potential for serious complications that can be associated with OPLL, a neurosurgical consultation was arranged. The neurological consultation, which took place four months after presentation, revealed normal neurological status. Only mild restrictions of global cervical motion remained and there was no cervical tenderness. No definitive management was necessary and the patient was cautioned against cervical trauma and advised to promptly report any changes in symptomatology.

Discussion

As a consequence of the slow, progressive development of this disorder, symptoms tend to develop insidiously. This pattern of slow onset may be noted in up to 95% of those affected[7], although occasionally a traumatic event may precipitate acute manifestations. Therefore, OPLL may present with a variety of signs and symptoms based on the degree and location of spinal cord or nerve root compression, or it may be entirely asymptomatic.[12]

The most common neurological presentations are those consisting of long tract signs, nerve root signs, and neck or arm pain. At the time of diagnosis, approximately 25% will have serious difficulty in ambulation and will be dependent on others for activities of daily living.[7] In fact, cases of urinary and rectal incontinence or dysfunction, as well as loss of libido have also been reported.[7]

In an effort to qualify the location of neurological compression, Ono et al.[5] observed a group of 166 symptomatic patients and divided them into three distinct groups:

1 those with cord signs, consisting of motor and sensory disturbances of the lower extremity (56% of total);
2 those with segmental signs, consisting predominantly of motor and sensory disturbances of the upper extremity (16% of total); and
3 those with cervicobrachialgia, including neck, shoulder, and/or arm pain (28% of total).

The case report described herein falls into this third group of cervicobrachialgia, with relatively mild neck and arm symptoms and normal neurological status, which may or may not have been the result of OPLL.

There are no characteristic diagnostic laboratory findings for OPLL, although there may be a slightly increased frequency of diabetes mellitus among these individuals.[5,7,14]

Diagnostic Imaging

The definitive diagnosis of OPLL is made by its characteristic radiological findings. The ossification is most commonly noted in the mid-cervical region, extending from three to five cervical segments. OPLL can extend to involve the thoracic and lumbar regions. Several cases have been reported, often associated with more severe clinical manifestations than those involving only the cervical spine.[7,14] Characteristically, a dense, linear, ossified strip, measuring one to five mm in thickness is noted extending along the posterior margin of the vertebral bodies. The ossification may be confined to one or several vertebral bodies without involving the discs or may extend continuously for several vertebrae and disc spaces (figure 2). A thin, radiolucent zone may be seen separating the osseous strip from the vertebral body. The intervertebral disc spaces and apophyseal joints are generally not affected. It is important to recognize OPLL, as but one of a number of different etiologies which may produce stenosis of the spinal canal. Although numerical values vary, the critical degree of spinal canal stenosis before danger of vascular and spinal cord compression occurs, is reportedly somewhere between 50–60% of the sagittal diameter of the spinal canal.[12]

Computed axial tomography with sagittal reformatting provides an excellent, non-invasive assessment of the configuration of the ossification and the degree of narrowing of the spinal canal and intervertebral foramen. Nuclear magnetic resonance imaging plays a role in demonstrating the extent of spinal cord compression with the osseous mass.

In addition to the ossified band, distinct anterior osteophytes and enthesopathic changes (DISH) are seen in over 20% of cases of OPLL.[8,15] The distinctive radiographic appearance of OPLL should not be mistaken for any other disorder. For example, spondylosis deformans will demonstrate triangular osteophytes arising adjacent to the vertebral endplates and extending horizontally. In contrast, the syndesmophytes of ankylosing spondylitis (AS) extend vertically from one vertebra to the next and are more prominent anteriorly. In addition, ossification of the posterior longitudinal ligament is not typically seen with AS. Psoriatic and Reiter's spondylarthropathies are characterized by large asymmetric areas of paravertebral ossification.[12]

Treatment

Tsuyama, in a recent paper on OPLL, states that in cases that are not surgical emergencies, up to 70% of patients will respond favorably to conservative treatment.[7] The conservative measures are reportedly aimed at immobilization of the neck using skull traction, bed rest and/or neck bracing. These measures may reduce the neurological disturbances that are present due to the mechanical pressure or friction placed upon the spinal cord by the ossified ligament. Consequently, the methods used are dependent upon the extent of neurological deficits.

Patients which are categorized into Ono et al.'s Group 3, present with signs and symptoms of cervicobrachialgia. In these patients, the myofascial structures and posterior joints may be the etiological factors in the production of pain and OPLL may be an incidental finding. Thus, these patients may benefit from conservative therapy which emphasizes the maintenance of functional movement rather than stressing immobilization. As seen in the above case report, specific attention to the myofascial structures using soft tissue massage and electrotherapy may be helpful. The fixations noted upon palpation are treated with very gentle non-force (low amplitude, low velocity) manipulations. This is important, since forceful manipulation may, as would any traumatic event, precipitate further endochondral ossification with devastating results. It is for this reason, some authors believe that manipulation of the cervical spine is contraindicated.[16]

Regardless of which group the patient is categorized into, neurosurgical consultation is recommended as soon as the diagnosis is confirmed, since long-term compression on the cord and adjacent blood vessels may lead to irreversible changes.[3] Surgery is indicated when the principle symptoms are long tract signs, such as gait disturbance or bowel and bladder dysfunction.[5] Operative procedures are aimed at decompression of the spinal canal and stabilization of the cervical spine. Laminectomy, canal widening, and anterior interbody fusion are the procedures most commonly utilized.[7] This condition is a prime example of how interdisciplinary communication is essential to a favorable outcome.

Conclusion

Ossification of the posterior longitudinal ligament, although a relatively uncommon finding in the North American population, is important to recognize as a cause of cervical spinal canal stenosis. It may result in compression of the spinal cord or nerve roots, and can cause permanent neurological damage. The radiographic signs of OPLL are diagnostic, and consist of a linear band of ossified tissue along the posterior margin of the vertebral bodies. A thorough history and examination will determine the plan of management, which can vary from mobilization to rest and immobilization, and possibly surgical decompression. Careful conservative management of these cases may be beneficial in relieving pain of myofascial and joint origin. Early surgical consultation, however, is emphasized as symptoms can progress.

Acknowledgement

The authors would like to acknowledge the financial contribution provided by the Ontario Chiropractic Women's Auxiliary.

References

1 Key CA. On paraplegia depending on disease of the ligaments of the spine. Guy's Hospital Rep 1839; 3: 17–34.
2 Tsukimoto H. An autopsy report of syndrome of compression of spinal cord owing to ossification within spinal canal of cervical spine. Arch Jpn Chir 1960; 29: 1003–1007.
3 Terayama K, Maruyama S, Myashita R, Minai K, Kirosheta M, Shimizu Y, Machizuki I. Ossification of the posterior longitudinal ligament in the cervical spine. Orthop Surg 1964; 15: 1083–1095.
4 Bakay K, Cares HL, Smith RJ. Ossification in the region of the posterior longitudinal ligament as a cause of cervical myelopathy. J Neurol Neurosurg Psychiatry 1970; 33: 263–268.
5 Ono K, Ota H, Tada K, Hamada H, Takaska K. Ossified posterior longitudinal ligament: a clinicopathologic study. Spine 1977; 2(2): 126–138.
6 Okamoto Y, Yasuma T. Ossification of the posterior longitudinal ligament of the cervical spine with or without myelopathy. J Jpn Orthop Assoc 1967; 40: 1349–1360.
7 Tsuyama N. The ossification of the posterior longitudinal ligament of the spine. Clin Orthop 1984; 184: 71–84.
8 Resnick D, Guerra J Jr, Robinson CA, Vint VC. Association of diffuse idiopathic skeletal hyperostosis (DISH) and calcification and ossification of the posterior longitudinal ligament. AJR 1978; 31: 1049–1053.
9 Malgham J, Nagent de Deuxcharones Ch, Rombouts-Lindemans C, Dory M, Maldagne B. Ossification of the posterior longitudinal ligament of the cervical spine: report of a case with computed tomographic study and associated with Forrestier's disease. J Belge Radiol 1979; 62: 69.
10 Hukuda S, Mochizuki T, Ogata M, Shichitawa K. The pattern of spinal and extraspinal hyperostosis in patients with ossification of the posterior longitudinal ligament and ligamentum flavum causing myelopathy. Skel Radiol 1983; 10: 79.
11 Hashizume Y. Pathological studies on the ossification of the posterior longitudinal ligament (OPLL). Acta Pathol Jpn 1980; 30: 255–273.
12 Resnick D. Diagnosis of Bone and Joint Disorders, Toronto; WB Saunders, 1981: 1603–1615.
13 Nakanishi T, Mannan T, Tsyokura Y. Asymptomatic ossification of the posterior longitudinal ligament of the cervical spine. J Neurol Sci 1973; 19: 375.
14 Ono M, Russell JR, Kudo S, Kuroiwa Y, Takamori M, Motomura S, Murakami J. Ossification of the thoracic posterior longitudinal ligament in a fixed population: radiological and neurological manifestations. Radiology 1982; 143(2): 469–474.
15 Van der Kolk G, Penning L. Ossification of the thoracic posterior longitudinal ligament. Eur J Radiol 1984; 4: 221.
16 Foreman, SM. Ossification of the posterior longitudinal ligaments: a cause of spinal stenosis syndrome. JMPT 1985; 8(4): 251–255.