

Influence of MRI field strength on clinical decision making in knee cartilage injury – A case study

Glenn Cashman, DC, MSc*

Raj Attariwala, MD, PhD, FANM, FRCPC**

Objective: *To increase clinicians' awareness of the differences in image resolution and potential diagnostic accuracy between small and large-field MR Scanners. To present an example of a clinical decision making challenge in how to proceed when knee MRI and clinical findings don't agree.*

Clinical Features: *A 38 year old female mountain biker presented with knee pain and clinical features strongly suggestive of a torn meniscus or loose bodies. An initial MRI using a small field strength (0.18T) scanner was reported as normal. Her clinical presentation was suspicious enough that a repeat MRI on a high-field (1.5T) scanner was ordered. The second MRI included high resolution 3D volumetric imaging which revealed cartilage damage and loose bodies.*

Intervention and Outcome: *The patient was treated with arthroscopic surgery which confirmed the presence of meniscal and chondral injury and resulted in notable improvement in the patient's symptoms.*

Conclusion: *Clinicians should consider scanner quality and diagnostic accuracy before discounting*

Objectif : *Sensibiliser les cliniciens aux différences de résolution d'image et de précision potentielle du diagnostic entre les petits et grands imageurs par résonance magnétique (IRM). Présenter un exemple de difficulté de prise de décision clinique quant à la façon de procéder lorsque l'IRM du genou et les résultats cliniques se contredisent.*

Caractéristiques cliniques : *Une vététiste de 38 ans souffre d'une douleur au genou et les caractéristiques cliniques indiquent clairement une déchirure du ménisque ou la présence de corps étrangers. Une IRM initiale à l'aide d'un petit appareil (0,18 T) n'a rien révélé d'anormal. Son tableau clinique était assez suspect pour qu'un nouvel examen par IRM à l'aide d'un appareil de 1,5 T soit prescrit. Le deuxième appareil d'IRM comportait une imagerie volumétrique haute résolution en 3D qui a révélé des lésions du cartilage et des corps étrangers.*

Intervention et résultats : *Le patient a subi une chirurgie arthroscopique qui a confirmé la présence de lésions du ménisque et de lésions chondrales. Une amélioration notable des symptômes du patient a été enregistrée.*

Conclusion : *Les cliniciens devraient tenir compte de la qualité de l'imageur et de la précision du diagnostic avant d'écarter des antécédents cliniques fortement*

* Private practice, 305-4603 Kingsway, Burnaby, BC, V5H 4M4

** Private Practice, AIM Medical Imaging, 1371 W. Broadway, Vancouver, BC, V6H 1G9

Correspondence to: Dr. Glenn E. Cashman, 305-4603 Kingsway, Burnaby, BC, V5H 4M4. E-mail: gcashman@telus.net

©JCCA 2014

strongly suggestive clinical history and examination findings when MRIs are reported as normal.

(JCCA 2014; 58(4):395-400)

KEY WORDS: MRI, diagnosis, accuracy, knee, injury

Introduction

Diagnosis of knee cartilage injury begins with the history and physical examination but often relies on magnetic resonance imaging (MRI) to confirm clinical suspicions and inform the final decision as to whether patients require arthroscopic surgery. In cases where MRI results contradict clinical suspicions, it is not uncommon for clinicians to discard their initial clinical impression due to the general reputation of MRI for high accuracy. It has been our observation that the specifications of the MR scanner and thus the resultant image quality are sometimes overlooked when considering diagnostic accuracy of MRI for cartilage injury. The purpose of this paper is to present a case in which consideration of scanner quality did play a role in the clinical decision making pathway and, combined with history and physical exam, resulted in a favourable outcome for the patient.

Case Presentation

History

A thirty-eight year old female experienced sudden onset of left knee pain while downhill mountain biking as she was negotiating difficult terrain while standing in the pedals. She did not fall from her bike. She described the initial pain as a sudden severe ache which she felt in the posterior knee but did not recall feeling any associated pop or click at the time. The next day, she reported her pain was localized to the posterior knee and was associated with mild knee swelling. She was able to ambulate with a limp, was unable to fully extend her left knee and the pain was much worse when she attempted to twist or rotate on the injured leg while walking.

She was assessed by her family physician and physical therapist who suspected a torn meniscus. She was referred for magnetic resonance imaging (MRI) and a consultation

évocateurs et les résultats des examens « normaux » effectués par une IRM.

(JCCA 2014; 58(4):395-400)

MOTS CLÉS : IRM, diagnostic, précision, genou, blessure, chiropratique

with an orthopedic surgeon. Due to the prolonged waits for publicly funded MRI in British Columbia, the patient opted to pay privately to have her MRI taken. Due to the relatively low cost, she chose a private clinic which utilized a 0.18 tesla (T) low-field strength MR scanner. This MRI was reported as normal and specific comment was made regarding the normal appearance of the menisci, articular cartilage and the absence of loose osteochondral fragments. The patient was subsequently assessed by an orthopedic surgeon who indicated that, based on the lack of MRI findings; she was not a candidate for arthroscopic surgery. The surgeon also felt that the presence of patellar palpatory pain indicated she likely had chondromalacia patella. She was advised to continue with conservative treatment.

At eleven weeks post-injury she presented to the first author's clinic seeking options for conservative care. She continued to be frustrated by her pain which had become more generalized in the knee and was stiff and aching at night. She reported that her knee would occasionally lock in an extended position and would also catch or buckle which, on one occasion, had caused her to almost fall down the stairs. She continued to experience pain with bending or twisting on her affected leg.

Physical Examination

She was unwilling to squat past 50% due to pain and apprehension. Heel and toe walking was unremarkable. Passive knee flexion was limited by 15 degrees due to postero-lateral knee pain. Passive knee extension was full but caused deep lateral knee pain. Palpatory pain was present along the lateral and postero-lateral joint line and in the proximal lateral head of the gastrocnemius. She also had bilateral palpatory pain of the inferior poles of the patellae.

Orthopedic exam was notable for deep lateral and posterior knee pain with McMurray's test and Thessaly's test. Valgus knee stress produced lateral knee pain without any

valgus laxity. No pain or laxity was present with varus stress, Lachmann's, posterior drawer or patellar apprehension tests.

Management

Her history, symptoms and physical exam findings were highly suggestive of internal derangement of the knee such as a meniscal tear or osteochondral fragment. Strong clinical indicators and the knowledge that the MRI was performed on an older low-field MRI scanner raised concern that the resolution may have been insufficient to detect the injury in this case.

The MR images were sent for a second-opinion with a radiologist specializing in advanced imaging who agreed with the findings of the first report but also commented on the relatively poor image quality. The patient was counselled in this regard and the recommendation was made to obtain a new private MRI on a 1.5 T scanner. The second MRI revealed marked irregularity involving the under-surface of the posterior horn of the lateral meniscus with multiple loose bodies. Chondromalacia patella was also present.

She was referred to a second orthopedic surgeon who performed arthroscopic surgery 5 months post-injury. Arthroscopy revealed: 1) a grade 3 osteochondral defect in the medial femoral condyle measuring 1 cm x 1.25 cm. There was no evidence of full thickness cartilage loss, 2) lateral meniscal damage, 3) grade 3 chondromalacia patella, 4) loose debris. The medial condyle defect was stabilized at its edge and the loose debris removed.

Results

One month post-surgery she reported feeling an obvious absence of catching or giving-way in her knee. Rehabilitation was undertaken including range of motion exercises, stretching, strengthening and soft tissue therapy for the hip, thigh and knee. For several months she continued to have pain on stairs and with exercise which limited her participation in some sports. This may have been related to residual synovitis or cartilage damage in the patella, condyle and meniscus. On follow-up one year post-surgery she had returned to mountain biking and skiing but still experienced some discomfort with running.

Discussion

MRI has become second only to arthroscopy in diagnostic

accuracy for internal knee derangements such as meniscal damage. A systematic review by Crawford et al.¹ reported sensitivity and specificity as 91.4% and 81.1% respectively in diagnosing medial meniscal damage and 76% and 93.3% respectively in diagnosing lateral meniscal damage. Some authors^{2,3} have reported that low-field MR scanners have similar accuracy to their high-field counterparts in diagnosing meniscal tears while a systematic review by Oei et al.⁴, using receiver operating characteristic curves, demonstrated some superiority in accuracy of high-field versus low-field scanners for diagnosing knees. Sensitivity for diagnosing chondral lesions of the knee has been reported as being considerably lower (45%-69%).⁵⁻⁷ Most notably, defects affecting less than 50% of the hyaline cartilage thickness (grades 1-2) are particularly difficult to resolve even with high-field strength MR scanners.^{5,7} We would expect that for many conditions, diagnostic accuracy would be affected by the ability of an MR scanner to produce images with detailed resolution.

Physical examination is generally regarded to be lower in diagnostic accuracy compared to MR for torn menisci. In a meta-analysis by Hegedus et al.⁸, pooled sensitivity and specificity values were 70% and 71% for McMurray's, 60% and 70% for Apley's, and 63% and 77% for joint line tenderness. Reported accuracy was reduced in ACL deficient knees. Less research is available for Thessaly test but sensitivity and specificity have been reported as approximately 90% and 97% respectively by two studies.^{9,10} Thessaly test in ACL deficient knees is less accurate with sensitivity and specificity of 79% and 40%.¹¹ We are not aware of studies which assessed diagnostic accuracy of physical exam procedures for chondral injuries or loose bodies making the relative value of physical exam compared to MRI uncertain for these diagnoses.

Clinicians who refer for MRIs should be aware that variations in image resolution exist between various scanners. Magnet static field strength, gradients, coil elements and protocols all play a role in determining the ability of a particular scanner to provide sufficient detailed images and appropriate diagnostic information. Image resolution can be divided into spatial and contrast resolution. Contrast resolution is effectively determined by the types of sequences that are selected by the MRI facility. Most commonly T1, T2, and gradient based MEDIC sequences are employed. Often fat saturation (FS) is used to eliminate the bright signal from fat and to make edema appar-

ent. No standard sequences have been defined for joint imaging and thus the selection of prescribed sequences, slice thickness, and qualitative appeal of image quality is usually derived by the reading radiologist, or more commonly by the technologist operating the scanner. The critical interplay between slice thickness (spatial resolution), and sequence selection is always offset by scan time. MRI scans, even with high-field scanners, are rarely three-dimensional (3D) image acquisitions and thus the selected image planes for acquiring each sequence is pre-defined by radiologist preference, with guidelines provided by experts in the field, and publications. For example, in one radiology text¹², the lateral meniscal thickness is described as being 3 to 4 slices thick on sagittal plane images and image slice thickness is described to be 4-5 mm thick. Thus orthogonal plane images are required to ensure adequate representation of all the tissue in question.

Comparisons of the slice and gap thickness, spatial resolution and sequence times for each scanner are presented in Table 1. The slice thickness and resolution can

Table 1
*Comparison of Spatial Resolution
Between 0.18 T and 1.5 T MR Scanners*

High-Field Scanner (Siemens Espree 1.5T)				
Sequence	Slice Thickness (mm)	Slice Gap (mm)	Resolution (mm)	Acquisition Time
Axial T2 Gradient	3.5	0	0.6 x 0.5	4:20
Sagittal PD Fat-Sat	3	0	0.6 x 0.5	4:24
Coronal T2 Fat-Sat	3	0	0.6 x 0.5	4:04
Coronal T2 Gradient	3	0	0.6 x 0.5	4:03
Sagittal T1	3	0	0.5 x 0.4	4:06
Axial 3D Hi-Res	0.6	0	0.6 x 0.5	4:11
Low-Field Scanner (ESAOTE Artoscan-C 0.18T)				
Sequence	Slice Thickness (mm)	Slice Gap (mm)	Resolution (mm)	Acquisition Time
Sagittal T1 Hi-Res	3	0.4	0.90 x 0.56	~7:51
Sagittal T2	3.5	0.9	0.83 x 0.80	~6:66
Coronal T2	4	0.4	0.83 x 0.83	~6:12
Coronal Fat-Sat	5	0.5	1.08 x 0.89	~7:07
Axial T2	4.5	0.9	0.78 x 0.78	unknown

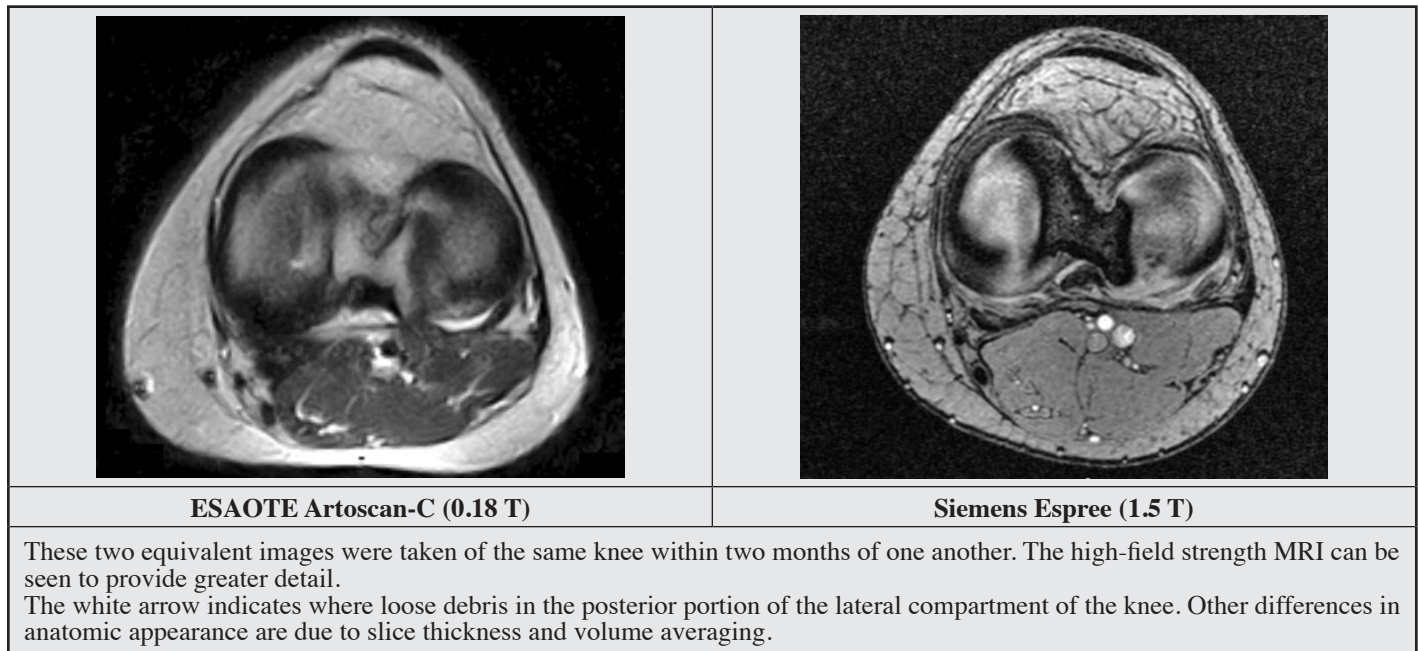
be seen to provide more images and detail on the higher field magnet. Resolution values are given in two dimensions but when multiplied by slice thickness they provide a pixel volume referred to as a voxel. Smaller voxels translate to more detailed resolution of the MRI. The highest detail created by the high-field scanner used in this case study was produced in the axial 3D high resolution sequence resulting in a voxel size of 0.18 mm³. The resolution provided by this sequence was 8.4 times more detailed than the best resolution provided by the low-field magnet. The images of the low-field magnet have thicker slices which volume average together – giving more blur, coupled with gaps without any imaging, which can lead to important information being missed. Figure 1 visually compares two similar axial slices of the same knee taken from each scanner, the high-field image showing the loose debris missed by the low-field image. Scan times for the high-field scanner are also shorter for each sequence which is important because motion at any point during the image acquisition will result in the entire sequence being discarded. In this case presentation, the patient's initial normal reported study was performed on a low-field magnet, which took approximately 45 minutes to complete including non-imaging scanner preparation time while the repeat study took 25 minutes to complete.

As stated above, not all high-field scanners utilize 3D high resolution volumetric imaging. This technology allows equal image detail in every axis and was not available from manufacturers until approximately 2008. Among the scanners manufactured with this capability, not all imaging centres implement the 3D high-resolution protocols. Therefore, knowledge of scanners' capacity for high resolution 3D volumetric imaging may also aid clinicians in their decision making, particularly with regards to chondral injuries for which the reported diagnostic accuracy of MRI is known to be lower.

Conclusion

We have presented a case in which meniscal damage and loose bodies in the knee were not detected on a low-field (0.18 T) MR scanner but were revealed by a higher field (1.5 T) magnet with superior contrast and spatial image resolution. The initial low-field MRI study which was reported as normal due to the lack of resolution led to discounting the patient's symptoms by an orthopedic surgeon and prolonged patient suffering.

Figure 1
Comparison of image resolution between 0.18 T and 1.5 T MRI.



We hope this case will raise clinicians' awareness of variability in scanner resolution when making referrals for MRI and when considering diagnostic accuracy of an MRI. Consideration should be given to scanner quality before discounting strongly suggestive clinical history and examination findings when MRIs are reported as normal.

References

1. Crawford R, Walley G, Bridgman S, Maffulli N. Magnetic resonance imaging versus arthroscopy in the diagnosis of knee pathology, concentrating on meniscal lesions and ACL tears: A systematic review. *Br Med Bull.* 2007;84:5-23.
2. Cotten A, Delfaut E, Demondion X, et al. MR imaging of the knee at 0.2 and 1.5 T: Correlation with surgery. *AJR. Am J Roentgenology.* 2000;174(4):1093-1097.
3. Riel KA, Reinisch M, Kersting-Sommerhoff B, Hof N, Merl T. 0.2-tesla magnetic resonance imaging of internal lesions of the knee joint: A prospective arthroscopically controlled clinical study. *Knee Surgery, Sports Traumatology, Arthroscopy.* 1999;7(1):37-41.
4. Oei EH, Nikken JJ, Verstijnen AC, Ginai AZ, Myriam Hunink MG. MR imaging of the menisci and cruciate ligaments: A systematic review. *Radiology.* 2003;226(3):837-848.
5. Challen J, Tang Y, Hazratwala K, Stuckey S. Accuracy of MRI diagnosis of internal derangement of the knee in a non-specialized tertiary level referral teaching hospital. *Australas Radiol.* 2007;51(5):426-431.
6. Figueroa D, Calvo R, Vaisman A, Carrasco MA, Moraga C, Delgado I. Knee chondral lesions: Incidence and correlation between arthroscopic and magnetic resonance findings. *Arthroscopy.* 2007;23(3):312-315.
7. Sonin AH, Pensy RA, Mulligan ME, Hatem S. Grading articular cartilage of the knee using fast spin-echo proton density-weighted MR imaging without fat suppression. *AJR. Am J Roentgenology.* 2002;179(5):1159-1166.
8. Hegedus EJ, Cook C, Hasselblad V, Goode A, McCrory DC. Physical examination tests for assessing a torn meniscus in the knee: A systematic review with meta-analysis. *J Orthopaedic & Sports Phys Ther.* 2007;37(9):541-550.
9. Karachalios T, Hantes M, Zibis AH, Zachos V, Karantanas AH, Malizos KN. Diagnostic accuracy of a new clinical test (the thessaly test) for early detection of meniscal tears. *J Bone & Jt Surg – American Volume.* 2005;87(5):955-962.
10. Harrison BK, Abell BE, Gibson TW. The thessaly test for

- detection of meniscal tears: Validation of a new physical examination technique for primary care medicine. *Clin J Sport Med.* 2009;19(1):9-12.
11. Mirzatolooei F, Yekta Z, Bayazidchi M, Ershadi S, Afshar A. Validation of the thessaly test for detecting meniscal tears in anterior cruciate deficient knees. *Knee.* 2010;17(3):221-223.
12. Brant WE, Helms CA. *Fundamentals of diagnostic radiology.* 4th ed. Philadelphia, PA: Lippincott Williams and Wilkins; 2012.