

Conservative treatment of a rock climber with a SLAP lesion: a case report

Marc-André Blanchette, DC, MSc¹

Ai-Thu Pham, DC²

Julie-Marthe Grenier, DC, DACBR/FCCR(C)³

This case report describes the clinical presentation and conservative treatment of a patient who suffered from a superior labrum anteroposterior (SLAP) tear of the shoulder after a rock climbing session. The 26 year old man had injured his right shoulder while trying to reach a distant socket with his shoulder 90° abducted and in extreme external rotation. After initial treatment failure in chiropractic, the patient sought an orthopaedist and physiotherapy care. A contrast magnetic resonance examination revealed a SLAP lesion. Awaiting orthopaedic consultation and in the absence of clinical improvement the patient sought care from a second chiropractor. Clinical examination revealed a mild winging of the right scapula and the presence of trigger points in the rotator cuff muscles, biceps, rhomboids and serratus anterior. The chiropractic treatment then included soft tissue mobilization and the prescription of strengthening exercises of the serratus anterior and rotator cuff muscles. After 4 sessions, the patient

L'objectif de ce rapport de cas est de décrire la présentation clinique et le processus thérapeutique d'un patient ayant subi une déchirure de la partie supéro-antérieure du labrum (SLAP) de l'épaule droite suite à une séance d'escalade. L'homme de 26 ans s'est infligé cette blessure à l'épaule droite en tentant d'atteindre une prise éloignée en maintenant son épaule en position abduction à 90° avec rotation externe extrême. Après un premier échec thérapeutique en chiropratique, le patient a consulté un orthopédiste et un physiothérapeute. Un examen par résonance magnétique avec contraste a révélé une lésion de type SLAP du labrum. Dans l'attente d'une consultation orthopédique et en l'absence de progrès clinique le patient a de nouveau consulté en chiropratique. L'examen a révélé un léger décollement scapulaire droite et des points gâchettes dans les muscles de la coiffe des rotateurs ainsi que dans les muscles biceps, rhomboïdes et dentelé antérieur. Le patient a été traité au moyen de mobilisations des tissus mous et des exercices de renforcements du dentelé antérieur et de la coiffe des rotateurs ont été prescrit. Après 4 séances, le patient ne ressentait plus aucune

¹ Public Health PhD Program, School of Public Health, University of Montreal, Montreal, QC, Canada

² Private practice, Momentum Chiropratique, Vaudreuil-Dorion, QC, Canada

³ Associate Professor, Department of Chiropractic, Université du Québec à Trois-Rivières, Trois-Rivières, QC, Canada

Corresponding author: Marc-André Blanchette

marc-andre.blanchette@umontreal.ca

Public Health PhD Program, School of Public Health, University of Montreal, Montreal, QC, Canada

Disclosures: Dr. Marc-André Blanchette receives a PhD fellowship award from the CIHR. Dr. Julie-Marthe Grenier and Dr. Ai-Thu Pham declare no competing interests.

© JCCA 2015

did not feel any pain and gradually resumed all his recreational activities. Clinicians should be aware that SLAP lesions are difficult to identify clinically and that manual therapy might be an important component of conservative treatment of SLAP lesions.

(JCCA 2015; 59(3):238-244)

KEY WORDS: shoulder, chiropractic, SLAP, labrum tear, sports injuries, diagnostic imaging, radiology, rock climbing, conservative care

Introduction

The term SLAP (superior labrum anteroposterior) tear was originally introduced by Snyder et al. in 1990¹ but Andrews was the first to report this type of lesion in 1985². SLAP lesions refer to a tear of the superior labrum (11-to-1 o'clock position), typically at the origin of the long head of the biceps tendon and might extend into the labrum anteriorly or posteriorly and into the adjacent structures.³⁻⁵ The prevalence of SLAP lesions in people seeking orthopaedic care with shoulder pain varies between 6% and 11.8%.^{6,7} Although it is difficult to assess the incidence in the population of this type of injury, the incidence of associated number of surgeries was 22.3 / 100,000 inhabitants in the state of New York in 2010.⁸ This represents an increase of 464% compared to the year 2002.⁸ In the military, the incidence of surgery rates can reach 2.13 cases per 1,000 person-years.⁹ Male gender, age and being in the Marine Corps were all significant risk factors.⁹ SLAP lesions are also frequently reported in young athletes with 'throw' movements sports (baseball, tennis, swimming, etc.).^{10,11} The natural evolution of SLAP lesions and the effectiveness of conservative treatment is unknown since it has only been investigated in the context of a case series.¹² However, the results look promising with a significant decrease in pain, improved quality of life and rates of return to play similar to surgical patients.¹² Nevertheless, half of the patients who start conservative treatment ultimately choose surgery.¹² The latter option seems to produce good results in the general population, but the return to play of athletes (especially baseball) is unpredictable.¹³ Treatment modalities used during the conservative care

douleur et effectuait un retour à ses activités récréatives. Les cliniciens doivent être conscients que les lésions de type SLAP sont difficiles à identifier cliniquement et que les thérapies manuelles semblent être un élément important du traitement conservateur des lésions de type SLAP.

(JCCA 2015; 59(3):238-244)

MOTS CLÉS: épaule, chiropratique, slap, déchirure labrum, blessures sportives, imagerie diagnostique, radiologie, escalade, traitement conservateur

of SLAP lesions are poorly documented. This case report presents in detail the treatments used for a young recreational climber suffering from a SLAP lesion.

Case presentation

A 26 year-old recreational rock climber developed a dull pain in the right shoulder during a bouldering session (difficulty V2-V3). The patient reported that he felt a popping sensation when he tried to reach a distant socket with his shoulder abducted 90° and in extreme external rotation (ABER position). The patient initially sought chiropractic care at a rate of 1 to 2 treatments per week over a two month period. Although we did not have access to that clinical record, the patient reported that the treatments consisted of transverse friction at the insertion of the rotator cuff tendon; spinal manipulative therapy of the thoracic spine; and prescription of stretching exercise of the pectoralis minor. Since his condition did not improve, the patient then consulted an orthopaedic surgeon and received a prescription for a magnetic resonance arthrography (MRA) examination as well as a reference for physiotherapy. The patient visited the physical therapist only once. During this visit, his shoulder was taped and he received a prescription for stretching exercises of the pectoralis minor and major, as well as strengthening exercises of the internal and external rotators using an elastic band.

Not feeling any improvement after performing the exercises for two weeks, the patient obtained an appointment for the MRA examination in a private clinic. The MRA examination revealed an isolated posterosuperior

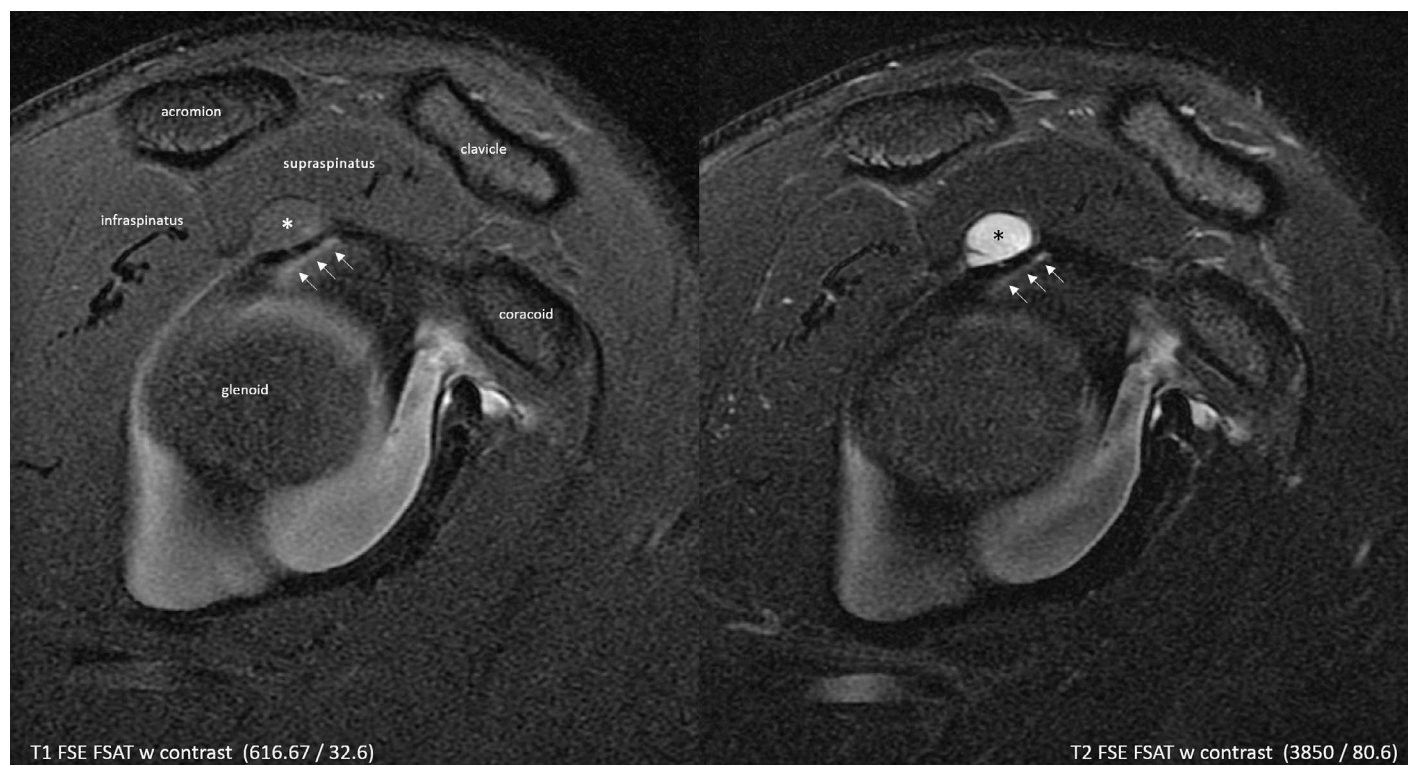

Figure 1.

MRA sagittal images demonstrating a paralabral cyst () and a tear (arrows) in the superior-posterior aspect of the glenoid labrum. The tear can be seen as a linear region of high signal intensity region. When one imagines the glenoid surface as a clock, the tear occupies the region between 10 to 12 o'clock. The cyst measured approximately 1 cm in diameter and is slightly septated, as seen on the T2 FS image. The different signal intensity between the T1 FS and T2 fat saturated images indicates that the cyst (*) does not fill with contrast.*

glenoid labral tear associated with a paralabral cyst without injury to the tendon of the long head of the biceps. All other structures including the rotator cuff tendons and bursae appeared normal (Figure 1 and 2).

Consequently, the patient consulted an orthopaedic surgeon to evaluate surgical options. Awaiting the preoperative consultation, the patient decided to consult another chiropractor for a second opinion 5 months after his initial injury because the pain was still intense (5/10) during exercise. During this clinical examination all the orthopedic tests of the shoulder (Neer, Jobe, Sulcus sign, Hawkins, Speed, Apprehension manoeuvre) were inconclusive and the ranges of motion (active, passive and resisted) were normal. Trigger point pains were identified in the follow-

ing muscles: supraspinatus, subscapularis, infraspinatus, teres minor, biceps (long head), rhomboids and serratus anterior. In addition, postural analysis showed a slight winging of the right scapula. Conservative care consisted of soft tissue mobilization of muscles, tendons, ligaments and joint capsule using Active Release Techniques® and Graston Technique®. Strengthening exercises of the external shoulder rotator (with an elastic band) and the serratus anterior (scapular “push-up”) were also prescribed. After four treatments, the patient cancelled his appointment with the orthopaedic surgeon because he was pain free. He then gradually returned to his sport, performing today at a more advanced level than before (bouldering V4-V5).

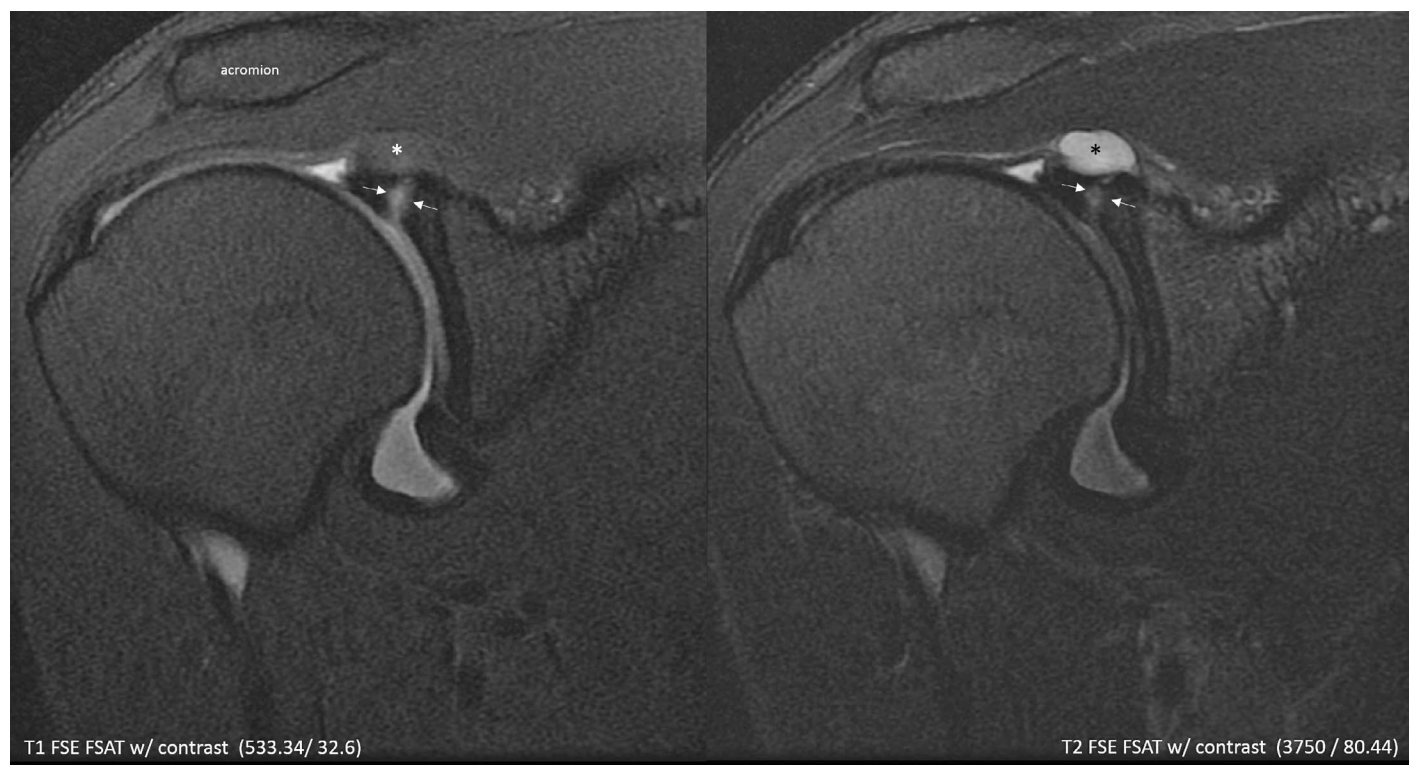


Figure 2.

MRA coronal (oblique) images demonstrating a paralabral cyst () and a tear (arrows) in the glenoid labrum. The tear can be seen as a linear region of high signal intensity (contrast-filled) region on both images, as the gadolinium-based contrast media mixed with articular fluid demonstrates a high signal intensity on both sequences. The cyst (*) does not fill with contrast.*

Discussion

This case report is a good example of positive outcomes following the conservative treatment of a SLAP lesion. Having tried several conservative approaches, it is likely that using manual therapies (Active Release®, Graston Technique®) was a key component of the treatment of this patient, along with the inclusion of scapular stabilization exercises. The diagnosis of SLAP requires a high level of clinical suspicion to wisely prescribe imaging. There is little literature on the natural history of this condition and the effectiveness of conservative care. We will now discuss the anatomy, clinical presentation, imaging and treatment of SLAP lesions.

Anatomy

The labrum is a ring of fibrocartilage based on the glenoid cavity. It increases the shoulder's depth, stability and shock absorption capacity.⁴ The labrum is also a site of attachment of the joint capsule, the glenohumeral ligaments, and the long head of the biceps tendon.⁴ Approximately 50% of the biceps tendon fibers attach to the superior labrum and the other 50% on the supra-glenoid tubercle.¹⁴ The superior and anterior region of the labrum has the poorest blood supply, and it is hypothesized that contributes to a slower healing process.¹⁴ The 11-to-3-o'clock position is a common site of anatomic variants of the labrum and glenohumeral ligament (sublabral recess, sublabral foramen, Buford complex and mobile glenoid

labrum).⁴ These normal variants are associated with a higher incidence of SLAP lesions.¹⁵⁻¹⁷ Ten distinct types of SLAP lesion, based on the extent of the labral tear and involvement adjacent structures, have been reported in the literature. Type II SLAP lesion (superior labral tear and biceps tendon stripping) is the most common type. 90% of type II SLAP lesions have associated shoulders abnormalities like: rotator cuff tendinosis and/or tear, acromioclavicular and/or glenohumeral arthritis, adhesive capsulitis.¹⁸

Clinical Presentation

It is difficult to clinically diagnose SLAP lesions, because it does not have a specific presentation and associated conditions are frequent. During the initial interview, the patient may report non-specific anterior shoulder pain aggravated by overhead activity.³ Clicking, popping, stiffness and glenohumeral instability might also be present.^{3,19} Clinicians should also investigate the plausibility of the following potential mechanisms of injury³:

- sudden traction on the arm and forceful contraction of the biceps muscle which can peel back the labrum from the glenoid²⁰ during activity that involves overhead motion with the arm in the abducted and externally rotated (ABER) position (ex: baseball, tennis, swimming);
- the superior migration of the humeral head resulting from a rotator cuff tear, might also cause a lifting of the superior labrum and biceps tendon from the glenoid;²¹
- a fall on an outstretched hand (FOOSH) or a direct blow to the shoulder;
- an internal impingement syndrome that results from the impingement of the soft tissues of the rotator cuff and joint capsule on the glenoid or between the glenoid and the humerus.²²

The physical examination should begin by a careful evaluation of the glenohumeral and scapulothoracic ranges of motion.^{5,10} The glenohumeral ranges of motion are better assessed in the supine position with the shoulder positioned at 90° of abduction and the elbow in flexion. This position stabilises the scapula and it is easier to detect side-to-side difference in internal and external gleno-

humeral rotation. SLAP lesions could be associated with an increase of external rotation and a decrease of internal rotation, particularly in the throwing athlete.¹⁰ This glenohumeral internal rotation deficit (GIRD), is characterized by a decrease of 20° when compared with the opposite side.²³ The evaluation of scapular kinematics is also an important component of the physical examination. Alteration of the scapular position or motion might produce greater stress to the glenohumeral joint^{10,24} as in the present case report. Clinicians should also keep in mind that atrophy of the periscapular muscles might be secondary to a cervical pathology.^{5,10} Despite the initial enthusiasm regarding particular orthopaedic shoulder tests (Biceps load II test and Active-Compression test (O'Brien's test)), a recent meta-analysis demonstrated that none of the studied tests had sufficient psychometric propriety (sensitivity, specificity, positive and negative predictive value) to provide the clinician with useful information.²⁵ Test combinations represent a promising area of research, but none of the studied combinations were actually satisfactory.²⁵

Imaging

Given the limitations of the clinical evaluation, imaging remains the key to diagnosing SLAP lesions. Plain radiographs of the shoulder are typically normal unless there are associated co-existing conditions such as glenohumeral subluxation, acromioclavicular deformation and/or outlet impingement.^{5,10} Bankart lesions (anterior inferior fracture of the glenoid) and Hills-Sachs defect (posterior superior fracture of the humeral head) might also be signs of previous shoulder trauma and potential instability.¹⁰ MRA is an examination where intra-articular Gadolinium is administered with a 18- to 25- Gauge needle into the shoulder joint under fluoroscopic or ultrasound guidance followed by magnetic resonance imaging (MRI). It is more sensitive than non-arthrographic MRI and ultrasound scans as Gadolinium distends the joint space allowing for improved visualization of the labral and joint capsular structures.^{26,27} Unfortunately, false positives are frequent when compared to arthroscopy.²⁷ Since computed tomography arthrography demonstrated similar psychometric properties to MRA, it might be used in the context of limited access to MRA.²⁸ Clinicians might consider prescribing advanced imaging after failure of a course of conservative care if the mechanism of injury is consistent with a SLAP lesion.

Treatment

The evidence regarding the conservative treatment of SLAP lesions is very limited and the treatment recommendations are based on a case series and expert opinions.^{5,10,12} Treatment recommendations include: rest from painful activities, nonsteroidal anti-inflammatory drugs and rehabilitation.^{5,10,12} Rehabilitation care is oriented towards stabilizing muscles of the shoulder and shoulder girdle in order to regain normal muscle strength, neuromuscular activation and adequate proprioception.^{10,12} In the presence of a GIRD, stretching exercises of the posterior capsule might also be prescribed.¹⁰ The present case report suggests that manual therapy (Active Release®, Graston Technique®) might also play an important role in the treatment of SLAP lesions. In the case series reported by Edwards, 49% of patients treated conservatively avoided the surgery.¹² Conservative care significantly improved pain, function and quality of life of patients in 49% of cases.¹² The return to play rate at the pre-injury level of activity was 71% (66% in the overhead athletes).¹² The rate of return to play of conservative care was also comparable to surgical treatment.¹² Edwards recommended that patients should be referred for surgical interventions if significant pain and functional limitations were still present after 3 months of conservative care.¹² Orthopaedic surgeons will consider: the type of SLAP lesions (ie: the extent of the labral tear and the involvement of adjacent structures), the age, and the level of functionality of the patient before recommending surgical options.^{5,10,13,29} Since surgical procedures vary widely (debridement, repair, fixation, partial or total resection of the tendon, etc.), it is difficult to assess the prognosis of SLAP lesion repairs.^{5,13} A recent systematic review concluded that type II SLAP repairs produced excellent results for patients not involved in overhead throwing sports.¹³ Baseball players had less predictable results with return to sport rates (at a similar level) ranging from 22% to 64%.¹³

Conclusion

This case report demonstrates that it is difficult to diagnose SLAP lesions without high clinical suspicion. It also illustrated that conservative treatment might provide an optimal recovery with a return to sport activities at the previous level (or higher). Manual therapies seemed to play an important role in the treatment of this patient. Future research should help to better understand the natural

history of SLAP lesions and identify effective modalities of conservative care.

Acknowledgement

The authors would like to thank Dr. Mathieu Paquin for the linguistic revision of the manuscript.

References

1. Snyder SJ, Karzel RP, Del Pizzo W, Ferkel RD, Friedman MJ. SLAP lesions of the shoulder. *Arthroscop*. 1990;6(4):274-279.
2. Andrews JR, Carson WG, Jr., McLeod WD. Glenoid labrum tears related to the long head of the biceps. *Am J Sports Med*. 1985;13(5):337-341.
3. Modarresi S, Motamedi D, Jude CM. Superior labral anteroposterior lesions of the shoulder: part 2, mechanisms and classification. *Am J Roentgen*. 2011;197(3):604-611.
4. Modarresi S, Motamedi D, Jude CM. Superior labral anteroposterior lesions of the shoulder: part 1, anatomy and anatomic variants. *Am J Roentgen*. 2011;197(3):596-603.
5. Aydin N, Sirin E, Arya A. Superior labrum anterior to posterior lesions of the shoulder: Diagnosis and arthroscopic management. *World J Orthoped*. 2014;5(3):344-350.
6. Handelberg F, Willems S, Shahabpour M, Huskin JP, Kuta J. SLAP lesions: a retrospective multicenter study. *Arthroscop*. 1998;14(8):856-862.
7. Maffet MW, Gartsman GM, Moseley B. Superior labrum-biceps tendon complex lesions of the shoulder. *Am J Sports Med*. 1995;23(1):93-98.
8. Onyekwelu I, Khatib O, Zuckerman JD, Rokito AS, Kwon YW. The rising incidence of arthroscopic superior labrum anterior and posterior (SLAP) repairs. *J Shoulder Elbow Surg*. 2012;21(6):728-731.
9. Waterman BR, Cameron KL, Hsiao M, Langston JR, Clark NJ, Owens BD. Trends in the diagnosis of SLAP lesions in the US military. *Knee Surg Sports Traum Arthroscop*. 2015;23(5):1453-1459.
10. Knesek M, Skendzel JG, Dines JS, Altchek DW, Allen AA, Bedi A. Diagnosis and management of superior labral anterior posterior tears in throwing athletes. *Am J Sports Med*. 2013;41(2):444-460.
11. Sayde WM, Cohen SB, Ciccotti MG, Dodson CC. Return to play after Type II superior labral anterior-posterior lesion repairs in athletes: a systematic review. *Clin Orthop Rel Research*. 2012;470(6):1595-1600.
12. Edwards SL, Lee JA, Bell JE, et al. Nonoperative treatment of superior labrum anterior posterior tears: improvements in pain, function, and quality of life. *Am J Sports Med*. 2010;38(7):1456-1461.
13. Gorantla K, Gill C, Wright RW. The outcome of type II SLAP repair: a systematic review. *Arthroscop*. 2010;26(4):537-545.

14. Vangsness CT, Jr., Jorgenson SS, Watson T, Johnson DL. The origin of the long head of the biceps from the scapula and glenoid labrum. An anatomical study of 100 shoulders. *J Bone Joint Surg (UK)*. 1994;76(6):951-954.
15. Bents RT, Skeete KD. The correlation of the Buford complex and SLAP lesions. *J Shoulder Elbow Surg*. 2005;14(6):565-569.
16. Ilahi OA, Cosculluela PE, Ho DM. Classification of anterosuperior glenoid labrum variants and their association with shoulder pathology. *Orthoped*. 2008;31(3):226.
17. Rao AG, Kim TK, Chronopoulos E, McFarland EG. Anatomical variants in the anterosuperior aspect of the glenoid labrum: a statistical analysis of seventy-three cases. *J Bone Joint Surg (US)*. 2003;85-a(4):653-659.
18. Jin W, Ryu KN, Kwon SH, Rhee YG, Yang DM. MR arthrography in the differential diagnosis of type II superior labral anteroposterior lesion and sublabral recess. *Am J Roentgen*. 2006;187(4):887-893.
19. Meserve BB, Cleland JA, Boucher TR. A meta-analysis examining clinical test utility for assessing superior labral anterior posterior lesions. *Am J Sports Med*. 2009;37(11):2252-2258.
20. Burkhart SS, Morgan CD. The peel-back mechanism: its role in producing and extending posterior type II SLAP lesions and its effect on SLAP repair rehabilitation. *Arthroscop*. 1998;14(6):637-640.
21. Lin E. Magnetic resonance arthrography of superior labrum anterior-posterior lesions: a practical approach to interpretation. *Curr Prob Diag Radiol*. 2009;38(2):91-97.
22. Grainger AJ. Internal impingement syndromes of the shoulder. *Sem Musculoskel Radiol*. 2008;12(2):127-135.
23. Burkhart SS, Morgan CD, Kibler WB. The disabled throwing shoulder: spectrum of pathology Part I: pathoanatomy and biomechanics. *Arthroscop*. 2003;19(4):404-420.
24. Fleisig GS, Andrews JR, Dillman CJ, Escamilla RF. Kinetics of baseball pitching with implications about injury mechanisms. *Am J Sports Med*. 1995;23(2):233-239.
25. Hegedus EJ, Goode AP, Cook CE, et al. Which physical examination tests provide clinicians with the most value when examining the shoulder? Update of a systematic review with meta-analysis of individual tests. *Brit J Sports Med*. 2012;46(14):964-978.
26. Pavic R, Margetic P, Bensic M, Brnadac RL. Diagnostic value of US, MR and MR arthrography in shoulder instability. *Injury*. 2013;44 Suppl 3:S26-32.
27. Sheridan K, Kreulen C, Kim S, Mak W, Lewis K, Marder R. Accuracy of magnetic resonance imaging to diagnose superior labrum anterior-posterior tears. *Knee Surg Sports Traumatol Arthroscop*. 2014.
28. Oh JH, Kim JY, Choi JA, Kim WS. Effectiveness of multidetector computed tomography arthrography for the diagnosis of shoulder pathology: comparison with magnetic resonance imaging with arthroscopic correlation. *J Shoulder Elbow Surg*. 2010;19(1):14-20.
29. McCormick F, Bhatia S, Chalmers P, Gupta A, Verma N, Romeo AA. The management of type II superior labral anterior to posterior injuries. *Orthoped Clin North Am*. 2014;45(1):121-128.