ISSN 0008-3194 (p)/ISSN 1715-6181 (e)/2016/182–189/$2.00/©JCCA 2016

High incidence of persistence of sacral and coccygeal intervertebral discs in South Indians – a cadaveric study

Satheesha Nayak B, MSc, PhD[1]
Ashwini Aithal P, MSc[1]
Naveen Kumar, MSc, PhD[1]
Bincy M George, MSc, PhD[1]
Deepthinath R, MSc, PhD[1]
Surekha D Shetty, MSc[1]

The sacrum, by virtue of its anatomic location plays a key role in providing stability and strength to the pelvis. Presence of intervertebral discs in sacrum and coccyx is rare. Knowledge of its variations is of utmost importance to surgeons and radiologists. The current study focused on the presence of intervertebral discs between the sacral and coccygeal vertebrae in south Indian cadaveric pelvises. We observed 56 adult pelvises of which, 34 (61%) pelvises showed the presence of intervertebral discs between the sacral vertebrae and between the coccygeal vertebrae, while 22 (39%) pelvises did not have the intervertebral discs either in the sacrum or the coccyx. We also found that most of the specimens had discs between S1 and S2 vertebrae (39%), followed by, between S4 and S5 (18%), between S2-S3 (14%) and least being between S3-S4 (13%). In the coccyx it was found that 7% of pelvises had disc between Co1-Co2, 4% of them had between Co2-Co3

Le sacrum, en raison de son emplacement anatomique, joue un rôle essentiel pour assurer la stabilité et la force du bassin. La présence de disques intervertébraux dans le sacrum et le coccyx est rare. La connaissance de ses variations est d'une importance capitale pour les chirurgiens et les radiologues. L'étude actuelle a porté sur la présence de disques intervertébraux entre les vertèbres sacrées et coccygiennes sur des bassins cadavériques dans le sud de l'Inde. Nous avons observé 56 bassins adultes, dont 34 (61 %) ont montré la présence de disques intervertébraux entre les vertèbres sacrées et coccygiennes, tandis que 22 (39 %) autres n'avaient pas des disques intervertébraux, dans le sacrum ou le coccyx. Nous avons également constaté que la plupart des spécimens avaient un disque entre les vertèbres S1 et S2 (39 %), 18 % avaient un disque entre les vertèbres S4 et S5, et enfin 14 % entre S3 et S4. Dans le coccyx, on a constaté que 7 % des bassins avaient un disque entre Co1 et Co2, 4 % d'entre eux l'avaient entre

[1] Department of Anatomy, Melaka Manipal Medical College (Manipal Campus), Manipal University, Manipal, Karnataka state, India 576104.

Corresponding author:
Ashwini Aithal P
Department of Anatomy, Melaka Manipal Medical College (Manipal Campus), Manipal University, Manipal. Karnataka, INDIA 576104
E-mail: ashwini.anat@gmail.com
Fax: 0820-2571201
Tel: +91 9738935728

and 4% had between Co3-Co4. Knowledge regarding such anatomic variations in the sacro-coccygeal region is important to note because they require alterations in various instrumentation procedures involving the sacrum.

(JCCA. 2016;60(2):182-189)

KEY WORDS: sacrum, intervertebral disc, coccyx, mobility of sacrum, sacral screw, sacral lesion.

Co2 et Co3 et 4 % entre Co3 et Co4. Il est important de noter la connaissance de ces variations anatomiques de la région sacro-coccygienne en raison des modifications nécessaires à apporter aux diverses procédures d'instrumentation impliquant le sacrum.

(JCCA. 2016;60(2):182-189)

MOTS CLÉS : sacrum, disque intervertébral, coccyx, mobilité du sacrum, vis sacrée, lésion sacrée.

Introduction

The sacrum is a large, triangular bone formed by the fusion of five sacral vertebrae. It forms the posterosuperior wall of pelvic cavity. Its apex articulates with the coccyx and its base articulates with the fifth lumbar vertebra at the lumbo-sacral angle. Between the base and apex are dorsal, pelvic and lateral surfaces and a sacral canal.[1] The coccyx is a small triangular bone. It usually consists of 3-5 fused rudimentary coccygeal vertebrae. The base of the first coccygeal vertebra articulates with the sacral apex. The second to fourth coccygeal vertebrae diminish in size and are usually mere fused nodules and represent rudimentary vertebral bodies.[1] Sacrum contributes significantly for the stability and strength of the pelvis by transmitting the weight of the body to the pelvic girdle. The five sacral vertebrae are connected by intervertebral discs during childhood with subsequent fusion of the S4–S5 and S3–S4 levels in late adolescence and fusion of the S2–S3 and S1–S2 levels by the third decade of life. This fusion process is partially dependent on human upright posture and locomotion. It is not infrequent to observe a residual disc at S1–S2 levels on imaging studies, especially in young adults. When this disc space is prominent, care must be exercised so as not to incorrectly count intervertebral disc space levels.[2] Variant anatomy may lead to misinterpretation of a radiograph or computed tomography (CT) scan. Lumbosacral fusion and instrumentation are common procedures for several spinal disorders including spondylolisthesis, lumbar scoliosis and for metastatic, infectious, degenerative and traumatic diseases affecting the sacrum.[3-5]

Dysmorphic sacra have distinct anatomic variations that must be noted prior to surgical intervention. Dysmorphic osseous characteristics include colinearity of the upper portion of the sacrum and the iliac crests, noncircular anterior sacral foramina, residual upper sacral discs, etc. Many surgeons believe that these variations are important to note because they require alterations in surgical fixation constructs in the sacrum, which will avoid any iatrogenic nerve injury.[6] They opine that sacral dysmorphism has been identified in almost half of the adult population using CT scans and that these variants complicate the interpretation of sacral anatomy and thus hinder many surgical and radiological interventions.

Thus, understanding the morphological variations of sacrum and coccyx is imperative. Persistence of intervertebral discs between the sacral and coccygeal vertebrae is a very rare finding. To the best of our knowledge, to date there is no study conducted on human cadavers which focuses on this idea and the importance related to it. Thus the current study was undertaken which focused on the presence of intervertebral discs between the sacral and coccygeal vertebrae in South Indian cadaveric pelvises.

Materials and Methods

During our regular dissection classes for medical undergraduates, we noticed a high incidence of persistent intervertebral discs between the sacral and coccygeal vertebrae. We decided to conduct a systematic study and document the percentage occurrence of intervertebral discs between sacral and coccygeal vertebrae. We had in our collection, 112 pelvic halves which were obtained by making midline saw cuts through 56 adult human south Indian cadaveric pelvises. The age of the formalin embalmed bodies ranged between 45 and 80 years. They were grouped into male and female pelvises. Incomplete or irregular pelvic halves were excluded from the study. The following par-

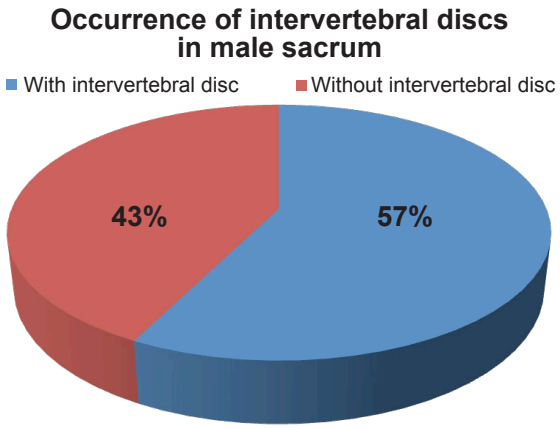

Figure 1.
Graph showing the presence of intervertebral discs in male sacrum.

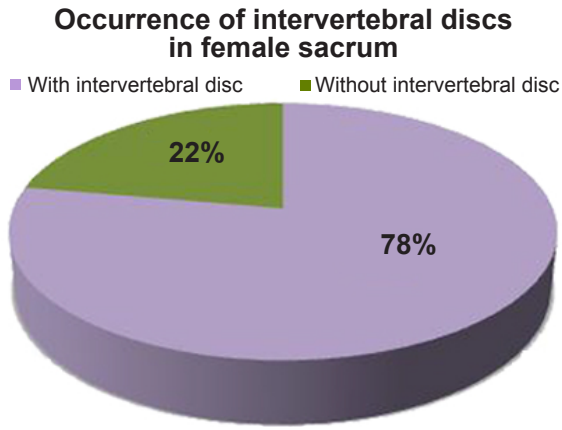

Figure 2.
Graph showing the presence of intervertebral discs in female sacrum.

ameters were noted: presence or absence of intervertebral discs in the sacrum and coccyx; vertebral levels at which the discs were present; maximum and minimum vertical thickness of the intervertebral disc. Results were expressed as percentages.

Results

Among the 56 pelvises that we observed, 47 were male and 9 were female pelvises. 34 (61%) of the pelvises showed the presence of intervertebral discs between the sacral vertebrae and between the coccygeal vertebrae while 22 (39%) pelvises did not have the intervertebral discs either in the sacrum or the coccyx. Among the pelvises with presence of at least one disc, 27(79%) were male pelvises while 7 (21%) were female pelvises. When we compared females with males for the presence of discs in sacrum, 78% of females had at least one disc in the sacrum while 57% of males had at least one disc in the sacrum (Figures 1 and 2). 15% of males had at least one disc in the coccyx, whereas none of females had any disc in the coccyx.

In most of the male pelvises, the intervertebral discs were found in sacrum and coccyx, while in female pelvises, the intervertebral discs were present only in the sacrum. In the sacrum, only 1 disc was present in 27 pelvises, while 2 discs were present in 3 pelvises, 3 discs in 2 and all 4 discs were present in 2 pelvises (Table 1). In the coccyx, we observed the presence of only 1 disc in 3

Table 1.
Table showing the number of intervertebral discs present in the sacrum (Total number of pelvises studied = 56).

No of intervertebral discs present in sacrum	No of pelvises and percentage
0 discs	22 (39%)
1 disc	27 (48%)
2 discs	3 (5%)
3 discs	2 (4%)
4 discs	2 (4%)

Table 2.
Table showing the number of intervertebral discs present in the coccyx. (Total number of pelvises studied = 56).

No of intervertebral discs present in coccyx	No of pelvises and percentage
0 discs	49 (87%)
1 disc	3 (5%)
2 discs	2 (4%)
3 discs	2 (4%)

Table 3.
Table showing the position profile of intervertebral discs in male (M) and female (F) pelvises.

	B/w S1& S2	B/w S2& S3	B/w S3& S4	B/w S4 & S5	B/w Co1&Co2	B/w Co2&Co3	B/w Co3&Co4
M	19	6	5	9	4	2	2
F	3	2	2	1	—	—	—
%	39%	14%	13%	18%	7%	4%	4%

pelvises, 2 discs in 2 and 3 discs in 2 pelvises (Table 2). The position profile of the intervertebral disc is shown in Table 3, where we found that most of the specimens had discs between S1 and S2 vertebrae (39%), followed by between S4 and S5 (18%), S2-S3 (14%) and least being between S3-S4 (13%). In the coccyx, it was found that 7% of pelvises had disc between Co1-Co2, 4% of then had between Co2-Co3 and another 4% had between Co3-Co4. 2 pelvises (both male) had persistence of all 4 sacral and 3 coccygeal discs. Figures 3 and 4 show the occurrence and distribution of the intervertebral discs in the sacrum and coccyx respectively. Photographs of the pelvises showing the presence of intervertebral discs at various levels can be seen in Figures 5-9.

We measured the thickness of the discs and found that

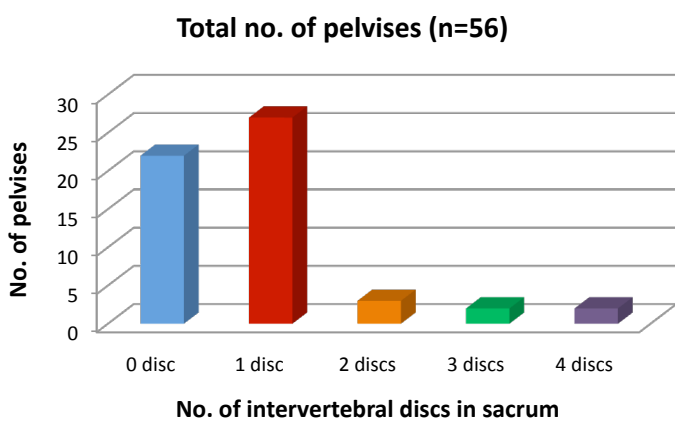

Figure 3.
Graph showing the number of sacral intervertebral discs in male and female pelvises collectively.

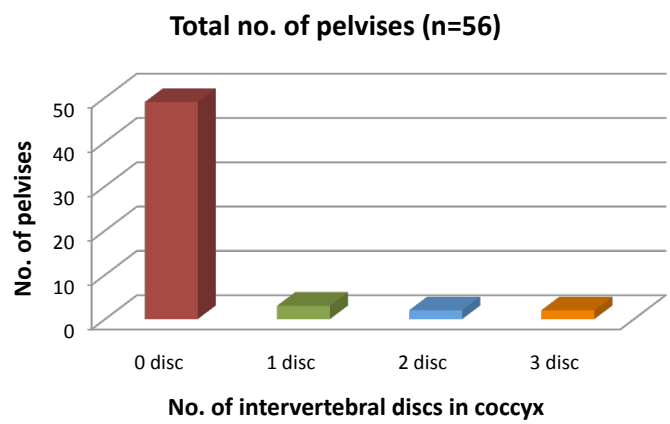

Figure 4.
Graph showing the number of intervertebral discs in male coccyx (Female coccyx did not possess intervertebral discs).

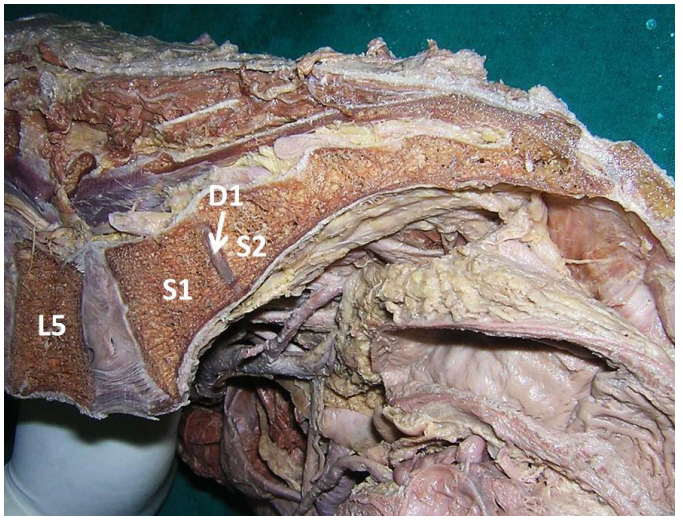

Figure 5.
Figure showing the presence of a single intervertebral disc (D1) in sacrum between S1 and S2. L5= fifth lumbar vertebra.

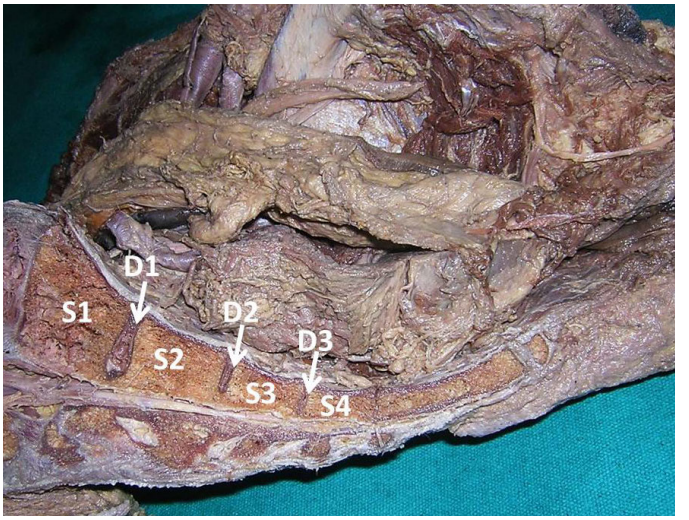

Figure 7.
Figure showing the presence of 3 intervertebral discs (D1, D2, D3) in sacrum between S1, S2, S3 and S4.

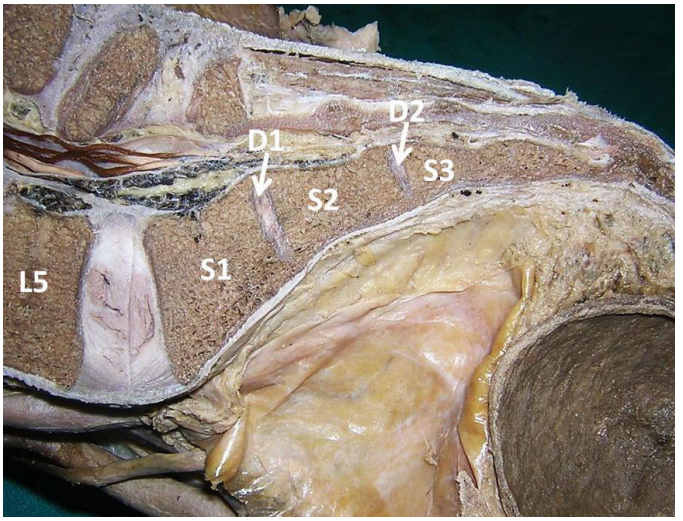

Figure 6.
Figure showing the presence of 2 intervertebral discs (D1 and D2) in sacrum between S1, S2 and S3. L5= fifth lumbar vertebra.

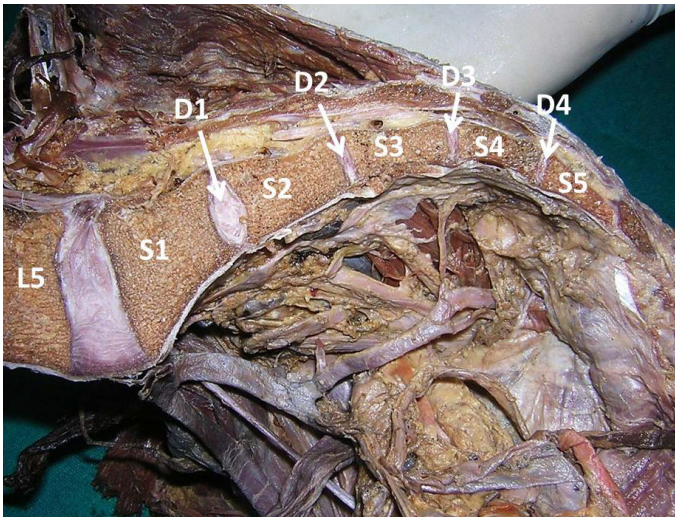

Figure 8.
Figure showing the presence of 4 intervertebral discs (D1, D2, D3, D4) between the 5 sacral vertebrae (S1, S2, S3, S4, S5). L5= fifth lumbar vertebra.

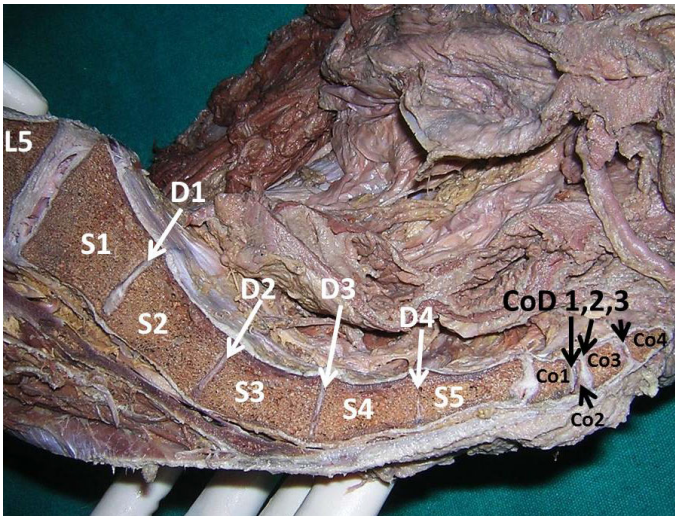

Figure 9.
Figure showing the presence of intervertebral discs (D1, D2,D3,D4) between all the sacral vertebrae (S1,S2,S3,S4,S5) and coccygeal intervertebral discs (CoD 1,2,3) between all the coccygeal vertebrae (Co1,Co2,Co3,Co4) . L5= fifth lumbar vertebra.

the maximum vertical thickness was 0.5 cm and minimum thickness was 0.2 cm.

Discussion

The vertebral column is formed by articulation of individual vertebrae. Its morphology is influenced externally by mechanical and environmental factors and internally by genetic, metabolic and hormonal factors.[1] The adult vertebral column usually consists of 33 vertebral segments. Between the vertebrae a fibrocartilaginous intervertebral disc is present which allows for the intervertebral movements and can sustain high compressive loads. The intervertebral disc consists of a central gelatinous core; the nucleus pulposus encircled by concentric layers of a densely fibrous connective tissue, the annulus fibrosus. The intervertebral discs are usually absent in the sacrum and coccyx due to the fusion of these vertebrae.

Vertebral body formation occurs during the fourth week of embryonic development as mesenchymal sclerotome cells migrate to surround the notochord. Each vertebral body is a combination of the caudal part of the sclerotome above and the cranial part of the sclerotome below; mesenchymal cells between cephalic and caudal parts of the original sclerotome segment form the intervertebral disc. The nucleus pulposus part of the intervertebral disc is formed from the notochord cells while the annulus fibrosus develops from the mesenchymal cells. In the sacrum, five vertebrae begin to fuse during childhood, beginning caudally and ascending, leaving no residual intervertebral sacral discs by early in the fourth decade of life.[7,8] A range of sacral segment fusion occurs during these stages of development, which may lead to the presence of residual disc remnants between the vertebral bodies in the sacrum.[9] Cadavers are the best means to study the variant anatomy of any region. During our literature review we found that there are no reports on any studies conducted about the persistence of intervertebral discs in sacrum and coccyx among the Indian population. Thus this study was conducted and we found promising results wherein 61% of the adult pelvises observed by us showed the presence of intervertebral discs between sacral vertebrae and coccygeal vertebrae. We assume that this variation may be due to the late fusion or incomplete fusion pattern of sacral and coccygeal vertebrae which may cause mobility of sacrum and coccyx leading to instability of the pelvic girdle. In a CT study done by Woon *et al*.[10], on adult coccyx they have found that sacrococcygeal and intercoccygeal joint fusion were common and it was not related to age or gender. Wu *et al*.[11], in their study on morphology of sacrum in the Chinese population believe that variations in sacral morphology are common in the Chinese population and these anatomic variations should be taken into consideration when diagnosing and treating sacrum-related diseases. They also postulate that such anatomic studies involving eastern populations are very rare and stress its importance.[11] Kaiser *et al*.[12], in their study on CT scans of pelvises opined that the prevalence of sacral dysmorphism ranged from 30% to 50%.

The lumbosacral region is one of the most variable regions of the spinal column. Most skeletal malformations occur in the area of the lumbosacral transition.[13-15] Lumbosacral transitional vertebrae are congenital spinal anomalies defined as either sacralisation of the lowest lumbar segment or lumbarization of the most superior sacral segment of the spine. Nicholsen *et al*.[16], have observed that when a lumbarized S1 is present, the disk space between S1 and S2 is larger than the rudimentary disc. This fact was observed in our study wherein there was presence of

intervertebral disc between S1 and S2 in 39% of the pelvises. O'Driscoll *et al*.[17], have developed a 4-type classification system of S1–2 disc morphology by using sagittal magnetic resonance images, depending on the presence or absence of disc material and the anteriorposterior length of the disc. Type 1 exhibits no disc material. Type 2 consists of a small residual disc with an AP length less than that of the sacrum. Type 3 is a well-formed disc extending the entire AP length of the sacrum. Type 4 is similar to type 3 but with the addition of squaring of the presumed upper sacral segment. Depending on this, we can claim that most of the discs in our specimens can be classified into type 2 and type 3. In type 3 disc types we found that the maximum vertical thickness of the disc was 0.5 cm and minimum thickness was 0.2 cm.

Valer Dzupa *et al*.[18], in their study have confirmed a high incidence of congenital malformations in the area of the lumbosacral transition and demonstrated a higher incidence of such cases in males. In our study, we observed that 78% of females had at least one disc in the sacrum while only 57% of males had at least one disc in the sacrum.

We also found the presence of discs between coccygeal vertebrae in 15% of male pelvises. We believe that this may lead to instability or excessive mobility of the coccyx. Some surgeons have opined that instability of coccyx may lead to pain in this region which is known as coccydynia. The pain is felt when the subject is in sitting position wherein the mobile coccyx may then align itself parallel to the seat. The coccygeal mobility can be assessed by dynamic radiographs. Lateral stress radiographs of the coccyx can show an organic lesion which affects coccygeal mobility.[19] Birender Balain *et al*.[20], have studied the fate of coccygeal intervertebral discs histologically and have found that out of total 22 intact specimens 10 had at least 2 discs or moving joints, and 11 had only 1 disc or moving joint. They observed that the disc spaces in the region were extremely variable, with examples of intact discs, discs with clefts, discs with cystic or fibrocystic changes, and discs replaced by synovial joints all being found. Wray *et al*.[21], report that it is possible to identify such variations before surgery radiologically by discography.

The fusion process of sacral and coccygeal vertebrae is said to be partially dependent on human upright posture and locomotion. It is found that in children who do not bear weight across the sacral region, as in paraplegia, the sacrum and coccyx do not fully fuse. Fusion at the lumbosacral junction, sacrum and coccyx distinguishes human sacra from other hominoid sacra.[9]

A residual disc space can be visualized between the dysmorphic upper and second sacral segments on the pelvic outlet plain radiograph and it happens in persons with dysmorphic sacral anatomy.[6] They suggest that dysmorphic sacra have distinct anatomic differences that must be noted prior to surgical intervention. Dysmorphic osseous characteristics of the sacrum include colinearity of the upper portion of the sacrum and the iliac crests, presence of mammillary bodies at the sacral ala, noncircular anterior sacral foramina, residual upper sacral discs etc.

These anatomic variations of the sacrum and coccyx are important to note because they require alterations in surgical fixation constructs which involves the sacrum like in sacral screw fixation for joint correction. The sacrum is a target point for sacral fixation during posterior lumbar body fusion (PLIF) and anterior lumbar body fusion (ALIF) procedures. Such instrumentation may carry the risks for neurovascular injury resulting in morbidity, and even mortality.[22] This dictates detailed knowledge of the sacrum and its regional anatomy. We are unsure of the exact factors behind such a high occurrence of intervertebral discs in the sacrum and coccyx of South Indians. We are unaware of the possible advantages or disadvantages of having these discs since we do not have any history of the cadavers. We had a limited number of pelvises. An extended study on a large number of pelvises might help us to understand the persistence of the disc better. Since it is difficult to get many cadavers, radiological studies on South Indians might produce interesting data about the persistence of intervertebral discs in sacrum and coccyx.

Conclusions

Surgical treatment of any sacral lesions requires detailed understanding of the underlying anatomy of sacro-coccygeal region and any variations related to it. Significant studies have been done towards the understanding of the sacral region by both anatomists and surgeons using MRI and CT scans. Much is to be learned with advances in surgical methods and instrumentation in the field of spinal surgery.[23] Presence of intervertebral discs in the sacrum and coccyx is a rare variation and knowledge regarding its prevalence is useful for orthopaedic surgeons, neuro-

surgeons, radiologists, obstetricians and anthropologists. Hence more studies on cadaveric specimens or radiological studies on living people have to be conducted to get a better understanding regarding the anatomy of this region.

References

1. Standring S. Gray's Anatomy. 39th Ed. London: Churchill Livingstone, 2008:749, 754,735.
2. Andrew Y. Choi, A. Orlando Ortiz, Douglas S. Katz, and Steven J. Lypen. Imaging of Sacrum in Spinal Imaging: Diagnostic Imaging of the Spine and Spinal Cord. Springer Science & Business Media, 2007:569.
3. Ebraheim NA, Xu R, Challgren E. Location of the sacral pedicle, foramina, and ala on the lateral aspect of the sacrum: a radiographic study. Orthop. 1998;21:703–706.
4. Mirkovic S, Abitbol JJ, Steinman J, et al. Anatomic consideration for sacral screw placement. Spine. 1991;16:289–294.
5. Morse BJ, Ebraheim NA, Jackson T. Preoperative CT determination of angles for sacral screw placement. Spine. 1994;19:604-607.
6. Anna N. Miller, and Milton L. Chip Routt, Jr. Variations in sacral morphology and implications for iliosacral screw fixation. J Am Acad Orthop Surg. 2012;20:8-16.
7. Sadler T.W. Langman's Medical Embryology. 10th ed. Lippincott Williams and Wilkins, 2006:140.
8. Frymoyer JW, Ducker TB, Hadler NM, Kostuik JP, Weinstein JN, Whitecloud TS. Surgical anatomy and operative approaches to the sacrum. In: The Adult Spine: Principles and Practice. Vol 2. Philadelphia: Lippincott-Raven, 1997:2329-2341.
9. Abitbol MM. Evolution of the sacrum in hominoids. Am J Phys Anthropol.1987; 74(1):65-81.
10. Woon JT, Perumal V, Maigne JY, Stringer MD. CT morphology and morphometry of the normal adult coccyx. Eur Spine J. 2013;22(4):863-870.
11. Wu LP, Li YK, Li YM, Zhang YQ, Zhong SZ. Variable morphology of the sacrum in a Chinese population. Clin Anat. 2009;22(5):619-626.
12. Kaiser Scott P, Gardner, Michael J, Liu, Joseph, Routt M. L. Chip Jr, Morshed Saam. Anatomic determinants of sacral dysmorphism and implications for safe iliosacral screw placement. J Bone Joint Surg. 2014;96:14 e120.
13. Apazidis A, Ricart PA, Diefenbach CM, Spivak JM. The prevalence of transitional vertebrae in the lumbar spine. Spine J. 2011;11:858–862.
14. Bron JL, Van Royen BJ, Wuisman PI. The clinical significance of lumbosacral transitional anomalies. Acta Orthop. 2007;73:687–695.
15. Dai L. Lumbosacral transitional vertebrae and low back pain. Bull Hosp Jt Dis. 1999;58:191–193.
16. Nicholson AA, Roberts GM, Williams LA. The measured height of the lumbosacral disc in patients with and without transitional vertebrae. Br J Radiol. 1988;61:454–455.
17. O'Driscoll CM, Irwin A, Saifuddin A. Variations in morphology of the lumbosacral junction on sagittal MRI: correlation with plain radiography. Skeletal Radiol. 1996;25:225–230.
18. Valer Dzupa, Slepanek, Striz, Krbec J, Chmelova D, Kachlik V. Developmental malformations in the area of the lumbosacral transitional vertebrae and sacrum: differences in gender and left/right distribution. Surg Radiol Anat. 2014;36:689–693.
19. Maigne J Y, Lagauche D, Doursounian L. Instability of the coccyx in coccydynia. J Bone Joint Surg. 2000;82-B:1038-1041.
20. Birender Balain, S. M. Eisenstein, G. O. Alo, Alan J. Darby,V. N. Cassar-Pullicino, S. E. Roberts, D. C. Jaffray. Coccygectomy for coccydynia: case series and review of literature. Spine. 2006;31:E414–E420.
21. Wray CC, Easom S, Hoskinson J. Coccydynia. Aetiology and treatment. J Bone Joint Surg Br. 1991;73-B:335–338.
22. Candan Arman, Sait Naderi, Amaç Kiray, Funda Tastekin Aksu, Hakan Sinan Yılmaz, Süleyman Tetik, Esin Korman. The human sacrum and safe approaches for screw placement. J Clin Neurosci. 2009;16:1046–1049.
23. Swathi Poornima C. Complete dorsal wall defect in dry human sacrum: a case report. International J Med Res Health Sci. 2013;2(2):290-292.