

The use of a multi-modal approach in the rehabilitation of a pre-operative grade 3 ACL tear in a world-level Poomsae athlete: a case report

Michael Edgar, BKin, DC¹

Mohsen Kazemi, RN, DC, FRCCSS(C), FCCPOR(C), MSc, PhD¹

Objective: *This case is designed to aid practitioners in understanding the potential role of multi-modal care with vibration rehabilitative exercise for a complete ACL tear in a high-level Poomsae athlete.*

Case presentation: *A 16-year-old male world-class Poomsae athlete presented with a right ACL rupture and LCL sprain. An extensive clinical examination and imaging confirmed a right grade 3 ACL tear. Due to the complete tear and impending participation in World Championships, a pre-operative rehabilitation strategy was implemented with treatment modalities aimed to accelerate return-to-play.*

Summary: *An appropriate clinical history and physical examination of the knee is required when instability is present. Imaging is indicated when testing criteria are positive. Clinicians should be aware that*

Objectif : *Le présent exposé de cas vise à aider les praticiens à comprendre le rôle que pourrait jouer le traitement multimodal associé à des exercices de rééducation par vibrations chez un athlète de haut calibre pratiquant le poomsae ayant subi une déchirure complète du LCA.*

Exposé du cas : *Un athlète de 16 ans de calibre international, pratiquant le poomsae, avait subi une déchirure du LCA droit et une entorse du ligament latéral externe (LLE). Un examen clinique approfondi et un examen par imagerie ont confirmé une déchirure du LCA droit de grade 3. Comme il s'agissait d'une déchirure complète et que la participation de l'athlète aux championnats internationaux était imminente, on a opté pour une rééducation préopératoire et des modalités thérapeutiques pour accélérer le retour au jeu de l'athlète.*

Résumé : *Un examen du tableau clinique et un examen physique du genou s'avèrent nécessaires en cas de genou instable. Un examen par imagerie est indiqué lorsque les critères d'instabilité sont satisfaits.*

¹ Canadian Memorial Chiropractic College

Corresponding author:

Michael Edgar, Canadian Memorial Chiropractic College, 6100 Leslie Street, Toronto, ON M2J 3J1

Tel: 416-482-2340

E-mail: medgar@cmcc.ca

© JCCA 2020

The authors have no disclaimers, competing interests, or sources of support or funding to report in the preparation of this manuscript.

The involved patient provided consent for case publication.

multiple therapies can each serve a role in conservative care to better suit patient demands, especially at high levels of sport. In the article, the author proposes a tailored protocol using vibration rehabilitative exercise, bracing, vibration therapy, neuromuscular electrical stimulation, and laser to improve healing and sport-specific outcomes.

(JCCA. 2020;64(3):248-257)

KEY WORDS : chiropractic, ACL, anterior cruciate ligament, taekwondo, poomsae, vibration, multimodal

Introduction

The traditional form of Taekwondo, which is a form of martial arts involving sparring, has been performed for many years. It has seen a recent popularization since the 2000 Summer Olympic Games, where it officially became a full medal sport. Overall, there has been an increase in the level of participation in Taekwondo with over 80 million athletes worldwide.^{1,2} Due to Taekwondo's popularity, Poomsae has gained a recognized position in the sporting community with its first world-level championship in 2006.^{3,4} Poomsae is the only non-contact form of Taekwondo and has a high degree of technical involvement due to the basis of its scoring.^{3,4} In addition, it involves skill, technique, flexibility, fluidity and physical exertion. Recognized Poomsae involves 13 defined patterns of movement which are emphasized repeatedly during sport-specific practice.^{3,4} On average, Poomsae athletes train up to six days a week with each session lasting for up to four hours and forty minutes.^{3,4}

Due to the workload these athletes experience and the demand of the sport, injuries can be detrimental especially at higher levels of performance. In regard to the injury rates for Poomsae and sparring, it was found that lower limb and back were the most common areas of injury in females and males respectively.⁴⁻⁶ Poomsae is the only non-contact and no opponent form of Taekwondo but de-

Les cliniciens devraient savoir qu'on pourrait avoir recours à une approche multimodale lorsqu'on envisage un traitement conservateur pour mieux répondre aux besoins du patient, en particulier ceux qui pratiquent des sports de haut niveau. L'auteur de l'article propose un protocole personnalisé comprenant des exercices de rééducation par vibrations, le port d'une attelle, un traitement par vibrations, la neurostimulation électrique transcutanée et des traitements par laser pour favoriser la guérison et l'obtention de résultats axés sur ce sport en particulier.

(JCCA. 2020;64(3) : 248-257)

MOTS CLÉS : chiropratique, LCA, ligament croisé antérieur, taekwondo, poomsae, vibration, multimodal

spite its non-contact nature, the lower limb and back were still the most common areas of injury.⁴

A retrospective case series by Kazemi *et al.*⁷ investigated the effects of injury on Taekwondo sparring performance by following 75 Taekwondo athletes over a ten-year period. They found that an injury that occurred during competition led to the athlete having an 88% less likely chance to win a medal.⁷ A paper by Kasbparast *et al.*⁸ highlighted the rates of anterior cruciate ligament (ACL) injury amongst Taekwondo sparring athletes. They found that the main mechanism of action for a torn ACL was that the athlete had a planted foot with the knee in an almost extended position (sometimes hyper-extended). In addition, they found the rates of ACL injury to be highest during practice compared to competition.⁸ Although this is the case, the literature regarding the prevalence of ACL rupture in Poomsae-specific athletes is sparse. Due to the degree of pivoting that each of the fundamental movements requires, the stability of the knee plays an integral role to technique and scoring and therefore placing at a world-level event.³

An ACL injury can typically be separated into three grades, ranging from grade one involving mild damage to grade three which involves a complete rupture of the ligament.⁹⁻¹¹ Among young male athletes, the rate of ACL injuries has increased within the last 20 years while the rate of surgical repairs for ACL ruptures is estimated at 47 per

100,000 boys each year.¹⁰ This injury can lead to several complications, including acute intra-articular swelling and instability, quadriceps strength deficits, and decreased range of motion.¹⁰ As strength, stability and full range of motion are essential for the sport of Poomsae, the effects of these variables on performance can be significant.⁹⁻¹¹ The first line of treatment for an ACL rupture is conservative management and rehabilitation, followed by surgical intervention with postoperative rehabilitation if the patient develops functional instability.¹²⁻¹⁴ Conservative management involves interventions such as, chiropractic manipulation, mobilization, exercise, soft tissue therapy, nonsteroidal anti-inflammatory drugs, and steroid injections.¹²⁻¹⁴

A case of an ACL rupture in a sixteen-year-old male, world-class Poomsae athlete is presented to illustrate clinical presentation, diagnosis, imaging assessment, and conservative chiropractic management. The patient ended up placing in the top 10 at the World Poomsae Championships, only two weeks after his last treatment and with no reported knee pain or instability during his competition.

Case report

A sixteen-year-old male, world-class Taekwondo Poomsae athlete, presented with right knee pain which started two days prior to his initial visit after executing a round-house kick, during which the right leg twisted and gave way after landing. Training was stopped after this and the pain was initially focused on the lateral side of the knee. After his practice session, he had discomfort bending and straightening the knee with noticeable aggravation upon walking with feelings of instability upon weight bearing. He focused on icing the area until his initial appointment with his sports chiropractor two days later. He did not have any prior injuries to his knee, and his past medical history and systems review were unremarkable and non-contributory to his chief complaint.

On examination, lower extremity deep tendon reflexes were 2+ bilaterally and light touch sensation examination was unremarkable. In addition, heel and toe walking were normal with pain at the end range of flexion during the squat test. His right knee (ROM) flexion and extension were reduced by 10% with pain in the lateral knee. The bounce home test, McMurray, Anderson and Lachman tests were positive on the right. Pivot shift, valgus loading, posterior drawer and posterior sag were negative. There



Figure 1.
Front kick.

was no noticeable clicking or locking upon examination and only mild swelling over the right lateral knee with sharp pain upon palpation. His right popliteus, iliotibial band, lateral collateral ligament (LCL), quadriceps and hamstrings were hypertonic and tender upon palpation.

A clinical diagnosis of right LCL grade 1 sprain, right lateral meniscus lesion and right ACL grade 2 sprain were made with associated myofascial pain. Initial treatment consisted of 15 minutes of acupuncture (AC) of the following points: GB33, GB34, ST36, SP9 and BL39 with TENS at 2Hz; Local vibration therapy using VMTX® device (made by Thumper®, 25-45Hz, 4-5 mm vertical displacement) to the right popliteus, iliotibial band, quadriceps, hamstrings and posterior and lateral fascial chains. A brace was prescribed to improve walking ability and rehabilitation was started with straight leg raises and slow, non-explosive front snap kicks (Figure 1).

The patient was initially referred for an x-ray in his first week of treatment which found no acute fracture or dislocation of the knee, although moderate knee effusion was observed. He was subsequently referred to his family physician to obtain a referral for an MRI of the knee. The physician referred the patient to an orthopedic surgeon who agreed with the diagnosis, requested an MRI of the knee, and referred the patient back to his sports chiropractor for further conservative treatment. The right knee

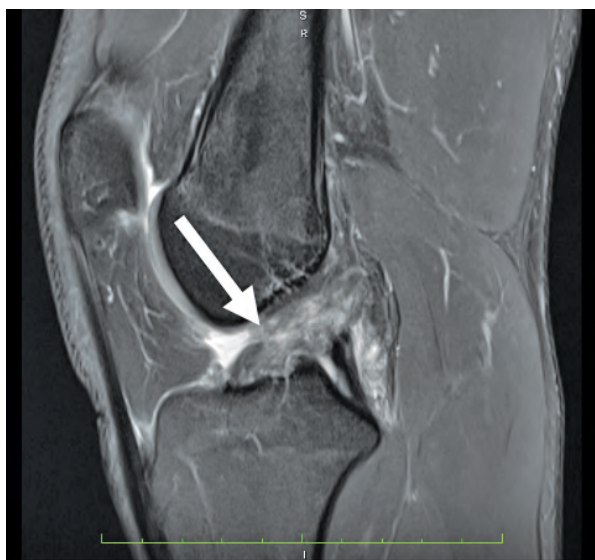

Figure 2.

A T2-weighted oblique sagittal MR image of the right knee demonstrating a grade 3 complete ACL tear (white arrow).

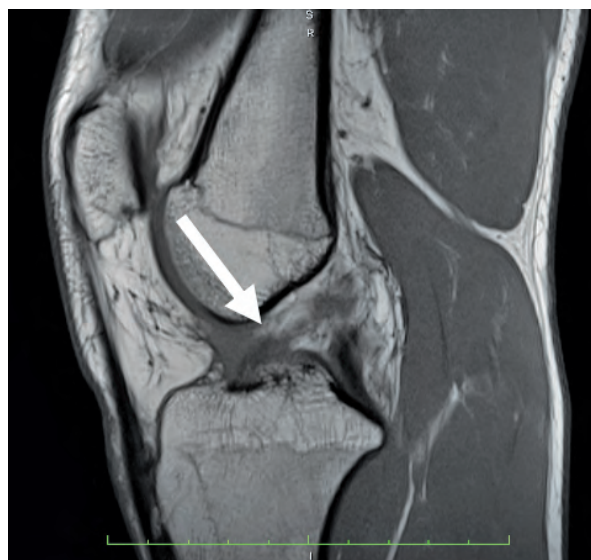

Figure 3.

A T1-weighted oblique sagittal MR image of the right knee demonstrating a grade 3 complete ACL tear (white arrow).

Table 1.
Exercise progression.

| Exercise and duration | Week implemented |
|----------------------------------|------------------|
| SLR | Week 1 |
| Front Kick | Week 1 |
| Squat 90 | Week 2 |
| Boeing 747 | Week 2 |
| Heel Raises | Week 2 |
| Side Kick Hold | Week 2 |
| Lunge (front stance) | Week 2 |
| One Legged Supine Hamstring Curl | Week 2 |
| Hamstring Curl on Ball | Week 5 |
| Front Snap Kick | Week 11 |
| 3 sets of 30 seconds | Week 1-12 |
| 3 sets of 40 seconds | Week 4-12 |

MRI indicated a complete ACL tear (Figures 2 and 3) and mid-grade partial tear of the LCL. It was decided that the focus should be on conservative, non-operative therapy as the Poomsae World Championships were taking place fourteen weeks later.


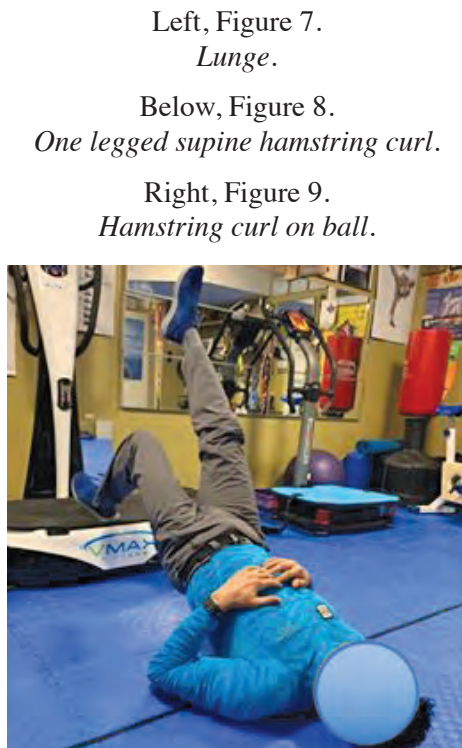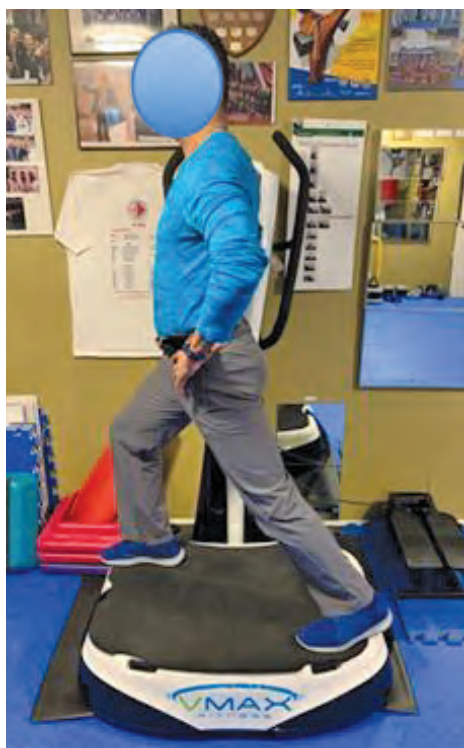
At the end of the second week, there was no visible swelling over the anterior knee and only minimal swelling on the lateral aspect. Right knee flexion and extension ranges of motion were full with a positive Lachman's test and negative Varus load test. Hyperalgesia and hypertonicity of the popliteus, iliotibial band, LCL, quadriceps and hamstrings were diminished. At this time, the treatment was changed to primarily rehabilitation. The rehabilitation program consisted of weight-bearing squats at 90 degrees (Figure 4), heel raises, 747 and sidekick holds (Figures 5 and 6), lunges (Figure 7), back stance and supine isometric one-legged hamstring curls (Figure 8) for three sets of thirty seconds on the whole body vibration (WBV) machine (VMAX® Elite 7) at 20 Hz with 3.2 mm vertical displacement. (See Table 1 for a more thorough chart of the exercise progression). This was done in conjunction with electro-muscular stimulation over the quad-



Left, Figure 4.
90 Degree Body Weight Squat

Above, Figure 5.
Boeing 747

Right, Figure 6.
Side kick hold.



Left, Figure 7.
Lunge.

Below, Figure 8.
One legged supine hamstring curl.

Right, Figure 9.
Hamstring curl on ball.

riceps and hamstrings with 15 seconds on and 10 seconds off as he practiced on the WBV. Local vibration therapy using VMTX® (VMTX Thumper® massager) was done to the right popliteus, iliotibial band, LCL, quadriceps and hamstrings, posterior and lateral lower limb myofascial chains. The same exercises were prescribed for at-home use with an avoidance of rotation and sudden stopping on the right side.

At the end of the fourth week, modifications had been made to his Poomsae routine and the patient was fitted with a Donjoy® ACL brace based on the recommendation of his orthopedic surgeon. There was no longer pain or instability during his Taekwondo practice. The exercises on WBV increased to 40 second holds at week four. Rehabilitation exercises continued with incorporation of supine hamstring curls on a physiotherapy ball (figure 9) for 3 sets of 10 repetitions on week five. An advanced front snap kick was incorporated at week eleven to incorporate an explosive movement. Laser was applied to the anterior and lateral knee at 10J with cryotherapy for 10 minutes after the rehabilitation exercises.

The same treatment was continued one or two times per week for twelve weeks. At the end of this treatment course, the athlete felt no pain in the right knee and had full ability in his Taekwondo practice with no sensation of 'giving way.' Two weeks following his final appointment, the athlete competed in the Poomsae World Championships without using any brace and placed in the top 10. He did not report any give way or pain during the competition or training.

Discussion

In this case, the athlete experienced an immediate reduction in his knee ROM after a roundhouse kick. The athlete suffered from a full ACL and partial LCL tears. The main symptoms experienced by the athlete were localized knee pain, decreased range of motion, feelings of instability, and weakness, although significant swelling was not present. Parkarri *et al.*¹⁵ found the knee was the most common location for injury in younger individuals. In addition, they found that participation in organized sports significantly increases the risk of a cruciate ligament injury of the knee.¹⁵ An anterior cruciate ligament injury is typically sustained at foot strike with the knee close to full extension with a sudden deceleration prior to a change of direction or landing motion due to the rotational forces.^{9,10}

Previous literature has described several risk factors for the predisposition of ACL injury, including increased general joint laxity, increased patellar tendon length, increased knee abduction angles, and decreased knee flexion angles. Specific anatomical risk factors include the intercondylar notch width (NW) and tibial slope.⁸⁻¹⁰

In the current case, x-rays were initially ordered to rule out knee pathology. Several guidelines and rules are available to recognize red flags for radiographic imaging of this bodily region. The Ottawa Knee Rules recognize several red flags: age greater than 55 years old, inability to bear weight immediately or the inability to take four steps, isolated tenderness of the patella or fibular head, and inability to flex to 90 degrees.¹¹ However, the Pittsburgh Knee Rules differ by highlighting four red flags: fall or blunt trauma, less than 12 years old or greater than 50 years old, and an inability to take four steps.¹⁴ In the case presented, an inability to flex to 90 degrees and issues weight bearing were noted; therefore, routine knee x-rays were ordered to rule out any osseous lesions. The x-ray appeared unremarkable, but the athlete was then referred to an orthopedic surgeon who confirmed a complete right ACL tear by clinical examination and MRI. One reason for the referral was to obtain an MRI since chiropractors in Ontario, Canada are unable to directly order MRI.¹⁶ The orthopedic surgeon referred the athlete back to the sports chiropractor for conservative management. Major *et al.*¹⁷ found MR imaging to be the gold standard for knee imaging in adolescents due to its avoidance of the exposure to ionizing radiation, and ability to illustrate the menisci and cruciate ligaments. The anterior cruciate ligament was the major focus of this case and highlights the utility of this imaging modality.

Conservative management is considered a first-line treatment option for anterior cruciate ligament injuries.^{12,13} The case presented a conservative approach focusing on a multimodal treatment plan. Interventions for multimodal care include strengthening, proprioceptive exercises, sport-specific exercises, bracing, activity modifications, neuromuscular stimulation, vibration therapy and laser, which have been shown to be beneficial for the treatment of ACL injuries.^{12,13, 18-27}

Many authors have reported success using progressive rehabilitation programs from partial weight-bearing to full weight-bearing with a predominant focus on quadriceps and hamstring strengthening.^{12,13, 18} The goal for this

form of strengthening is to improve active stabilization of the major muscles around the knee to prevent translation of the tibia relative to the femur during loading of the lower limb.¹⁸ In the case provided, strengthening and proprioceptive exercises were successfully implemented. This was done in conjunction with a Donjoy® brace which is designed to reduce knee instability following an anterior cruciate ligament injury by providing passive integrity.²⁶ The brace was warranted and utilized for the athlete's sport-specific Poomsae movements which require a high degree of pivoting and knee stabilization.³ Knee bracing for pre-operative anterior cruciate ligament injury has shown to improve subjective perceptions of knee instability, although it had no effect on activation of the quadriceps or hamstrings, in conjunction with functional movements.^{28,29}

Transcutaneous electrical nerve stimulation (TENS) is recognized to have several benefits physiologically and therapeutically by eliciting a current and contraction within the musculature it is applied to without voluntary control.^{19,20} At the present time, no studies or literature reviews have been conducted into NMES efficacy prior to ACL reconstruction. However, Lee *et al.*¹⁹ reported good outcomes for the use of TENS on the quadriceps for the reductions of pain and improved strength after ACL reconstruction. As well, Kim *et al.*²⁰ performed a systematic review and found neuromuscular electrical stimulation (NMES) combined with exercise may be more effective in improving quadriceps strength than exercise alone after ACL reconstruction. It is the authors' belief that this gave credence into the effectiveness of NMES stimulation combined with exercise during the case presented.

Vibration is believed to work through a tonic vibratory reflex (TVR).^{30,31} This is purported to be through rapid, successive micro-muscular stretches which trigger intra-fusal muscle spindle activity.^{30,31} This is believed to lead to decreased muscle inhibition and improve the ability to recruit a higher threshold of motor units.^{30,31} Vibration can be applied locally or through whole-body vibration (WBV). The neurophysiological mechanism may differ between both, as WBV generally activates multiple different mechanoreceptors which can synchronize motor unit firing and central motor commands to globally improve neuromuscular activation patterns.³⁰ In addition, WBV can potentially work as a neuromuscular training meth-

od where the subject stands on a platform that generates vertical sinusoidal vibrations.²¹ In contrast, local muscle vibration (LMV) uses a smaller device typically applied to one bodily region. The neurophysiological mechanism for LMV is theorized to work through its activation of receptors proximal to the site of administration.^{30,31}

Vibratory stimulation combined with resistance training has gained popularity in an attempt to gain greater neuromuscular activation. It has been shown to improve nerve-muscle function, realign muscle fibers, and induce relaxation of stretched muscle tissue.²¹⁻²³ It can be speculated from the research that in a rehabilitative exercise setting, vibration therapy can allow for improved strength, power and proprioception to better attenuate the sports-related deficits from an acute injury.^{21-23, 30,31} Pain reduction has also been noted purportedly through the activation of skin mechanoreceptors leading to the stimulation of inhibitory interneurons. This is theorized to downregulate pain signals by alpha and C-fibers by the gate control mechanism.²³ Macintyre and Kazemi²¹ found that the best analgesic and pain-reducing effect occurred when vibration was localized to the region of pain on the affected muscle or tendon. On a systemic level, vibration therapy has been found to elicit increased angiogenesis through promoting pro-healing growth factors and chemokines.^{32,33} Improved blood flow has also been found in the lower extremity for healthy individuals and is theorized to potentiate increased healing rates and ability.³⁴ Typically, frequency and amplitude of vibration stimulus can range from five to 300Hz and 0.12 to 12 mm respectively.³⁵ However, higher frequencies required exposure of 30 minutes to achieve the same results of one to two minutes exposure of 20-50Hz.³⁵ In addition, higher frequencies above 60Hz (60-500Hz) have been associated with cumulative trauma disorders.^{36,37} As such for the patient in this case, vibration with 20-50Hz range with amplitude of 3.2-5mm was used as this is more time efficient and safer.³⁵⁻³⁷

For the athlete described in the case, the use of whole body and local vibration was used for several purposes. Arthrogenic muscle inhibition (AMI) of the quadriceps muscles is a common occurrence after ACL injury.^{38,39} The phenomenon involves quadriceps activation failure by neural inhibition. There are several theories for this occurrence relating to resting motor thresholds, aberrant articular sensory receptor discharge, spinal reflexes and executive function related to abnormal cortical func-

tion.³⁸ Vibration was implemented to improve motor unit recruitment for the athlete due to AMI of the knee. This had the dual benefit of improving strength capacity and reducing the degree of atrophy in the lower limb musculature.³⁰ Vibration also was used to stimulate afferent input within the intrafusal structures within the knee to improve proprioceptive capacity, an aspect which appears to be reduced when intra-articular derangement is present within the knee.^{30,38,39} As the athlete's sport required high degrees of coordination and balance, proprioceptive input and overall kinesthetic awareness was a top priority.⁴ Whole-body platform vibration combined with exercise was incorporated successfully into the plan of management of the athlete presented in the current case study.

The goal of improved healing time was also prioritized due to the time demands until his next tournament. As the athlete presented at acute onset of the injury, mitigating the initial inflammatory response at the knee was focused on. Upon ACL injury, local cytokines and inflammatory mediators like IL-6, IL-8, VEGF, and TGF β I are released within the synovium and ligaments to accelerate both catabolic and anabolic activities.⁴⁰ Local vibration therapy to the affected tissues has shown to improve perfusion to both increase uptake of nutrients within the tissues and recycling of damaged structures.^{32,33} For this athlete, vibration was applied to the knee region with the goal of accelerated healing in mind. It was also applied directly over the knee itself to elicit an analgesic response.²¹ The use of local vibration was appropriately implemented within the treatment plan of this patient.

Basic research into low-level laser therapy (LLLT) has shown to reduce knee inflammation in rat models and LLLT with 50 mW reduced cellular inflammation and decreased the expression of IL-1 β and IL-6.^{24,25} The utility of LLLT can be two-fold due to its therapeutic window for anti-inflammatory actions overlapping with its ability to improve tissue repair. A new hypothesis into its efficacy revolves around it having a systemic effect through nitric oxide synthesis (NOS) and local TNF levels.²⁴⁻²⁶ Although the clinical effectiveness of laser therapy for acute ACL rupture in the athletic populations remains controversial, inflammation was treated. LLLT and ice was utilized on the right knee and localized tissues to decrease inflammation after the rehabilitation exercises and possibly improve healing times.

Limitations

Limitations of this case report include the initial symptomatology and complexity of the plan of management, meaning that the effects of each treatment or their combined effect cannot be determined when natural history is also accounted for. Firstly, the minimal swelling noted on initial examination may have led to a more rapid progression to rehabilitation. This paramount factor could have been the determining factor in the success of this athlete. In addition, the case also presented an elite-level athlete which current research populations do not generalize to. Furthermore, research into NMES primarily looked at post-ACL reconstruction whereas the current case highlights an athlete prior to ACL reconstruction. More so, LLLT research is sparse for ACL injuries and is limited to basic research at the current time. Higher quality research is recommended to investigate prognostic factors revolving around swelling and rehabilitation rates, in conjunction with the effectiveness of the management protocol described in the case.

Summary

Lower limb injuries are a common occurrence in Taekwondo athletes. This case demonstrates the use of multimodal care in conjunction with active therapy using WBV for an acute, destabilizing lower limb injury in a world-level athlete who requires high levels of coordination and control. Exercise and progressive strengthening are considered the first line of care for rehabilitation as they have the ability to improve function and stability. Despite the lack of research into combined treatments, there may be benefits to simultaneous care with exercise, vibration therapy, and neuromuscular activation when peak performance requirements and time constraints are present. The current literature combined with the clinical outcome described in the case suggests that multimodal care, including progressive exercise, vibration therapy, NMES and LLLT can potentially offer a therapeutic benefit greater than simply one modality alone. Further research is required to investigate the efficacy and associations of these modalities when used in conjunction in a larger study population.

References

1. Kazemi M, Pieter W. Injuries at a Canadian National Taekwondo Championships: a prospective study. *BMC Musculoskel Dis*. 2004;5(1):22.
2. Thomas RE, Thomas BC, Vaska MM. Injuries in taekwondo: systematic review. *Physician Sportsmed*. 2017;45(4): 372-390.
3. Poomsae Scoring Guideline [Internet]. WFC; Available from <http://www.tc-sidestep.de/files/WTF---Poomsae-scoring-guidelines.pdf>
4. Kazemi M, Ingar A, Jaffery A. Injuries in elite taekwondo poomsae athletes. *J Can Chiropr Assoc*. 2016;60(4):330-341.
5. Pieter W, Fife GP, O'Sullivan DM. Competition injuries in taekwondo: a literature review and suggestions for prevention and surveillance. *Br J Sports Med*. 2012;46(7): 485-491.
6. Kazemi M, Waalen J, Morgan C, White AR. A profile of Olympic taekwondo competitors. *J Sports Sci Med*. 2006;5(CSSI):114-121.
7. Kazemi M. Relationships between injury and success in elite Taekwondo athletes. *J Sports Sci*. 2012;30(3): 277-283.
8. Kasbparast Jr M, Rahimi A, Aghaei F, Shokrgozar A, Sangachin MH. Comparing the incidence of anterior cruciate ligament injury in collegiate male soccer, taekwondo and basketball players. *Biological Forum*. 2014; 6(2): 387-392.
9. Boden BP, Dean GS, Feagin JA, Garrett WE. Mechanisms of anterior cruciate ligament injury. *Orthopedics*. 2000;23(6): 573-578.
10. Kay J, de SA D, Karlsson J, Musahl V, Ayeni OR. Anterior cruciate ligament rupture: a family affair. *Orthopaed J Sports Med*. 2015;3(11): 2325967115616783.
11. Seaberg DC, Jackson R. Clinical decision rule for knee radiographs. *Am J Emerg Med*. 1994;12(5):541-543.
12. Strehl A, Eggli S. The value of conservative treatment in ruptures of the anterior cruciate ligament (ACL). *J Trauma Acute Care Surg*. 2007;62(5): 1159-1162.
13. Bogunovic L, Matava MJ. Operative and nonoperative treatment options for ACL tears in the adult patient: a conceptual review. *Physician Sportsmed*. 2013;41(4): 33-40.
14. Cheung TC, Tank Y, Breederveld RS, Tuinebreijer WE, de Lange-de Klerk ES, Derksen RJ. Diagnostic accuracy and reproducibility of the Ottawa knee rule vs the Pittsburgh decision rule. *Am J Emerg Med*. 2013;31(4): 641-645.
15. Parkkari J, Pasanen K, Mattila VM, Kannus P, Rimpelä A. The risk for a cruciate ligament injury of the knee in adolescents and young adults: a population-based cohort study of 46 500 people with a 9 year follow-up. *Br J Sports Med*. 2008;42(6):422-426.
16. Home [Internet]. College of Chiropractors of Ontario. CCO; [cited 2020Mar31]. Available from: <https://www.cco.on.ca/members-of-cco/standard-of-practice/>
17. Major NM, Beard Jr LN, Helms CA. Accuracy of MR imaging of the knee in adolescents. *Am J Roentgen*. 2003;180(1): 17-19.
18. Hart JM, Kuenze CM, Pietrosimone BG, Ingersoll CD. Quadriceps function in anterior cruciate ligament-deficient knees exercising with transcutaneous electrical nerve stimulation and cryotherapy: a randomized controlled study. *Clin Rehabil*. 2012;26(11): 974-981.
19. Lee DJ, Shim JH, Yoon SI, Park SJ. Effect of convergence-based Russian current and transcutaneous electrical nerve stimulation at quadriceps muscles on pain, strength, and performance in persons with anterior cruciate ligament reconstruction. *J Kor Conver Soc*. 2017;8(1):77-87.
20. Kim KM, Croy T, Hertel J, Saliba S. Effects of neuromuscular electrical stimulation after anterior cruciate ligament reconstruction on quadriceps strength, function, and patient-oriented outcomes: a systematic review. *J Ortho Sports Phys Ther*. 2010;40(7): 383-391.
21. Macintyre I, Kazemi M. Treatment of posttraumatic arthrofibrosis of the radioulnar joint with vibration therapy (VMTX Vibromax Therapeutics™): a case report and narrative review of literature. *J Can Chiropr Assoc*. 2008;52(1):14-23.
22. Luo J, McNamara B, Moran K. The use of vibration training to enhance muscle strength and power. *Sports Med*. 2005;35(1): 23-41.
23. Falempin M, In-Albon SF. Influence of brief daily tendon vibration on rat soleus muscle in non-weight-bearing situation. *J Appl Physio*. 1999;87(1): 3-9.
24. Alves AC, de Paula Vieira R, Leal-Junior EC, dos Santos SA, Ligeiro AP, Albertini R, Junior JA, de Carvalho PD. Effect of low-level laser therapy on the expression of inflammatory mediators and on neutrophils and macrophages in acute joint inflammation. *Arthritis Res Ther*. 2013;15(5):1-1.
25. Pallotta RC, Bjordal JM, Frigo L, Junior EC, Teixeira S, Marcos RL, Ramos L, de Moura Messias F, Lopes-Martins RÁ. Infrared (810-nm) low-level laser therapy on rat experimental knee inflammation. *Lasers Med Sci*. 2012;27(1): 71-78.
26. Gigo-Benato D, Geuna S, Rochkind S. Phototherapy for enhancing peripheral nerve repair: a review of the literature. *Muscle Nerve*. 2005;31(6):694-701.
27. Paluska SA, McKeag DB. Knee braces: current evidence and clinical recommendations for their use. *Am Fam Phys*. 2000;61(2): 411-418.
28. Swirtun LR, Jansson A, Renström P. The effects of a functional knee brace during early treatment of patients with a nonoperated acute anterior cruciate ligament tear: a prospective randomized study. *Clin J Sport Med*. 2005;15(5): 299-304.
29. Della Villa F, Ricci M, Perdisa F, Filardo G, Gamberini J,

- Caminati D, Della Villa S. Anterior cruciate ligament reconstruction and rehabilitation: predictors of functional outcome. *Joints*. 2015;3(04): 179-185.
30. Pamukoff DN, Ryan ED, Blackburn JT. The acute effects of local muscle vibration frequency on peak torque, rate of torque development, and EMG activity. *J Electromyogr Kinesiol*. 201;24(6): 888-894.
 31. De Ruiter C, Van Der Linden R, Van der Zijden M, Hollander A, De Haan A. Short-term effects of whole-body vibration on maximal voluntary isometric knee extensor force and rate of force rise. *Eur J Appl Physiol*. 2003;88(4-5): 472-475.
 32. Weinheimer-Haus EM, Judex S, Ennis WJ, Koh TJ. Low-intensity vibration improves angiogenesis and wound healing in diabetic mice. *PloS One*. 2014;9(3).
 33. Arashi M, Sugama J, Sanada H, Konya C, Okuwa M, Nakagami G, Inoue A, Tabata K. Vibration therapy accelerates healing of Stage I pressure ulcers in older adult patients. *Adv Skin Wounds Care*. 2010;23(7): 321-327.
 34. Lohman III EB, Petrofsky JS, Maloney-Hinds C, Betts-Schwab H, Thorpe D. The effect of whole body vibration on lower extremity skin blood flow in normal subjects. *Med Sci Monitor*. 2007;13(2):CR71-76.
 35. Germann D, El Bouse A, Jordan Shnier NA, Kazemi M. Effects of local vibration therapy on various performance parameters: a narrative literature review. *J Can Chiropr Assoc*. 2018;62(3): 170-181.
 36. Sauni R, Paakkonen R, Virtema P, Toppila E, Uitti J. Does-response relationship between exposure to hand-arm vibration and health effects among metalworkers. *Ann Occup Hyg*. 2009;53(1): 55-62.
 37. Lis AM¹, Black KM, Korn H, Nordin M. Association between sitting and occupational LBP. *Eur Spine J*. 2007;16(2):283-298.
 38. Chmielewski TL, Stackhouse S, Axe MJ, Snyder-Mackler L. A prospective analysis of incidence and severity of quadriceps inhibition in a consecutive sample of 100 patients with complete acute anterior cruciate ligament rupture. *J Orthop Res*. 2004;22(5): 925-930.
 39. Sonnery-Cottet B, Saithna A, Quelard B, Daggett M, Borade A, Ouanezar H, Thaunat M, Blakeney WG. Arthrogenic muscle inhibition after ACL reconstruction: a scoping review of the efficacy of interventions. *Br J Sports Med*. 2019;53(5): 289-298.
 40. Haslauer CM, Proffen BL, Johnson VM, Hill A, Murray MM. Gene expression of catabolic inflammatory cytokines peak before anabolic inflammatory cytokines after ACL injury in a preclinical model. *Journal of Inflammation*. 2014 Dec;11(1):1-10.