

# Conservative management of neck and thoracic pain in an adult with neurofibromatosis-1

John Mignelli, DC, BSc<sup>1</sup>

Lauren J. Tollefson, DC, BS, DACBR<sup>1</sup>

Eric Stefanowicz, DC, MS, DACBR<sup>1</sup>

**Objective:** *To describe the case of a 21-year-old female with previously diagnosed neurofibromatosis type 1 (NF-1) with neck, scapular, lumbar, and temporomandibular discomfort along with headaches.*

**Clinical features:** *The patient had chronic tightness and pain in the cervicothoracic region as well as pain in the lumbar spine at the site of prior neurofibroma removal. Radiographs demonstrated multilevel osseous changes. In addition to NF-1, she was diagnosed with cervical myalgia, tension-type headaches, and chronic temporomandibular joint disorder.*

**Intervention and outcomes:** *Treatment consisted of a course of manual therapy including cervical flexion-distraction, myofascial release, patient education on workplace ergonomics, and an at-home active care plan. The patient experienced a reduction in pain and headache frequency.*

**Traitement conservateur des douleurs cervicales et thoraciques de l'adulte atteint de neurofibromatose de type 1**

**Objectif :** *Présenter le cas d'une jeune femme de 21 ans atteinte de neurofibromatose de type 1 (NF1) et ressentant une gêne au cou, aux épaules, à la région lombaire, à l'articulation temporomandibulaire et souffrant de maux de tête.*

**Caractéristiques cliniques :** *La patiente se plaignait de raideurs chroniques et de douleurs à la région cervicothoracique et à la colonne lombaire au point d'ablation d'un neurofibrome. Les clichés radiographiques montraient des altérations osseuses à plusieurs étages. En plus d'être atteinte de NF1, la patiente avait des myalgies cervicales, des céphalées de tension et un trouble chronique de l'articulation temporomandibulaire.*

**Intervention et résultats :** *On a opté pour une thérapie manuelle consistant en une décompression discale en flexion-distraction, un relâchement myofascial, l'information sur l'ergonomie du poste de travail et un plan de soins actifs à domicile. Les douleurs et la fréquence des maux de tête de la patiente ont diminué.*

<sup>1</sup> Chiropractic Department, D'Youville College

Corresponding author: Lauren J. Tollefson, Chiropractic Department, D'Youville College, 320 Porter Ave; Buffalo NY, 14222

Tel: 716-829-8026

E-mail: tollefsl@dyc.edu

© JCCA 2021

The authors have no disclaimers, competing interests, or sources of support or funding to report in the preparation of this manuscript. The involved patient provided consent for case publication.

**Summary:** *Manual therapy in the form of cervical flexion-distraction with myofascial release and education on workplace ergonomics were effective in reducing neck and thoracic pain as well as reducing headache frequency in a 21-year-old with NF-1.*

(JCCA. 2021;65(1):121-126)

**KEY WORDS:** active care, cervical flexion-distraction, cervicgia, chiropractic, manual therapy, neurofibromatosis

## Introduction

Neurofibromatosis type 1 (NF-1), also known as von Recklinghausen disease, is an inherited genetic condition of neuroectodermal origin affecting roughly one in 2500 to one in 3000 births<sup>1</sup> and is characterized by abnormal growth of nerve tissue resulting in neurofibromas. It is possible to diagnose NF-1 at young ages because characteristic cutaneous manifestations typically present during childhood.<sup>2</sup> Clinicians should be aware of these signs, as they can be easily recognized by clinical observation. For clinicians who discover skin lesions in children and are suspicious of NF-1, referral to a primary care provider (PCP) or neurologist for laboratory and genetic testing is warranted.

Because patients may experience neck and back pain as well as clinical neurologic deficits as a result of spinal deformity due to the presence of neurofibromas<sup>3</sup>, patients with NF-1 may seek chiropractic treatment. Subsequent surveillance and management of neurologic complications and spinal deformity of NF-1 are typically handled by the PCP and/or the neurologist. The purpose of this case report is to review the etiology, epidemiology, and clinical manifestations of NF-1, discuss these factors within a chiropractic context, and demonstrate the outcomes of conservative management and active care of a patient with this condition.

## Patient presentation

A 21-year-old female nursing student presented to a chiropractic clinic seeking care for neck, bilateral scapular, low back, and temporomandibular joint discomfort as well as

**Résumé :** *La thérapie manuelle sous forme de décompression en flexion-distraction, le relâchement myofascial et l'information sur les postes de travail ergonomiques ont permis de réduire les douleurs cervicales et thoraciques et la fréquence des maux de tête chez une jeune femme de 21 ans atteinte de NF1.*

(JACC. 2021;65(1):121-126)

**MOTS CLÉS :** soins actifs, décompression cervicale en flexion-distraction, cervicgia, chiropratique, thérapie manuelle, neurofibromatose

weekly headaches of moderate severity. Her headaches were described as “tightness” which wrapped around her orbital, temporal, and occipital regions. She was previously diagnosed with NF-1, which was being managed by her primary care physician. The patient also described occasional mild “shooting” pain in her right hand and cubital area that she attributed to local neurofibromas in these areas.

She initially attributed her complaint of headaches to her condition, mentioning that at one point she was undergoing bi-annual head MR Imaging to monitor for any cranial changes related to NF-1. However, at the time of presentation it had been approximately two years since her last MR Imaging study.

She had undergone two previous surgical procedures related to her condition: in 2001 to remove neurofibromas from her left kidney, resulting in decreased kidney function on this side, and in 2009 to remove painful neurofibromas adjacent to the posterior aspect of her right iliac crest. Vital signs, including bilateral blood pressure, pulse, and respiration were within normal limits.

Bilateral palpable and audible clicking of the temporomandibular joint upon active opening and closing of the mouth was present without lateral deviation. Upon cutaneous inspection, the patient had multiple café-au-lait spots located on her upper back, neck, and arms, as well as multiple fibroma molluscum located on her anterior and lateral neck. Her right posterior iliac crest demonstrated scar tissue with a blue-purple coloration characteristic of a bruised, edematous focus. Predictably, this region was palpated to be tender, and the patient de-

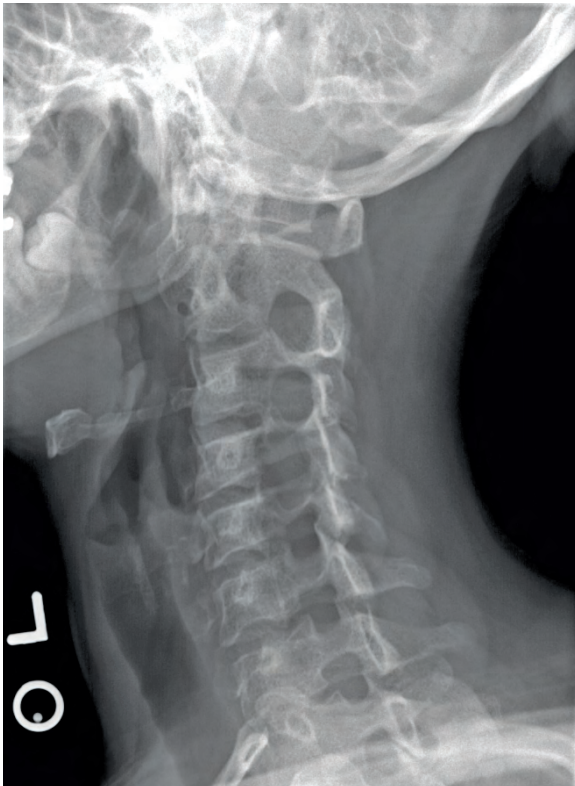


Figure 1.

*Left posterior oblique radiograph. Intervertebral foraminal widening at C2-C3 through C5-C6 on the right.*

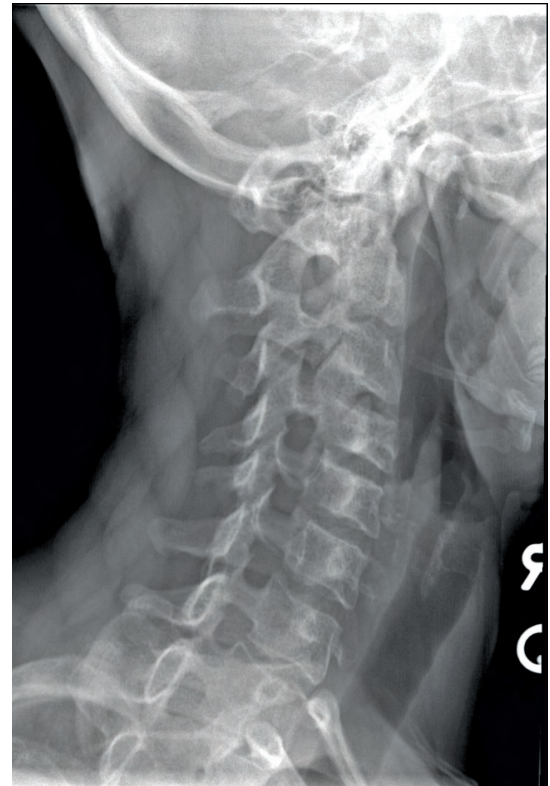

Figure 2.

*Right posterior oblique radiograph. Intervertebral foraminal widening at C2-C3 on the left.*

scribed it as a source of irritation with sitting or direct contact.

Palpation of the cervical and thoracic spine revealed joint restrictions at C2, C3, T1, T4 and T6. Tenderness and hypertonicity were palpated in muscles around the temporomandibular joint, upper cervical spine, cervicothoracic junction, and mid-thoracic spine. Additionally, palpation provoked pain in the trapezius and rhomboid muscles, which were also hypertonic bilaterally.

Cranial nerves, as well as C5-T1 and L3-S1 dermatomes, myotomes, and deep tendon reflexes each tested normal. Discomfort in the cervical spine was elicited with active cervical flexion, and in the left scapular region with resisted external rotation of the arm. Cervical spine ranges of motion were otherwise full and pain-free. Spurling A and cervical distraction tests did not reproduce her hand

or cubital pain, suggesting that this complaint did not originate from the cervical spine. Seated Kemp's test yielded no reproduction of symptoms. Neer's, Yergason's, and Empty Can test were negative and did not produce shoulder symptoms. Straight leg raising and Patrick's test were negative and did not produce any low-back symptoms.

Prior to initiating chiropractic manipulative therapy, radiographs of the thoracic and cervical spine were obtained to assess for potential osseous and postural alterations that are commonly associated with NF-1. The radiographs demonstrated intervertebral foraminal widening, most notably at C2-C3 through C5-C6 on the right (Figure 1) and to a lesser degree at C2-C3 on the left (Figure 2). Osseous remodeling and posterolateral vertebral body scalloping were present at C3-C5, more prominent on the right with complete erosion of the right C5 uncinete pro-

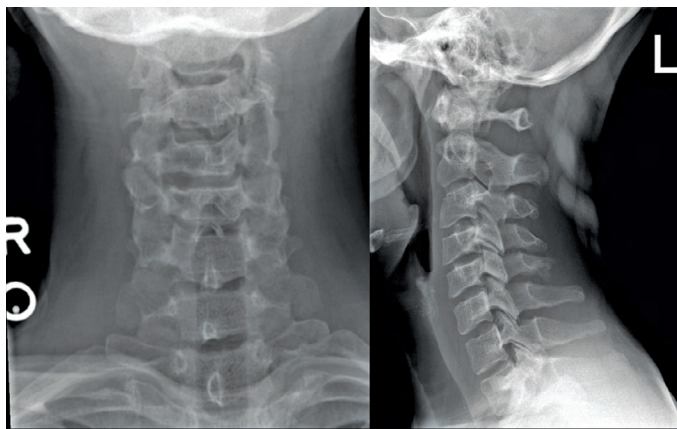


Figure 3.

*AP lower cervical and lateral cervical neutral radiographs. Osseous remodeling with posterolateral vertebral body scalloping, more prominent on the right with complete erosion of the right C5 uncinat process.*

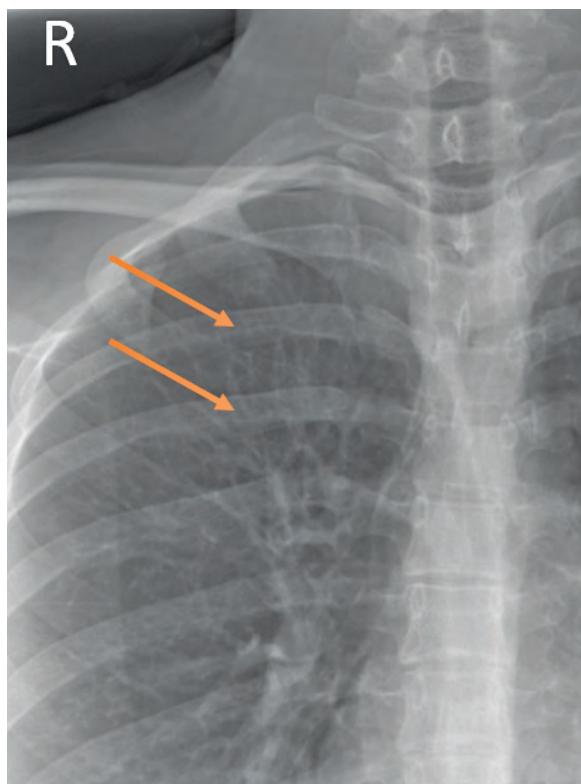


Figure 4.

*Cropped AP thoracic radiograph demonstrating mild scalloping of the inferior aspect of the right fourth and fifth ribs.*

cess (Figure 3). The thoracic spine study demonstrated mild scalloping of the inferior aspect of the right posterior fourth and fifth ribs with no soft tissue or mediastinal masses (Figure 4). No posterior vertebral body scalloping was seen in the thoracic spine or visualized upper lumbar segments. No kyphoscoliosis or other spinal deformity was present.

Upon completion of history and examination, she was diagnosed with tension-type headaches, temporomandibular joint disorder, and myalgia of the trapezius and scalene muscles. We concluded that these diagnoses were likely secondary to the patient's activities of daily living and independent of her diagnosis of neurofibromatosis-1. MR imaging of the cervical spine was recommended to fully characterize the extent and location of the neurofibromas. The patient declined the MR study, and, since there was no evidence of radiculopathy or myelopathy, the MR study was deferred.

Due to complications of NF-1, including intervertebral foraminal widening in the cervical spine, cervical spinal manipulative therapy was considered a relative contraindication, in accordance with World Health Organization guidelines. Thus, the low-force technique of cervical flexion-distraction was the primary method of treatment for addressing her cervical joint restrictions and myalgia by promoting motion via gentle traction. This was supplemented with manual soft tissue mobilization of the cervicothoracic spine musculature. Furthermore, this patient's treatment plan included patient education on workplace ergonomics and an at-home stretching and strengthening regimen. The patient reported pain relief at the conclusion of each treatment session.

The temporomandibular complaints were addressed with myofascial release technique of the masseter and temporalis muscles. Instruction on strategies to reduce jaw clenching were provided which included applying self-massage and mindfully relaxing the jaw when conscious of clenching. Treatment of the patient's low back complaint was deferred due to the prior surgical history; it was recommended that she see her primary care physician to address the scarring and continued dermal pain as well as to monitor for additional potential complications, including vascular abnormalities.

The patient underwent a treatment plan to include 8 weekly visits, of which the patient attended six visits. As of her last visit, her verbal analog scale with regards to her

neck pain reduced from a 5/10 to a 2/10. Her temporomandibular joint discomfort was resolved, and she reported a reduction of headache frequency to approximately 1 per month of mild severity. The patient continued with her nursing studies and no longer sought care as her condition improved.

## Discussion

NF-1 is an autosomal dominant phakomatosis resulting from a mutation on chromosome 17.<sup>4</sup> Clinical diagnostic criteria of NF-1 includes two or more of the following: café-au-lait spots (patches of skin appearing darker than the surrounding dermal tissue), two or more neurofibromas or one plexiform neurofibroma, cutaneous freckles in the axillary and/or inguinal areas, presence of two or more Lisch nodules (melanocytic hamartomas on the surface of the iris), presence of an optic glioma, sphenoid wing dysplasia or bowing of a long bone, and a first-degree relative with NF-1.<sup>1</sup> The cutaneous features are typically present during childhood, making NF-1 possible to diagnose at a young age.<sup>2</sup>

As many as 40% of adults with NF-1 have internal neurofibromas, which cannot be seen on physical examination and are likely to be asymptomatic.<sup>5</sup> Vascular associations of NF-1 include peripheral vascular abnormalities including aneurysms and stenosis.<sup>6</sup> Furthermore, there is potential for malignant transformation of a neurofibroma, particularly multiple large plexiform types, into a malignant peripheral nerve sheath tumor, which has a lifetime risk of 8-13% in those with NF-1 and is the leading cause of mortality in this population.<sup>7</sup> Unfortunately, there are no reliable clinical screening tests to evaluate for malignant peripheral nerve sheath tumors.<sup>8</sup>

Spinal manifestations of NF-1 are quite common and occur in 60% of patients.<sup>9</sup> Imaging findings of the spine include scoliosis, exaggerated kyphosis, vertebral body scalloping, intervertebral foraminal widening, and thinning of the pedicles, transverse processes, and ribs.<sup>10</sup> Due to the foraminal involvement, oblique radiographs of the cervical spine should be included when imaging this region. Unilateral dysplasia of the posterior wall of the orbit, creating a “bare orbit” appearance<sup>11</sup> may be visualized on frontal skull (and sometimes cervical) radiographs.

Previously, our patient had undergone biannual MR imaging of her brain, however it is suggested that routine MR imaging screening is not recommended for the de-

tection of the majority of complications in patients with NF-1.<sup>12</sup> Routine imaging does not influence the management of this condition and should not be performed.<sup>12</sup> However, in our case, treatment choice was influenced by radiographs which revealed widened cervical intervertebral foramina with adjacent osseous remodeling, warranting low force spinal manipulative techniques in this region.

There is limited research on chiropractic manipulation in patients with NF-1. A previous case study reported that the Thompson-drop technique was effective in treatment of a NF-1 patient with low-back pain without gross radiographic contraindication to manipulation.<sup>13</sup> Chiropractors should exercise caution when applying spinal manipulation in patients with NF-1 given the presence of neoplastic growth on nerve tissue and potential for vascular manifestations.<sup>6</sup> The World Health Organization suggests that spinal manipulative therapy is contraindicated in patients with “neoplastic disease of muscle or other soft tissue”.<sup>14</sup> These case studies suggest that low force techniques, such as flexion-distraction or Thompson-drop techniques<sup>15</sup> could provide symptomatic relief in NF-1 patients with musculoskeletal discomfort provided there are no gross osseous contraindications in that region. Chiropractors should be mindful of their scope of practice and limitations of manipulative therapy; thus, patients should be appropriately co-managed with a PCP or neurologist to address potential complications of NF-1.

Flexion-distraction technique has been widely utilized to relieve chronic low back pain<sup>16</sup>, however, research pertaining to the cervical region is limited. Flexion-distraction differs from high-velocity, low amplitude manipulations in that it is a slow manual traction and mobilization.<sup>16</sup>

It has also been shown that muscle stretching and strengthening regimens are beneficial in patients with NF-1.<sup>13,17</sup> Active care management with prescribed at-home stretching and strengthening was found to improve and relieve postural complaints.<sup>13</sup> A 20-session physical therapy regimen was shown to completely relieve cervical pain and headaches in a 17-year-old girl with NF-1.<sup>1</sup> This suggests that active care combined with patient education on proper muscle stretching and strengthening and continued primary care co-management is effective in patients managing NF-1.

## Summary

Musculoskeletal complaints happen in people who suffer from NF-1 as they do in other individuals, but when treating patients who have NF-1 various factors should be considered when choosing a manual therapy technique. Our case study summarized cervical spine indicators we used in considering a treatment protocol for a woman with NF-1 who presented with neck and thoracic pain.

## References

1. National Institutes of Health Consensus Development Conference. Neurofibromatosis. Conference statement. *Arch Neurol*. 1988; 45(5):575-578.
2. Dyatiara D, Damayanti D. Establishing the diagnosis neurofibromatosis type 1: a rare case. *Dermatol Rep*. 2019; 11(s1):8092: 176-178.
3. Crawford AH, Schumaier AP, Mangano FT. Management of cervical instability as a complication of neurofibromatosis type 1 in children: a historical perspective with a 40-year experience. *Spine Deform*. 2018; 6(6):719–729.
4. Williams VC, Lucas J, Babcock MA, Gutmann DH, Korf B, Maria BL. Neurofibromatosis type 1 revisited. *Pediatr*. 2009; 123(1):124-133.
5. Thakkar SD, Feigen U, Mautner VF. Spinal tumours in neurofibromatosis type 1: an MRI study of frequency, multiplicity, and variety. *Neuroradiol*. 1999; 41(9):625-629.
6. Oderich GS, Sullivan TM, Bower TC, Gloviczki P, Miller DV, Babovic-Vuksanovic D, Macedo TA, Stanson A. Vascular abnormalities in patients with neurofibromatosis syndrome type I: clinical spectrum, management, and results. *J Vasc Surg*. 2007; 46(3):475–484.
7. Evans DG, Baser ME, McGaughran J, Sharif S, Howard E, Moran A. Malignant peripheral nerve sheath tumours in neurofibromatosis 1. *J Med Genet*. 2002; 39(5):311–314.
8. Athanasiou A, Sarlis P, Balogiannis I. Aggressive malignant peripheral nerve sheath tumor of the lower limb of a patient with neurofibromatosis-1 and multiple spinal cord neurofibromas. *Hippokratia*. 2014; 18(4):376.
9. Resnick D, Kransdorf MJ. Bone and joint imaging. 3<sup>rd</sup> ed. Philadelphia, PA: Saunders.
10. Feldman DS, Jordan C, Fonseca L. Orthopaedic manifestations of neurofibromatosis type 1. *J Am Acad Orthop Surg*. 2010; 18(6):346–357.
11. Mukonoweshuro W, Griffiths PD, Blaser S. Neurofibromatosis type 1: the role of neuroradiology. *Neuropediatr*. 1999; 30(3):111-119.
12. Ferner RE, Huson SM, Thomas N, Moss C, Willshaw H, Evans DG, Upadhyaya M, Towers R, Gleeson M, Steiger C, Kirby A. Guidelines for the diagnosis and management of individuals with neurofibromatosis 1. *J Med Genet*. 2007; 44(2):81–88.
13. Gajeski BL, Ketter NM, Awwad EE, Boesch RJ. Neurofibromatosis type I: clinical and imaging features of Von Recklinghausen's disease. *J Manipulative Physiol Ther*. 2003; 26(2):116-127.
14. World Health Organization. Guidelines on basic training and safety in chiropractic. Geneva. 2005. Retrieved from <https://www.who.int/medicines/areas/traditional/Chiro-Guidelines.pdf>.
15. Zemelka WH. The Thompson technique. 1<sup>st</sup> ed. Bettendorf, IA: Victoria Press.
16. Cox JM, Guadavalli MR. Traction and distraction techniques In: Haldeman S, Dagenais S, Budgell B, Grunnet-Nilsson N, Hooper PD, Meeker WC, Triano J (eds). Principles and practice of chiropractic. 3<sup>rd</sup> ed. New York, NY: McGraw-Hill.
17. Helmers KM, Irwin KE. Physical therapy as conservative management for cervical pain and headaches in an adolescent with neurofibromatosis type 1: a case study. *J Neurol Phys Ther*. 2009; 33(4):212-223.